



Kumbrink



K Taping

An Illustrated Guide

- Basics
- Techniques
- Indications

1	The K-Taping Method
2	The Four Application Techniques
3	Muscle Applications
4	Ligament Applications
5	Corrective Applications
6	Applications for Specific Indications
7	Lymphatic Applications
	References
	Subject Index



Birgit Kumbrink

Born 1972

- 1990: Completed training as a Certified Masseur and Balneotherapist
- 1993: Completed education as a Physical Therapist
- 2000: Became Director of the K-Taping Academy

Continuing Professional Education

- Manual therapy
- Manual lymphatic drainage
- PNF (Proprioceptive Neuromuscular Facilitation)
- Trained as an APM (Acupuncture Massage) therapist

Birgit Kumbrink

KTaping

An Illustrated Guide

- Basics
- Techniques
- Indications

Birgit Kumbrink

K Taping

An Illustrated Guide

- Basics
- Techniques
- Indications

With 450 illustrations in colour

Birgit Kumbrink
K-Taping Academy
Wildbannweg 10
44229 Dortmund



Please tell us your opinion regarding this title: www.springer.de/978-3-642-12931-5

ISBN-13 978-3-642-12931-5 Springer-Verlag Berlin Heidelberg New York

Bibliographic information Deutsche Bibliothek

The Deutsche Bibliothek lists this publication in Deutsche Nationalbibliographie;
detailed bibliographic data is available in the internet at <<http://dnb.ddb.de>>.

This work is subject to copyright. All rights are reserved, whether the whole or part of the material is concerned, specifically the rights of translation, reprinting, reuse of illustrations, recitation, broadcasting, reproduction on microfilms or in any other way, and storage in data banks. Duplication of this publication or parts thereof is permitted only under the provisions of the German Copyright Law of September 9, 1965, in its current version, and permission for use must always be obtained from Springer-Verlag. Violations are liable to prosecution under the German Copyright Law.

Springer Medizin

Springer-Verlag GmbH
ein Unternehmen von Springer Science+Business
springer.de

© Springer-Verlag Berlin Heidelberg 2012

The use of general descriptive names, registered names, trademarks, etc. in this publication does not imply, even in the absence of a specific statement, that such names are exempt from the relevant protective laws and regulations and therefore free for general use.

Product liability: The publishers cannot guarantee the accuracy of any information about dosage and application contained in this book. In every individual case the user must check such information by consulting the relevant literature.

Planning: Marga Botsch, Heidelberg

Project management: Heidemarie Wolter, Heidelberg

Translated into English from the German by Norma Dickson, Großer Steinweg 16, 35390 Gießen

Anatomic drawings in chapter 3: Appell u. Staug-Voss (1996)

Anatomic drawings in chapter 4: Tillmann (2005)

Cover design: deblik Berlin

Typesetting: Fotosatz-Service Köhler GmbH – Reinhold Schöberl, Würzburg

Preface

Dear Reader,

This book is intended to serve as a reference work for trained »K-Tapers« and a useful everyday tool for practitioners. It includes a variety of indications for treatment, and is full of information and advice based on over 12 years of experience.

K-Taping can support an extraordinarily wide range of therapies and represents an effective tool for every physical therapist and doctor who knows the method. Practitioners do not need to employ medicines or other pharmaceutical agents: simply applying the correct technique in conjunction with the appropriate K-Tape produces optimal results. Over the last twelve years K-Taping – based in the German K-Taping Academy – has established itself in nearly 40 countries and has become a standard component of physiotherapy treatment. Though K-Taping has developed considerably in that time and the K-Taping Academy has conducted successful studies with partners including the research division of Charité Berlin, many aspects of the method present vital prospects for continuing research and experimentation.

K-Taping is hardly a passing trend in the field of professional medical training, but instead has rightfully achieved a solid international standing in the field on the basis of the K-Taping Academy's years of hard work and professional research. This internationally recognized status is also the product of the uniform and well-founded training program offered by the Academy worldwide and held in the respective home languages. As a result the K-Taping approach and the Academy's training have not only been recognized in Germany, Austria and Switzerland for several years, but the Academy has also been accredited by professional associations in Australia, France (SFMKS), Croatia and Canada, and by the Board of Certification (BOC) in the USA. Participants receive continuing education points for their training and in many cases it is also possible to receive state educational funding (e.g. educational »checks« and vouchers (Bildungsschecks and Bildungsgutscheine)) or support through other programs.

This book extensively details the fundamentals of K-Taping and its many-faceted applications, and is mainly geared towards trained K-Taping therapists. Those who would like to learn and use this valuable and effective therapy method in their work should first complete the Academy training and not attempt to learn it on their own, as it is only in supervised, practical training that one can learn how to correctly apply the special techniques required when working with elastic K-Tape, and learn the specific body positioning needed when treating athletes or other patients. Only then can elastic tape be transformed into a unique and effective instrument to support the work of doctors and physical therapists alike.

Birgit Kumbrink

K-Taping Academy

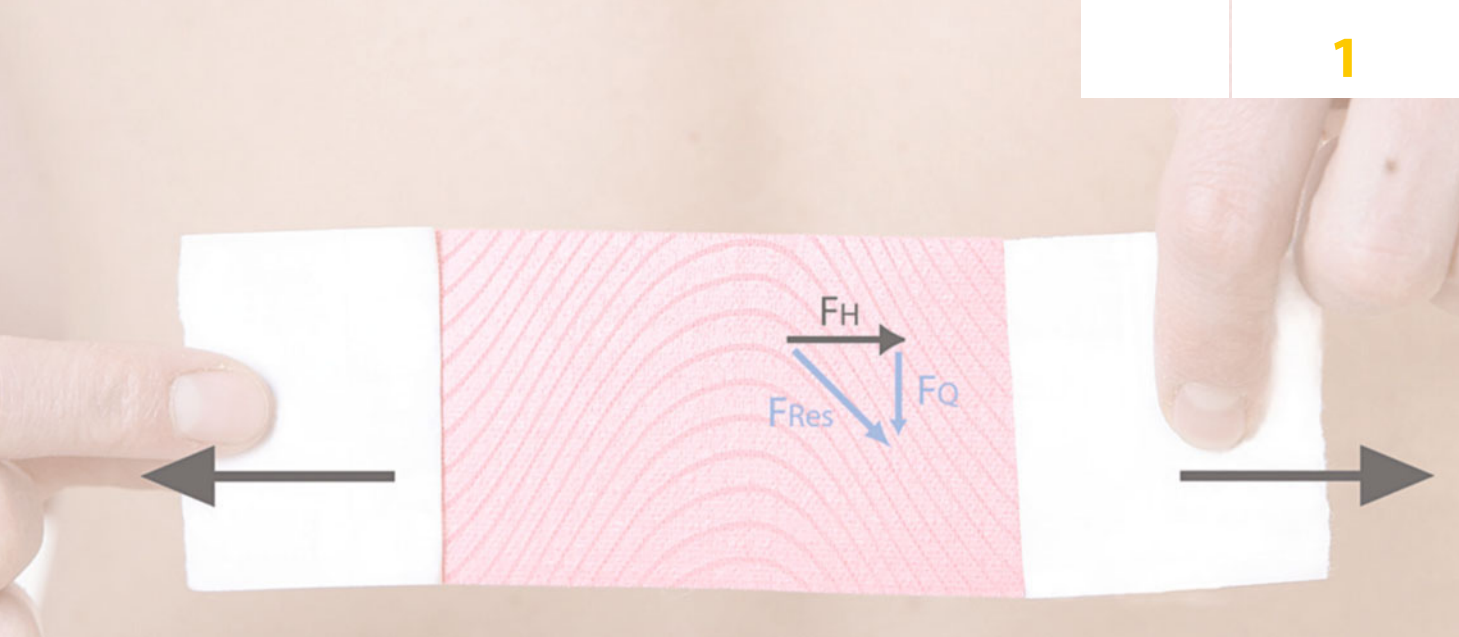
Dortmund

July 2011

Contents

1	The K-Taping Method	1		
1.1	From Theory to Therapeutic Methodology	2	3.2.7	Intrinsic back musculature (erector spinae), application for the lumbar region
1.2	The elastic stretch K-Tape	3	3.3	Muscle application for the lower extremities
1.2.1	Indications of inadequate tape quality	4	3.3.1	Adductor longus
1.2.2	Tape with pharmaceutically active ingredients	5	3.3.2	Rectus femoris
1.3	User and areas of application	6	3.3.3	Biceps femoris
1.4	Training for K-Taping Therapists	6	3.3.4	Semimembranosus
1.5	CROSS-TAPE®	6	3.3.5	Gluteus maximus
1.6	Basic functions and effects of K-Taping	6	3.3.6	Tibialis anterior
1.6.1	Improvement of muscle function	7	3.3.7	Extensor hallucis longus
1.6.2	Elimination of circulatory impairments	7		
1.6.3	Pain reduction	7	4	Ligament Applications
1.6.4	Support of joint function	9	4.1	Ligaments and tendons
1.7	Application and removal of the tape	9	4.1.1	Collateral ligaments of the knee
1.8	Contraindications	11	4.1.2	Patellar ligament
1.9	Color theory	11	4.1.3	Achilles tendon
1.10	Diagnosis	11	4.1.4	Lateral collateral ligaments of the ankle joint
			4.2	Special form of ligament application: spacetape
2	The Four Application Techniques	13	4.2.1	Spacetape pain point
2.1	Muscle applications	14	4.2.2	Spacetape Trigger point
2.1.1	Muscle function	14		
2.1.2	Mode of action of the K-Taping	14	5	Corrective Applications
2.1.3	Executing the application	14	5.1	Functional correction
2.2	Ligament applications	16	5.1.1	Patella correction
2.2.1	Ligament applications (Ligamenta)	17	5.1.2	Scoliosis
2.2.2	Ligament applications for tendons	21	5.1.3	Spinous process correction
2.2.3	Space tape	23	5.2	Fascia correction
2.3	Corrective applications	25	5.2.1	Fascia correction of iliotibial tract
2.3.1	Functional correction	25	5.2.2	Inflammation of the superficial pes anserinus
2.3.2	Fascia correction	27	5.2.3	Frontal headache
2.4	Lymphatic applications	28	5.2.4	Anterior shoulder instability
2.4.1	Causes of lymphostasis	28	5.2.5	Hallux valgus
2.4.2	Mode of action of lymphatic applications	31		
			6	Applications for Specific Indications
3	Muscle Applications	35	6.1	Head
3.1	Muscle applications for the upper extremities	37	6.1.1	Tinnitus
3.1.1	Trapezius	37	6.1.2	Migraine
3.1.2	Deltoid	39	6.1.3	Whiplash
3.1.3	Biceps brachii	41	6.1.4	Temporomandibular joint
3.1.4	Triceps brachii	43	6.2	Trunk
3.1.5	Infraspinatus	45	6.2.1	Thoracic outlet syndrome (TOS)
3.1.6	Extensor carpi radialis longus muscle	47	6.2.2	Asthma
3.2	Muscle applications for the trunk	49	6.2.3	Scoliosis
3.2.1	Pectoralis minor	49	6.2.4	Lumbar vertebral syndrome (LVS)
3.2.2	Pectoralis major	51	6.2.5	Micturition disorders
3.2.3	Rectus abdominis	53	6.2.6	Menstrual disorders
3.2.4	External oblique	55	6.2.7	Uterine prolapse
3.2.5	Internal oblique	57	6.2.8	Scar tape
3.2.6	Iliacus	59		

6.3	Upper extremities	135	7.2	Lower extremities	175
6.3.1	Impingement syndrome	135	7.2.1	Drainage of the thigh	175
6.3.2	Biceps tendonitis	137	7.2.2	Drainage of the lower leg/entire leg	177
6.3.3	Epicondylitis	139	7.2.3	Drainage of the entire leg	179
6.3.4	Carpal tunnel syndrome	141	7.2.4	Drainage of the foot	181
6.3.5	Wrist stabilization	143	7.2.5	Stemmer sign in the foot	183
6.3.6	Finger contusion	145	7.2.6	Drainage using the leg spiral tape	185
6.4	Lower extremities	147	7.3	Trunk	187
6.4.1	Hip problems	147	7.3.1	Drainage of upper trunk quadrant	187
6.4.2	Torn muscle fibers	149	7.3.2	Drainage of lower trunk quadrant I	189
6.4.3	Osteoarthritis of the knee joint	151	7.3.3	Drainage of lower trunk quadrant II	191
6.4.4	Achillodynia	153	7.3.4	Drainage of abdomen	193
6.4.5	Ankle joint distortion	155	7.4	Additional lymphatic applications	195
6.4.6	Splayfoot, fallen arch, and flatfoot	157	7.4.1	Drainage of the face	195
7	Lymphatic Applications	159	7.4.2	Drainage of the shoulder joint	197
7.1	Upper extremities	161	7.4.3	Drainage of the knee joint	199
7.1.1	Drainage of medial upper arm	161	7.4.4	Fibrosis/hematoma	201
7.1.2	Drainage of lateral upper arm	163	References		203
7.1.3	Drainage of forearm/entire arm	165	Subject Index		205
7.1.4	Drainage of upper arm – medial and lateral	167			
7.1.5	Drainage of hand	169			
7.1.6	Protein fibrosis (Stemmer sign) in the hand	171			
7.1.7	Drainage using the arm spiral tape	173			



1 The K-Taping Method

1.1 From Theory to Therapeutic Methodology – 2

1.2 The elastic stretch K-tape – 3

1.2.1 Indications of inadequate tape quality – 4

1.2.2 Tape with pharmaceutically active ingredients – 5

1.3 User and areas of application – 6

1.4 Training for K-Taping Therapists – 6

1.5 CROSS-TAPE® – 6

1.6 Basic functions and effects of K-Taping – 6

1.6.1 Improvement of muscle function – 7

1.6.2 Elimination of circulatory impairments – 7

1.6.3 Pain reduction – 7

1.6.4 Support of joint function – 9

1.7 Application and removal of the tape – 9

1.8 Contraindications – 11

1.9 Color theory – 11

1.10 Diagnosis – 11

The term »taping« invariably raises the question of what is different about **K-Taping** compared to the well-known **classic taping** with non-elastic material. Apart from a few **application techniques**, there is no comparison. Generally speaking, classic tape is used to stabilize or immobilize joints. The application techniques using **elastic stretch K-Taping** cannot be carried out with **classic tape**. K-Tapes follow the path of a muscle or nerve, can be freely applied to any part of the body, and do not limit the patient's **freedom of movement**. Lymphatic applications, which improve the lymph and blood circulation, are also included in the K-tape application options. Whereas classic taping is predominantly used for immobilizing or stabilizing joints, K-Taping is a wide-ranging **treatment method** with the potential for further development. A comparison can therefore only be made when the same indications are to be treated, e.g. joint problems, injuries to, or pain in the joints, and postoperative therapy. Compared with classic taping, where a joint problem, for example, would be immobilized, the joint would remain mobile with elastic stretch K-Tape. Beyond this comparison, K-Taping offers a multitude of **treatment options**. There are also **useful combinations** of both taping techniques (e.g. in sport). Whether in general or competitive sport, application of the colorful K-Taping treatment strips, in addition to classic taping, is already standard procedure.

Every process in **mechanics, dynamics, physics**, and, of course, also in **medicine** depends upon the interaction of all the components. Thus the smallest defective cog can disrupt a **complex functional chain reaction**. This is also true for the human body. Only when muscle force, moment arm, and ligaments round a joint are working in balance is the individual free of discomfort. A great deal of pain results from **functional disorders** and the consequent disrupted interaction or **imbalance**. Such functional disorders are triggered by a difference in **muscle flexibility** and/or **muscle development** on the opposite side of the joint (agonist and antagonist). With injuries, not only is the balance disrupted but the performance of protective **contraction reflexes** is reduced. Edema and swelling disrupt the process of physiological movement and lead to pain.

A K-Taping application simultaneously facilitates the **reduction of edema**, improves **lymph and blood circulation**, and contributes, through **proprioception**, to the normalization of muscle function and the support of ligaments and tendons. The result is generally a rapid reduction of pain and an improvement in the joint and muscle function.

If the space between skin and muscle is compromised, e.g. through muscle inflammation, there is reduced drainage of lymph – the lymphatic system is disrupted. This compression and the resultant restricted drainage of lymph stimulate the **pain receptors** in the skin leading to **localized pain**. If the skin in the affected area is stretched prior to the

application of K-Tape, the skin, together with the tape, forms wave-like convolutions on returning to the resting state. Through this lifting of the skin, the space between skin and subcutaneous tissue increases. The lymph can drain from this space into the lymphatic system more easily, thereby reducing the pressure on the pain receptors and reinforcing the **body's self-healing effects**. At the same time, the tissue is constantly lifted and lowered through bodily movement. Lymphatic drainage and blood circulation are stimulated in a similar way to a **pump action**. In addition, movement ensures continual displacement of the skin. These skin movements influence the **mechanoreceptors**, which in turn leads to **pain attenuation**.

K-Tape can likewise influence the internal organs. With simple applications, a reduction in pain in **dysmenorrhoea**, for example, or improvement of bladder function in micturition dysfunction can be achieved on a segmental level via the cutivisceral reflex arc.

1.1 From Theory to Therapeutic Methodology

The concept of influencing **proprioception**, muscles, ligaments, and thus physiological activity via the **cutaneous receptors** is far older than the idea of K-Taping. Experimentation with therapy concepts to induce proprioceptive stimulation using manual treatment or non-elastic tape applications has been, and continues to be carried out. Non-elastic tape has the disadvantage that it can only be applied to small areas. Muscle movement, and thus skin displacements, work against the non-elastic tape. This results in less comfort, restricted movement, and a short application period.

The many positive properties of **K-Taping treatment** known today were not, however, the primary focus of its development. Initially, attempts were made to influence proprioception and consequently muscle function using elastic tape that did not restrict the patient's movement. Hence the name K-Taping therapy, which derives from the Greek word *kinesis* = movement.

For a long time, predominantly **muscle applications** were tested and executed. The additional features and scope of treatment were developed only through years of use, the associated therapeutic results, and through the development of the K-Taping currently employed. Up to the year 2000, the **K-Taping Academy** conducted patient questionnaires after the initial application of the tape, evaluated the results, and employed the conclusions to provide new application options. As well as in Germany, the Academy now conducts international **studies** in collaboration with clinics and professional associations of therapists to discover new areas of application.

1.2 · The elastic stretch K-Taping

The first formulation of the treatment concept has led to a completely new and effective therapeutic method across the entire range of K-Taping applications, which can be used for an exceptionally broad **indications spectrum** and effectively support many well-known therapeutic concepts. A major advantage of K-Taping treatment is that the therapist can give the patient supportive therapy to take home. Most therapeutic methods stop with the end of the treatment session; in contrast, K-Taping continues to work for as long as the tape remains on the patient.

The experience collected at the K-Taping Academy led to the development of »K-Tape for me« at bivix. K-Tape for me is a collection of easy-to-use K-Tapings that anyone can apply using the accompanying instructions. These are the most commonly used tapings and, with a bit of guidance, can also easily be used preventively (■ Fig. 1.1).

1.2 The elastic stretch K-Tape

High-quality tape is essential for the successful application of K-Taping therapy. The tape must have very specific properties and maintain **consistent quality** over a period of several days and under stress. Critical to this requirement is the **quality of the materials** on the one hand, and the controlled, consistent processing on the other hand. The **cotton fabric** must be woven with the warp and weft at right angles to each other and the incorporated elastic warp thread must retain its **elasticity** during the entire application period and not be subject to fatigue.

The elasticity of the K-Tape is comparable to the extension capacity of the human muscle. The cotton fabric can only be stretched **longitudinally** by approximately 30-40%.

This corresponds to muscle extension of 130-140%, with the tape having already been stretched by 10% upon application to the backing paper. These stretching properties play an important role in the various application techniques.

Original K-Tape is available in **4 colors**: cyan, magenta, beige, and black (■ Fig. 1.2). The different colored tapes have exactly the same properties, however. They do not vary in stretching capacity, thickness, or any other function. The background to the 4 different colors can be found in ► Chap. 1.9, Color theory.

Important

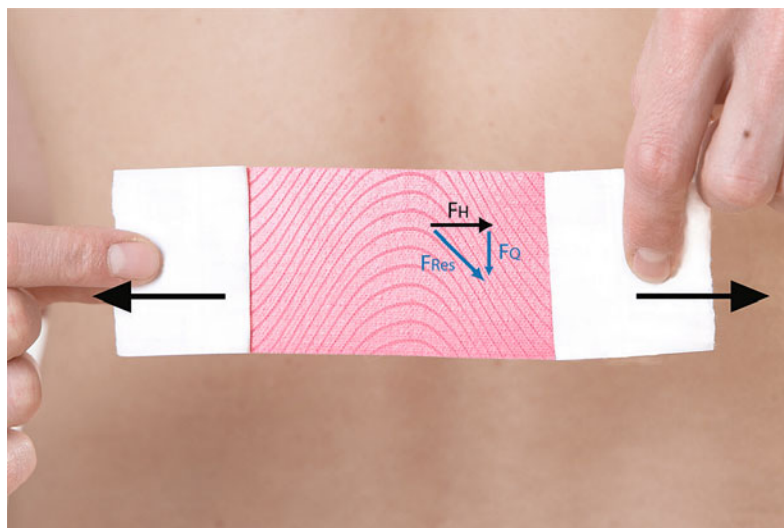
The water-resistant and breathing properties of the K-Tape allow long **wearability** and a high level of **comfort**.

While **retaining mobility**, the patient is not restricted or handicapped during sporting activities, showering, swimming, saunas, at work, or in any other daily activities. To this end, there are specific requirements regarding the **quality** of the tape. An increasing number of tapes for K-Taping are coming onto the market, for the most part poor quality products from China and other Asian countries. Currently, over 60 different tape names and varieties are available. There are, however, considerably fewer manufacturers than tape names. This means that many different product names are supplied by only a few manufacturers. These non-brand name products are sold in different packaging. The tape supplier has no influence over the quality of these products. The **tape properties** of cheaper products vary continuously when the raw materials for the manufacture come from different suppliers. The variation of a single compo-



■ Fig. 1.1. Original K-Tape in 4 colors and K-Tape for me, precut strips you can use on your own

■ Fig. 1.2. Original K-Tape in 5cm width



ment is enough to effect this change: if the cotton, the acrylic adhesive, or the backing paper is changed, this automatically alters the properties of the tape.

Tapes that have no product name on the backing paper or the packaging, or are printed with a label different from the brand name frequently originate from mass production, where the manufacturer always purchases the basic materials from the cheapest suppliers, and thus the tape properties are subject to variability. In Asia, a common name and general term for elastic tape is »**Kinesiology Tape**.« This is an umbrella term for a multitude of varying qualities. In many cases, this name is found on the tape roll, while the product is offered with another name on the packaging.

The range of products is becoming increasingly unmanageable, and still more tape brands are appearing on the market.

Important

Every therapist should examine the materials on offer very closely and critically, since their quality is crucial to the success of the therapy and the wearing comfort for the patient.

Many seemingly more economical offers turn out to be expensive alternatives when the tape application has to be renewed after a short time, the elastic stretch properties and workmanship do not meet requirements, or the acrylic adhesive causes **skin irritations**. Since several applications can be made with one roll of K-Tape, the possible saving per patient is questionable. No therapist should risk the quality of the therapy and treatment success for patient for reasons of economy.

As an **International Trainer**, the Academy depends upon the use of high-grade tape with consistent quality.

Quality control has been introduced into the production of this tape. In addition, samples from each batch are tested in a German laboratory for residual monomers and general residues in the adhesive, as well as for their mechanical properties. In particular, residual monomers, which remain from the production of the acrylic adhesive, must be removed as far as possible by a specific and time-consuming finishing process, since they can lead to skin irritations and intolerance.

The mechanical properties are tested to show whether the tape has the required elasticity and retains it throughout the period of application.

1.2.1 Indications of inadequate tape quality

Ultimately, the quality of the tape only becomes apparent through use. Of course, the quality of each tape should not be tested on the patient. Some of the criteria and **quality deficiencies** can be simply checked beforehand.

Characteristics of the cotton fabric

The **cotton fibers** must be woven at right angles to each other. The longitudinal thread must run parallel to the outer edges of the tape. Some tapes show a visible distortion of the fibers. Instead of running parallel in a longitudinal direction, they run diagonally. The outermost threads of the fabric become severed at short intervals. These discontinuous outermost threads cannot hold the tension, and fraying of the fabric leads to shortened wearability.

Deficient elastic properties

The elastic fiber woven into the fabric **longitudinally** must display very specific stretch and endurance limits. Devia-

tion of stretch parameters and premature fatigue present problems in usage.

If the tape has significantly lower **stretchability**, this results in different modes of action, reduction in wearability, and poorer comfort.

The more the elasticity is reduced, the closer the tape comes to the limiting state of »non-elastic tape.« Using non-elastic tape for a K-Taping application means the patient loses mobility, the muscle works against the tape with each movement, and after a short time the tape comes loose or else causes painful pulling of the skin. Tapes with less stretch display these »limiting properties« in a correspondingly reduced form.

If the tape has significantly higher stretchability, the K-Taping application is ineffective, or produces a different result. The softer an elastic thread is, the lower the restoring forces are that can work on the fabric. With an infinitely stretchable tape, there are no restoring forces at all and therefore no effect.

Variable elastic properties

As with other high quality goods, the manufacture of a tape requires constant quality control during production. Even slight alterations in the manufacturing process, variations in the quality of the raw materials, uneven cutting of the individual rolls, and storage conditions of the finished product can lead to inconsistencies in the properties of tape from one manufacturer. Variable properties make the work of every K-Taping therapist harder and have a negative influence on the treatment and the wearing comfort and satisfaction of the patient

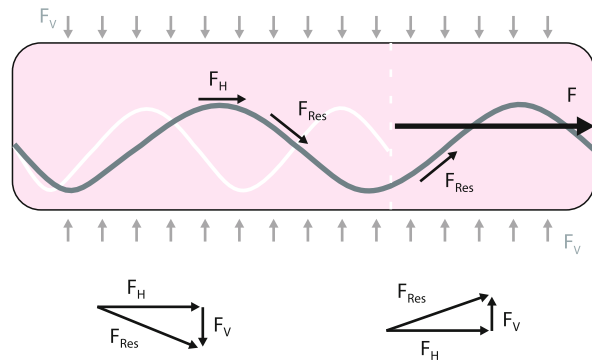
Important

It is advisable to buy only the best quality (e. g. K-Tape®) and to remain with a good product and not constantly change it!

The acrylic coating

The tape strip is woven in such a way that there is only longitudinal elasticity. The tape cannot be stretched in a transverse direction. The desired effect of transverse stretching, i.e. a restoring force in the transverse direction, is achieved by the **acrylic coating**, which is applied longitudinally to the tape in the form of a sine wave (■ Fig. 1.3). The longitudinal forces follow the acrylic curves and thus effect a resolution of force (FRes) into a **longitudinal**, or horizontal (FH) and a **transverse**, or vertical (FV) **component**.

Thus, depending upon the extent to which the tape is stretched, there is an associated transverse force which works evenly over the entire length of the tape.



■ Fig. 1.3. Force effect and force resolution

Important

The restoring force from the longitudinal stretching in combination with the transverse force facilitates lifting of the skin or tissue. This is one of the principal effects of K-Taping therapy.

1.2.2 Tape with pharmaceutically active ingredients

Important

K-Taping therapy does not require pharmaceutically active ingredients!

Precisely this medicament-free therapy is a fundamental advantage of K-Taping.

In K-Taping therapy, the use of tape products with added pharmaceutical, secondary, or unknown mineral ingredients is inadvisable. Particularly for athletes, there is always the risk of a substance being included that is forbidden according to **anti-doping guidelines**. In pregnant women there is the question of whether such long-term administration can have an effect on the developing child. The varying periods of wear of the respective applications would also yield different contact times and side-effects. The size of the K-Taping application, and thus the area of adhesion, would also be critical for the amount of a pharmaceutically active ingredient that is absorbed. **Controlled administration** is therefore not possible.

If one considers, in addition, the very **broad application spectrum** of K-Taping therapy, from the treatment concept for professional athletes, through lymphatic therapy – including aftercare for cancer patients – to menstrual and urinary problems, and even support during pregnancy, then the use of tape with the addition of pharmaceutically active ingredients is inadvisable for the entire indications spectrum.

1.3 User and areas of application

For several years now, K-Taping has been finding its way into **competitive sport** and many areas of medicine and physiotherapy. In world championships, Olympic Games, and diverse competitive sports, be it soccer, handball, volleyball, basketball, rugby, American football, skiing, biathlon or gymnastics, this effective treatment method has become an integral component of **prevention, rehabilitation**, and part of the **training therapy**. Likewise, **after-care** and **treatment concepts** in orthopedics, surgery, as well as oncology, geriatrics, and pediatrics have been developed and introduced into hospitals and rehabilitation centers.


The **range of application** of K-Tape is currently very broadly defined and will expand still further in the coming years. It offers not only physiotherapists and sports physiotherapists but also a multiplicity of medical specialists (e.g. alternative practitioners, occupational therapists) a new **therapeutic tool**. Its use in neurology, with specific applications techniques, can be considered individually, as can gynecology and lymphatic therapy. In all cases, the prerequisite is the established training as a K-Taping therapist, as offered by the K-Taping International Academy.

1.4 Training for K-Taping Therapists

Apart from the advancement of K-Taping therapy, the establishment of a high-quality **international training system** with uniform standards is one of the most important tasks of the K-Taping Academy. This system has been under development in Germany since 1998 and is now available in more than 30 countries world wide. The training offered by the K-Taping Academy has since been recognized by professional associations in several countries, allowing participants to receiving continuing education points or other credit from their local association. The standardized courses are given in the language of the country in which they take place. Particularly interesting here is the inclusion of **treatment concepts typical of the country** concerned. This provides opportunities for a multitude of new treatment applications and the sharing of experience. For this purpose, graduates also have access to the **International K-Taping Forum**. Through its many partnerships with approved training providers, the Academy has the opportunity of incorporating the various experiences in different countries into its training and therapy.

The following **K-Taping courses** are currently being offered:

- K-Taping Basic Course – Training as K-Taping therapists.



■ Fig. 1.4. CROSS TAPE®

- K-Taping Special Courses applicable to lymphatic therapy, sports medicine and training therapy, gynecology and pregnancy support, occupational therapy, podiatry, neurology, and osteopathy (Information at: www.k-taping.com).

1.5 CROSS TAPE®

In the following treatment examples, mention is made of **Cross-Tapes**. Cross-Tapes are small, lattice-like, polyester tapes, also provided with an adhesive acrylic coating (■ Fig. 1.4). Like the K-Tapes, Cross-Tapes are free of medication and pharmaceutically active ingredients and are applied very successfully to **pain, trigger, and acupuncture** points. In many cases, Cross-Tapes can be successfully combined with K-Taping applications. For this reason, Cross-Tapes has become a firm component of the K-Taping training.

1.6 Basic functions and effects of K-Taping

Summary 1.1: The basic functions and effects

1. Improvement of muscle function
2. Elimination of circulatory impairments
3. Pain reduction
4. Support of joint functions

1.6.1 Improvement of muscle function

Application in muscle injuries

Muscle injuries range from overworked muscles through strain to torn muscle fibers and torn muscles.

Overloading the muscle apparatus causes ruptures in the **muscle connective tissue**. The resultant fluid in the interstitial spaces causes increased pressure, with concomitant stimulation of pressure and pain sensors. The consequences are: pain, stiffness, swelling, and increased tonus.

Application in hypertonus/myogelosis

A reflexively increased, **persistent tonus** leads to a **change in the consistency** of the muscle. Generally, the entire muscle is affected, but changes may be confined to localized areas within the muscle. The cause is trauma due to one-sided overload, e.g. repetitive work on a production line, which causes continuously elevated muscle tonus.

Application in muscle shortening

Muscle shortening may be reflexive or functional. This transition is generally blurred. The reasons for **reflexive muscle shortening** are, e.g.,

- protective reaction to pain,
- acoustic or optic stress factors,
- alterations in balance due to degenerative joint changes,
- coordination problems due to unaccustomed work (leading to faulty movements with an imbalance in the muscles involved),
- overloading the musculature through one-sided work.

The same conditions that cause reflexive muscle shortening may, in the long run, also lead to reversible structural shortening.

Application in hypotonus/flaccidity

Hypotonus is generally caused by reflexive inhibition due to a hypertonic antagonist, pathological joint processes, or paresis. The consequences are disrupted muscle activity resulting in reduced strength and muscle atrophy.

Application in malfunctioning muscle activation

Malfunctioning muscle activation fairly rapidly leads to **hypotrophy** and **atrophy**.

The cause is always **inactivity**, e.g. trauma with subsequent immobility, chronic diseases of the musculoskeletal system, lack of exercise, reflexive inhibition due to chronic joint processes. Complete atrophy only occurs with interruption of the nerve signal.

Effect of muscle taping

Change in tonus

Tonus is a **state of tension** maintained by impulses from the CNS as well as through peripheral afferent signals (joint, muscle, skin) as **peripheral feedback regulation**. Skin receptors are activated by the tape, thereby strengthening additional peripheral afferent signals. Influence can be exerted on tonus regulation via these mechanisms.

Support of muscle control

Proprioception (deep sensibility) serves to orient the body in space. Through the **mechanoreceptors**, we sense the position and movement of our joints. The proprioceptive afferents of the mechanoreceptors are involved in the **control of the postural motor system** (static) and **directed motility** (dynamic). The sensors are in the joints, muscles, tendons, and in the skin. The proprioceptors in the skin are reached by means of the tape. In this way, more information on position and exertion of the extremities and the body is transmitted.

1.6.2 Elimination of circulatory impairments

Inflammation is frequently the body's reaction to **tissue damage**. Along with fluid in the injured area, inflammation leads to compressed swelling and an increase in pressure between skin and musculature. The lymph flow is disrupted or stagnates. The K-Taping application can lift the skin in this area, increase the space, and thus effect a decrease in pressure and an improvement in the lymph circulation.

1.6.3 Pain reduction

Nociceptors form the basis of the **sense of pain**. Nociceptors are free nerve endings found in the **dermis**, partially penetrating the **epidermis**. They are distributed fairly evenly over the body and are of crucial importance for the skin's function as a protective layer for the organism.

Nociceptors are likewise found in the musculature, the internal organs, and in all types of body tissues. Exceptions are the outer layers of the articular cartilage in the joints, the nucleus pulposus of the spinal discs, and the brain and liver. Nociceptors react to **thermal**, **mechanical**, and **chemical** stimuli. The transmission of the **nociceptive signals** occurs on the one hand via the **myelinated A γ -fibers**, which, because of their rapid stimulus transmission, trigger the so-called **first pain** sensation (bright, sharp, piercing, or incisional pain) and on the other hand via the **unmyelinated C-fibers**, which can only slowly transmit the stimulus and trigger the »second pain« (dull, burning, boring, or tearing pain). The »**first pain receptors**« are distributed in

the skin, the »second pain receptors« in the joint capsules ligaments, tendons, and inner organs.

The **nociceptive afferents** are switched in the dorsal horn to a second neuron and relayed divergently by numerous **synaptic connections**. The first filtering and influence of the incoming **nociceptive** and **proprioceptive signals** occurs at the spinal level prior to transmission to the cranial level; in principal, however, the »important« information, e.g. nociceptive afferents for the superordinate centers (cortex, brain stem) is relayed.

The nociceptive afferents running to the dorsal horn come from joints, muscles, skin, and inner organs. Likewise, afferents run from the cortex and brain stem to the dorsal horn. These centrally descending pathways can be inhibitory as well as channelling.

The nociceptive afferents pass to the **ventral horn** and the **lateral horn**. The **motor nocireaction** takes place in the ventral horn:

- reflexive increase in muscle tonus,
- hypertonus, and
- myogelosis.

Autonomic nociception takes place in the lateral horn:

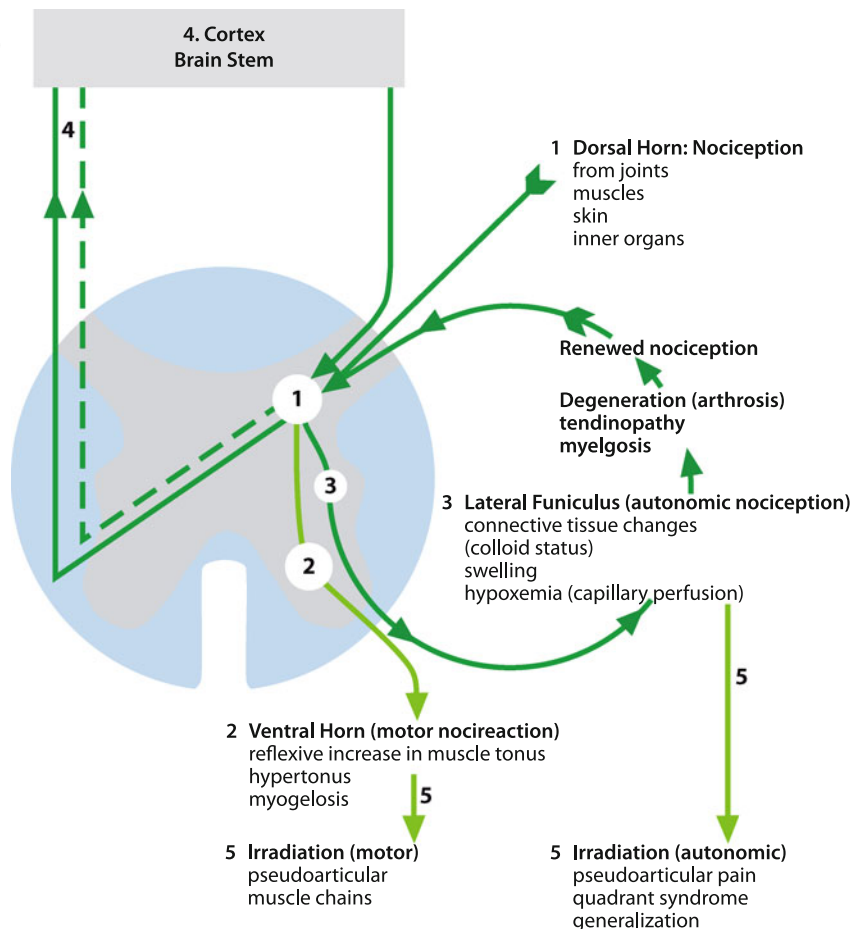
- connective tissue changes,
- swelling, and
- hypoxemia (capillary perfusion).

Degeneration (arthrosis), tendinopathy, and myelgosis give rise to repeated nociceptive afferent signals to the dorsal horn. Motorically as well as autonomically, this leads to irradiation (radiation). Motorically, it causes **pseudoradicular radiation** and radiation in the muscle chain. Autonomically, it leads to **pseudoradicular pain, quadrant syndrome, and generalization** (■ Fig. 1.5; Frisch 1999).

Thus the first nocireaction in supraliminal nociceptive afferents occurs at the spinal level.

The adhesion of the K-Tape to the skin, and the resulting mechanical displacement caused by body movement, leads to stimulation of the mechanoreceptors in the skin. Like the nociceptive afferents, these proprioceptive afferents also run to the dorsal horn and inhibit the relaying of nociception.

■ **Fig. 1.5.** Transmission of nociception and pathway of nocireaction (Frisch 1999)



1.6.4 Support of joint function

Joints are moveable connections between bones. The **capsular ligament apparatus** and the **musculature** are also involved in the control of joint movement. The mobility of a joint depends upon the type of joint and the surrounding structures (muscles, ligaments, and capsule).

Movement disorders in the joint can have different causes:

- damage to the joint surfaces due to arthrosis or arthritis with shrinkage in the capsular ligament apparatus due to faulty posture and repetitive strain
- imbalance in the musculature around the joint
- blockages due to compression, e.g. of meniscuses in the joint
- nocireactions from other structures outside the joint

The **joint functions** can be supported using different K-Tape applications.

By influencing the muscle tone, imbalances can be corrected and balance restored to the muscle group.

Important

A better sense of movement can be attained by stimulating proprioception.

Corrective functional and **fascial applications**, like passive support, result in improvement of joint function, lead to pain attenuation and consequently to a shorter healing process.

1.7 Application and removal of the tape

During its **manufacture**, the K-Tape is applied with a **slight stretch** of 10% to the backing paper. This stretch should be retained during the application of the tape strips.

Important

Despite this pre-stretching, the application is referred to as unstretched.

Depending on the **type of application**, the tape is affixed unstretched or with different degrees of pre-stretching. Before the tape is affixed and the **backing paper** removed, the tape strips are cut accordingly. The strips may be cut as **I-**, **Y-**, or **X-tapes**, or, in lymphatic therapy, **fan-shaped** and in **narrow single strips**.

Special K-Tape scissors (bivix DSN210 and bivix Nursing Scissors; ■ Fig. 1.6) are helpful and to be recommended. They have a special coating on the cutting edges



■ Fig. 1.6. K-Tape Scissors

to prevent the acrylic adhesive from penetrating the pores of the metal (as happens with conventional scissors), thus precluding sticking and blunting of the cutting edges.

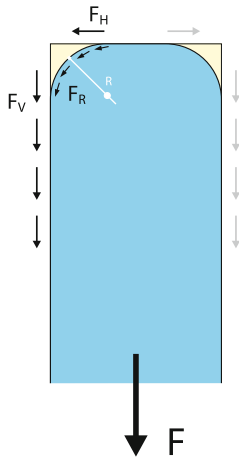
With few exceptions, K-Taping applications begin with the affixing of a **tension-free base**, which is generally the width of two fingers. From this base, the various tape strips with the required pre-stretch are affixed, apart from the two finger width ends of the tape strips, which are applied without stretch.

Each of the corners of the tape strips should be rounded with scissors. In this way and by the application of the unstretched base and ends, **premature loosening** and undesirable rolling of the tape ends can be avoided. The **rounding** of the corners plays a significant role here, since loosening of sharp corners cannot be prevented. Through the tape tension and skin movements, a certain degree of tension cannot be completely avoided in the tape ends. The **longitudinal tensile forces** are thus conducted »round the corner.« This is referred to as a **redistribution of force**.

Important

Given the opportunity, forces flow optimally along the radius.

This opportunity is provided by the tape. This means that the tensile force flows in an arc to the boundary of the tape edge (■ Fig. 1.7). The sharp corners (depicted in yellow) are thus free of tension. The **limit state** between **force flow** and **tension-free tape** leads to the corners lifting slightly. If they come into contact with clothing or a towel, the tape becomes detached more easily.



■ Fig. 1.7. Rounded edges

The K-Taping application can thus be worn for considerably longer. Likewise, it should be noted that after showering or bathing, the taped should not be rubbed with a towel but only patted dry. Rubbing frequently causes rolling of the tape ends because the adhesive sticks to the towel.

For the best durability and adhesion Pre-K Gel, which was specially developed for K-Taping therapy, is applied to the skin prior to taping (■ Fig. 1.8). Pre-K Gel ensures reliable adhesion despite oily or lightly sweaty skin. It also contains a mild disinfectant.

Extreme heat, such as infrared treatment, Fango (medicinal clay), or the influence of direct, high, external heat can lead to **skin irritations**. In contrast, a sauna presents no problems, since the body adjusts the skin temperature accordingly.



■ Fig. 1.8. Pre-K Gel

Important

The skin must be dry and oil-free, optimally Pre-K Gel should also be applied. Likewise, any thick covering of hair should be removed beforehand.

A light covering of hair is not an obstacle to the application and removal of the tape (sensory stimuli). If a **wet razor** has been used to remove the hair, there may already be small **skin injuries** or **irritations**, which, in combination with the K-Taping application, can cause itching under the tape. **Clippers**, **beauty razors**, or **trimmers** are better because they cut the hair short enough and do not injure the skin.

Important

To **activate the heat-dependent adhesive properties** of the K-Taping, the therapist should rub the flat of his/her hand several times over the completed tape application. The respective body areas are still in the pre-stretched position.

In areas that quickly become damp (hands, feet), a **separate anchor** can be affixed over the ends of the tape strips. T-taping applications should be carried out 1 to 2 hours prior to **sporting activities** because **perspiration** reduces the durability of the application.

Removal of K-Taping applications is relatively painless if the tape is wet – e.g. in the shower. The skin is tightened and the tape removed in the **direction of hair growth**.

Even a short time after affixing the tape, the skin metabolism under the tape is stimulated due to **improvement in blood circulation**. Moreover, the **acrylic adhesive** develops its **full adhesive strength** during the first hours and bonds with the skin. Particularly during the training courses, when the tapes are removed after a short time, some participants react with slight reddening of the skin if the tape is removed after a few hours or the next day.

The reason for this is that the skin is freshly stimulated and the adhesive sticks well. When it is removed, it is possible that part of the **epidermis** comes away, which no longer happens after a few days of wear because the skin renews itself. Tape should also not be removed too abruptly from **sensitive areas** like the bend of the elbow and the hollow of the knee, otherwise small skin injuries may occur. With **sensitive skin**, e.g. in the elderly or small children, the tape should be left on longer because with each additional day it is easier to remove (skin renewal).

Important

This slight reddening quickly fades and is not a contraindication.

1.8 Contraindications

So far, there are no known **side-effects** of K-Taping. However, K-Taping applications should not be used with the following contraindications:

- open wounds
- scars which have not yet healed
- parchment-like skin, e.g. in acute episodes of neurodermatitis or psoriasis
- sacral connective tissue massage zone (genital zone) in the first trimester of pregnancy
- known allergies to acrylic

Prior to all applications, the therapist should first ask whether the patient is taking **anticoagulants**. Small hemorrhages may occur in the skin as a reaction to the lifting effect of the K-Taping application. Experience has shown that cardiac patients taking anticoagulants occasionally react to K-Taping with itching or skin eruptions. The reason for this reaction is not known.

The backing tape is sprayed with silicon to facilitate removal of the cotton tape from the backing. Even though this is minimal, silicon residue may stick to the adhesive. Silicon is generally used to make the tape kinder to the skin. Nevertheless, there are patients who react to silicon with slight reddening of the skin.

1.9 Color theory

The **original K- Tape** is used in the four colors: **cyan, magenta, beige, and black**.

There is no difference in the structure and properties of the tapes. They have identical stretching capacities. The colors have been chosen to support the treatment based on color theory. It should be mentioned at this point, however, that first and foremost the application technique is the critical factor and that color has been adopted as an additional positive aspect.

The **color red** is regarded as activating and stimulating, whereas the **color blue** is calming. Black and beige are classed as neutral.

The effect of color upon entering a room is well-known. If the walls are painted blue, this evokes different perceptions from a room with red walls. This holds true for K-Tape applications.

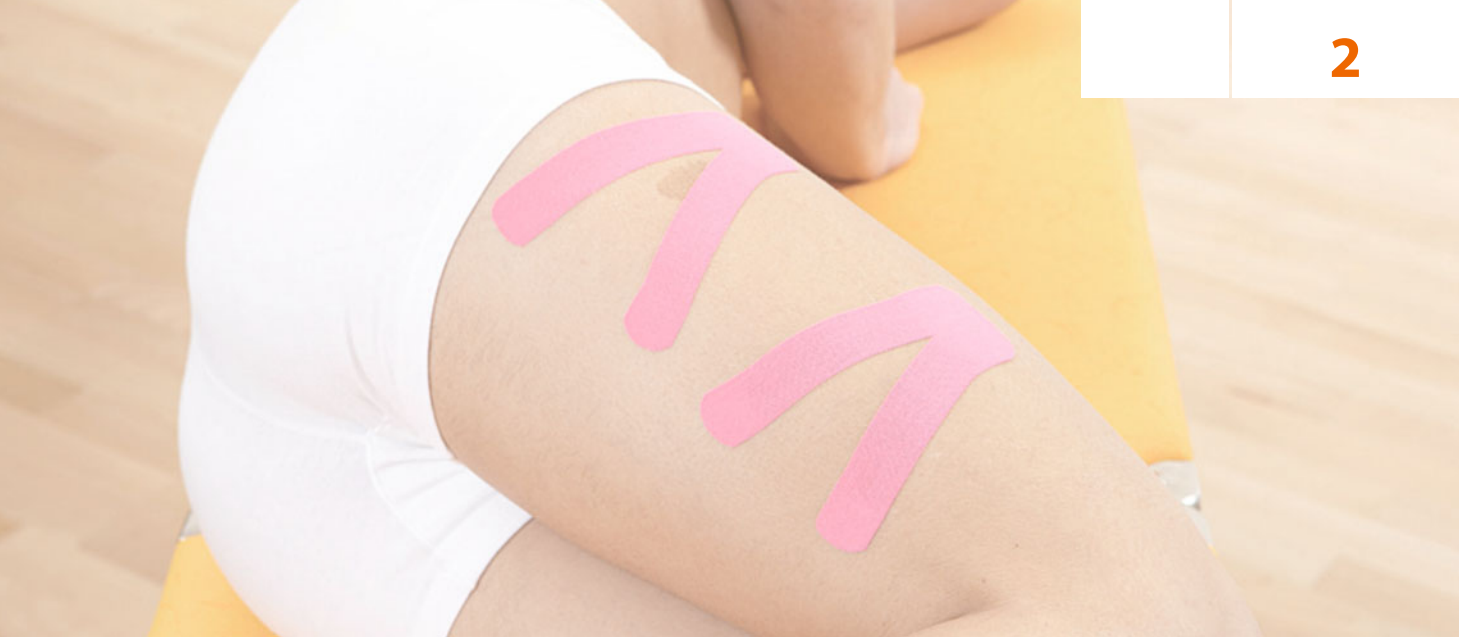If the therapist affixes red tape to hypertonic musculature, or to a structure already inflamed, most of the patients will react with further stimulation and discomfort. In contrast, the color blue has a calming effect. The therapist should take note of this effect.

K-Tape applications are thus carried out so that red tape is used to stimulate **weak, energy-deficient structures** and for muscle applications intended to increase tonus. Blue tape is used to calm **high-energy structures** and to lower muscle tonus. In some cases, the patient's vanity may decide, where the application needs to be unobtrusive. Particularly for lymph applications, which are affixed to large areas of skin, beige is used in most cases. As with the **placebo effect**, therapists should not ignore the effect of the color - but should not put this at the forefront of the treatment and mode of action.

1.10 Diagnosis

As with every method, a **detailed diagnosis** forms the basis of good K-Taping treatment. Not only the symptoms and localized pain should be treated.

Determining the cause is also desirable. Only then is precise targeting of the **self-healing process** possible. Every therapist and physician acquires a series of testing and diagnostic methods to help with this. By a process of elimination, information can be obtained about connections in disrupted processes, allowing conclusions to be drawn about the cause, which then point the way to subsequent therapy.



2 The Four Application Techniques

2.1 Muscle applications – 14

- 2.1.1 Muscle function – 14
- 2.1.2 Mode of action of the K-Taping – 14
- 2.1.3 Executing the application – 14

2.2 Ligament applications – 16

- 2.2.1 Ligament applications (Ligamenta) – 17
- 2.2.2 Ligament applications for tendons – 21
- 2.2.3 Space tape – 23

2.3 Corrective applications – 25

- 2.3.1 Functional correction – 25
- 2.3.2 Fascia correction – 27

2.4 Lymphatic applications – 28

- 2.4.1 Causes of lymphostasis – 28
- 2.4.2 Mode of action of lymphatic applications – 31

2.1 Muscle applications

Muscle applications are used for **increased** or **reduced resting muscle tone** (hypertonicity, hypotonicity), as well as for injuries to the musculature, and bring about a normalization of the resting muscle tone, reduction in pain, and improvement in resilience, which facilitate more rapid healing.

Muscle applications are affixed with **10% tape tension**. Because the tape is already pre-stretched by 10% on the roll, this is referred to as an **unstretched application**. The patient is placed in a **pre-stretched position** and the tape is applied with the 10% pre-stretching to the part of the body to be treated. Depending on the type of application, K-Taping can **effect increased** or **decreased tonus**.

During the **K-Taping training**, students are taught that a **tonus increasing application** is affixed from the muscle of origin to the muscle of insertion and for a **tonus-decreasing effect**, the application is affixed in the opposite direction, from muscle insertion to muscle origin. However, according to muscle movement and function, origin and insertion can change, and in these cases, the muscle applications are carried out contrary to the rules mentioned above. The classic portrayal whereby the muscle origin and insertion are rigidly prescribed does not, however, provide for this »alteration,« which may lead to misunderstandings for some therapists during training and in practice.

The illustration of muscle function using **punctum fixum** (fixed end) and **punctum mobile** (mobile end) is **helpful** since according to the function of the muscle, the fixed and mobile ends change positions.

! Tip

Tonus-increasing applications are affixed from punctum fixum to punctum mobile and tonus-decreasing applications from punctum mobile to punctum fixum.

This basic rule should be observed for each diagnosis, and the muscle application must be carried out accordingly.

In accordance with the **K-Taping training**, and in the interests of understanding previous publications, the designations **origin** and **insertion** continue to be used in this book. In the illustrations of muscle applications in which punctum fixum and punctum mobile deviate from the origin-insertion designation, this will be explicitly indicated.

As described in ► Chap. 1.7, muscle applications begin by affixing a **tension-free base**. The base is fixed using the hand (pressed onto the body) and displaced with the skin (**skin displacement**). For tonus increasing applications, this is carried out in the direction of origin (punctum fixum) and for tonus-decreasing applications in the direction of

insertion (punctum mobile). Displacement occurs up to the maximum **skin stretch** that does not trigger pain in the patient.

2.1.1 Muscle function

In carrying out movements, the muscle contracts, bringing the muscle insertion closer to the muscle origin, or, as explained in ► Chap. 2.1, the punctum mobile approaches the punctum fixum and the muscle fascia as well as the skin are displaced in the same direction.

2.1.2 Mode of action of the K-Taping

In a **tonus-increasing muscle application**, the elastic stretch tape exerts tension via the restoring force in the direction of origin (punctum fixum) to the fixed base, and thus displaces the skin in the same direction. This brings about **support of the muscle contraction**.

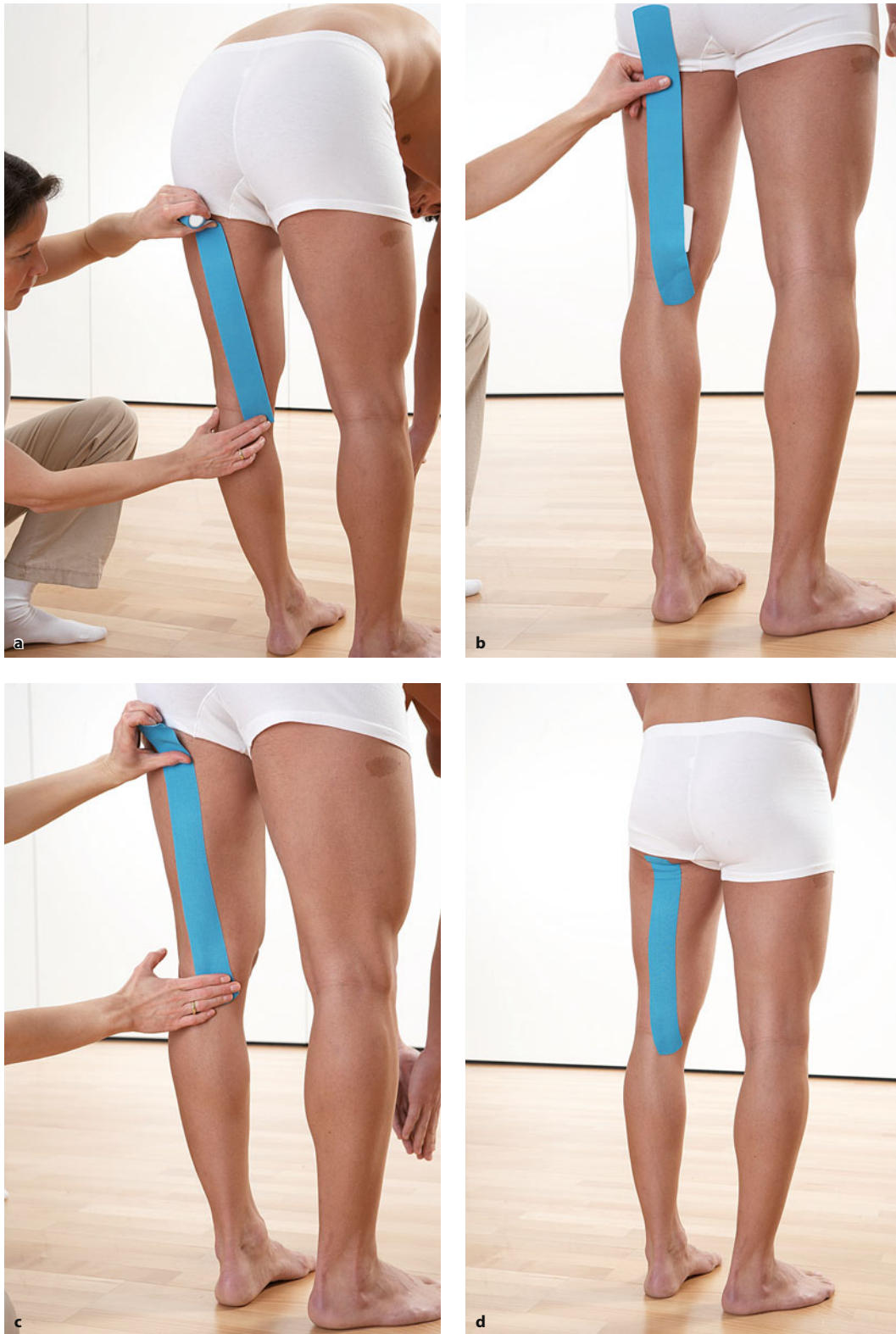In a **tonus-decreasing muscle application**, the elastic stretch tape exerts tension in the direction of insertion (punctum mobile) to the fixed base and likewise displaces the skin in the same direction. This causes a **reduction in muscle contraction**.

! Tip

In accordance with color theory, tonus-increasing applications are affixed using red tape (red = activating effect). Tonus-decreasing applications are affixed using blue tape (blue = calming effect).

2.1.3 Executing the application

- Measure the required tape strips on the patient with the muscles in the elongated position (■ Fig. 2.1a)
- If necessary, cut the tape strips into the appropriate form (e. g. Y-tape)
- Cut the corners at the tape ends into a rounded form
- Place the patient in the resting position
- Affix the base (■ Fig. 2.1b)
- Place the patient in position for the necessary muscle elongation
- The therapist affixes the base with one hand and then positions the skin (■ Fig. 2.1c)
- Affix the tape strips with the other hand along the course of the muscle with 10% stretch
- Rub the affixed tape strips while the muscle is elongated



■ **Fig. 2.1.** **a** Measure the tape with the muscle in the elongated position, **b** affix the base without muscle tension, **c** execute the application with elongated muscles, **d** completed muscle application

Memo

- The muscle application is affixed with 10% tape stretch.
- The patient is placed with the muscle in the elongated position.
- I- and Y-tapes are predominantly used.



■ **Fig. 2.2.**
blue I-Tape



■ **Fig. 2.3.**
Red Y-tape

2.2 Ligament applications

Ligament applications are used for injuries and overloading of ligaments (Lat.: *ligamenta*) and tendons. The same technique can be used to treat **pain points**, **trigger points**, or **spinal segments**. They bring about relief of symptoms, pain attenuation, and improvement in resilience and thus lead to more rapid healing and a reduction in rehabilitation time. The term »ligament application« does not, therefore, adequately describe the various application options, although it has become widely recognized for this application technique.

Ligament applications are affixed with **maximum tape stretch**. As with the muscle applications, the tape ends are applied unstretched for an improved period of wear. For ligament applications, the respective joint is positioned so that it is in a state of tension. For tendon applications, the muscles are maximally elongated, and for the treatment of pain points, the patient is placed in the **elongated muscle position**.

Two application techniques are used, depending upon whether tendons, ligaments, or pain points are to be treated (► Chap. 2.2.1-2.2.3).

Ligament and tendon areas are structures copiously provided with sensors, which form a close functional connection to joints and muscles. Afferents from the skin and subcutis can supplement the **deep sensibility** (proprioception) and attenuate the pain impulses (**nociceptive afferents**). K-Taping therapy uses these properties to influence bodily movement via skin stimulation.

2.2.1 Ligament applications (Ligamenta)

This application technique is used for ligaments which connect two adjacent bones, e.g. the collateral ligaments of the knee. In this case, the tape is affixed **en bloc**.

The backing paper is torn down the middle and detached to the sides so that only a two finger width of tape at each end (the bases) remain attached to the backing paper. The tape is then affixed **en bloc** with **maximum stretch** over the ligament structure up to the osseous insertion point. During this process, the joint is positioned so that the ligaments are under tension.

Only then is the backing paper removed from the tape ends, which are affixed without stretch.

! Tip

It should be noted that the joint must be placed in a position to achieve **maximum skin stretching beforehand in order to ensure that there is no force effect on the tape ends during movement. In this way, the respective bases remain tension-free during maximum movement.**

Ligament function

Two adjacent bones are connected by a ligament. According to the position of the joint, the ligaments are either tensed or relaxed and serve to **reinforce and guide the joint**. With the exception of the ligamenta flava between

the vertebrae, ligaments are only minimally extendible. They have numerous **nerves** and **mechanoreceptors** and are thus functionally involved in much more than providing mechanical support and direction. They provide **information** about the position, movement, and speed of the joint. In addition, they register extension and pain. There is a functional interrelationship between the capsules, the musculature, and the mechanoreceptors contained in the ligaments in **controlling joint movement**, in which the **capsule tension**, movement, and the **joint pressure** are continuously measured, and signals transmitted via the spinal segment to the respective joint. Through constant adaptation, the musculature can thus react to the current situation.

Mode of action of K-Taping

By first affixing the tape **en bloc** with maximum tension and only then attaching the bases, the tape is simultaneously anchored to both osseous insertion points.

In this way, the tape pulls the ligaments together towards the middle. Purely mechanically, it supports the ligament in such a way that in joint movement it is brought into the same state of tension as the tape. Moreover, through the concomitant displacement of the skin, which, according to the joint position and movement, is displaced towards the center or the base of the application, it triggers **receptor stimulation**, which, as described in ► Chap. 2.2.1, contributes to the effect on muscle function.

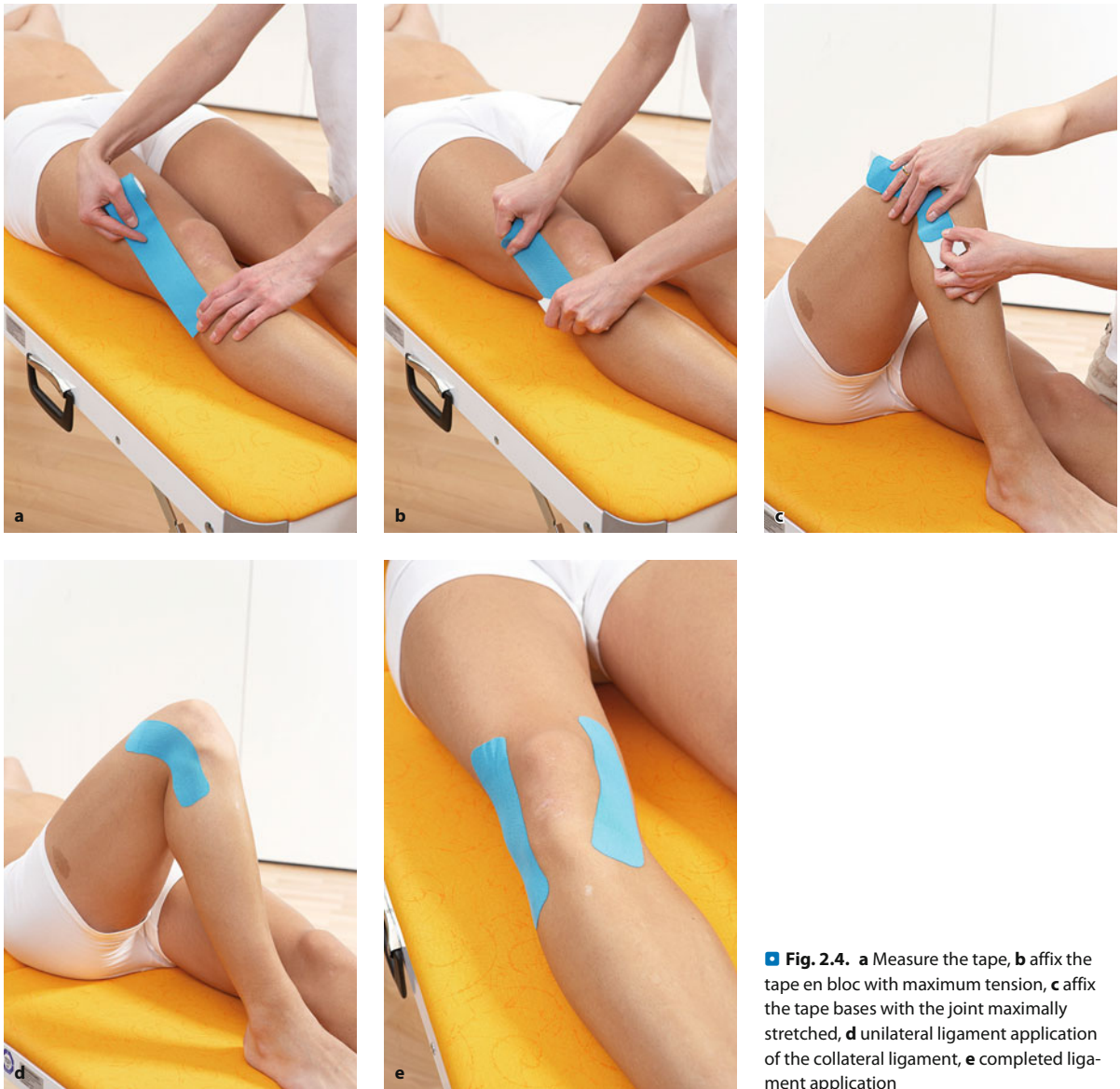

Fig. 2.4. **a** Measure the tape, **b** affix the tape en bloc with maximum tension, **c** affix the tape bases with the joint maximally stretched, **d** unilateral ligament application of the collateral ligament, **e** completed ligament application

Executing the application for ligaments

- Position the joint so that the ligament is in a state of tension.
- Measure the tape from insertion to insertion (■ Fig. 2.4a)
- Cut the tape strips and round the edges
- Tear the backing paper down the middle and remove up to the width required for the respective bases at the ends of the tape
- Apply maximum stretch to the tape and affix en bloc over the ligament structure (■ Fig. 2.4b)
- Position the joint so there is maximum skin tautness (■ Fig. 2.4c)
- Remove backing paper and affix the tape ends (■ Fig. 2.4d)

Memo

- The tape application for ligaments (ligament application) is affixed **en bloc with maximum stretch**.
- The joint is positioned so that the ligaments are under tension.
- Exclusively I-tapes are used.



■ Fig. 2.5.
Blue I-tape

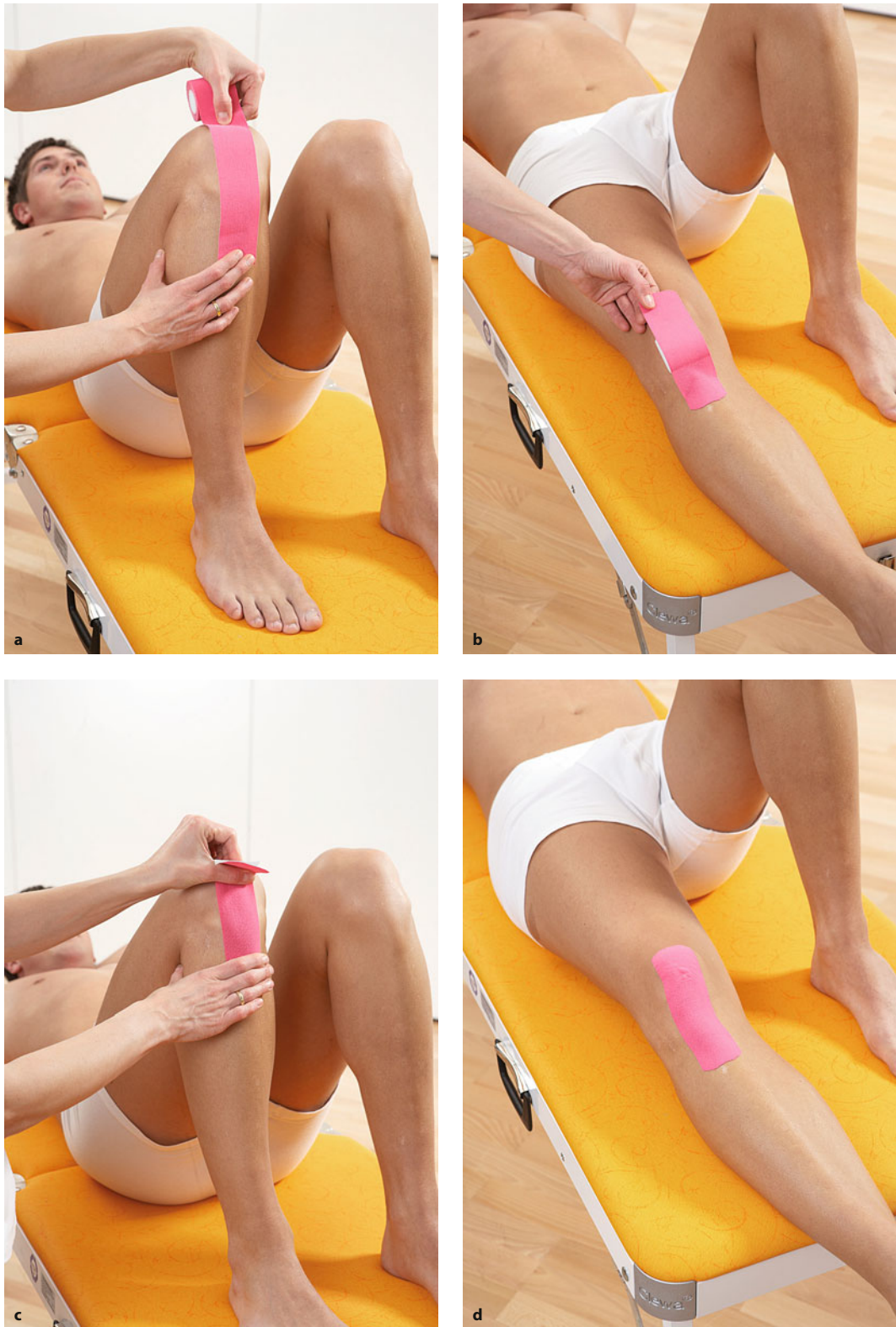

Fig. 2.6. **a** Measure the tape in the elongated position, **b** affix the base in the resting position, **c** affix the tape in the elongated position, **d** completed tendon application

2.2.2 Ligament applications for tendons

In this application technique, the tape is affixed over tendons, or tendon structures, from the muscle-tendon junction up to the osseous insertion.

In contrast to the application technique for ligaments, an **unstretched base** is first affixed over the osseous insertion point. The joint to be treated is subsequently placed in the **stretched** position. In this position, the base is affixed with the hand, and then the **skin displacement** occurs in the longitudinal direction of the tendons, in the opposing direction to the tape tension. Finally, the tape is affixed with maximum tension over the tendon structure. The tape end is affixed without tension over the musculature.

Through this tape application, the tape pulls towards the base, displacing the skin in the same direction.

Tendon function

As opposed to ligaments, which are connected to two bones, tendons are attached on one side to a bone and on the other side to the fascia of a muscle. They transmit the **tensile forces** of the muscles to the bones, triggered by contraction and gravity. They also have a proprioceptive sensory receptor organ, the **Golgi tendon organ**, which measures muscle tension and transmits this information to the point of insertion into the bones, thereby providing **overload protection**.

Mode of action of the K-Taping application

In tendon applications, K-Taping influences the tendons, fascia, and musculature. Mechanical support of the tendon function coupled with receptor stimulation through the skin displacement (afferents from the skin and subcutis) is involved, as is the effect on muscle tonus (see Muscle applications; ► Chap. 2.1), and the displacement of the fascia in the direction of the base.

Executing the application for tendons

- Muscles and consequently tendons are elongated; if the patient is not able to achieve this position alone, the therapist supports the movement **without causing pain**
- Measure the tape in the elongated position from insertion to muscle-tendon junction (■ Fig. 2.6a)
- Cut the tape strips and round the corners
- Bring the muscle into the resting position and affix the tape base at the insertion point (■ Fig. 2.6b)
- Place the muscle in the pre-stretched position
- The therapist affixes the base with one hand and displaces the skin (■ Fig. 2.6c)
- Affix the tape with maximum tension along the course of the tendon up to the muscle-tendon junction
- Affix the tape ends without tension over the musculature
- Rub the application in the elongated muscle position

Memo

- **The ligament application for tendons** is affixed **with maximum tension** from insertion to muscle-tendon junction.
- The patient is in the elongated muscle position.
- Exclusively **I-tapes** are used.



■ **Fig. 2.7.**
Red I-tape



Fig. 2.8. **a** Affix the first tape strip, **b** affix the second tape strip at a 90 degree angle, **c** affix the tape strips three and four at 45 degree angles, **d** completed space tape application

2.2.3 Space tape

Space tape describes an application that is affixed over a point in a cross or star shape using tapes of the same length. As with the ligament application, each tape is affixed en bloc with maximum tension. In general, **four strips are used for a star**. After affixing the first tape strip, the second is affixed at an angle of 90 degrees to form a cross. Strips 3 and 4 are applied at 45 degree angles to the cross.

This application is used for **pain points** and **trigger points**, **spinal segments**, **CTM zones** (connective tissue massage zones), and the iliosacral joint (ISJ). Depending upon the size of the body area to be treated, or when using for children, the lengths of tape can be halved. As a rule, the individual tape strips are 15 cm up to a maximum of 20 cm long (applied to the back) and for smaller parts of the body, e.g. elbows, they are shorter. In special cases, fewer than four strips may be used.

Mode of action of space tape

Space tape provides **selective lifting** of the skin and thus brings about a loosening of adhesions in the layers of tissue. Patients describe the result of this star-shaped application as a kind of **suction effect** with clearly noticeable lifting of the adhered structure. As the name already suggests, the space tape provides more space for the damaged structure and leads to **pain reduction**. Space tapes can also be used for mobilizing connective tissue.

Execution of the space tape application

- Bring the body into the elongated muscle position
- Measure and cut the tape strips (corners rounded)
- Tear the backing paper down the middle and remove up to the required width of the tape ends
- Affix the tape en bloc with maximum stretch, centered over the point to be treated (■ Fig. 2.8a)
- Affix the second tape strip in the same way at a 90 degree angle (■ Fig. 2.8b)
- Affix the third and fourth tape strips at 45 degree angles to the Cross-Tapes (■ Fig. 2.8c-d)
- Rub the application with the patient in the elongated muscle position

Memo

- Space tape is a space-creating application for pain points and trigger points.
- The application is carried out **with maximum tension**.
- The body is in the elongated muscle position.
- Exclusively I-tapes are used.



■ Fig. 2.9.
Blue I-tape

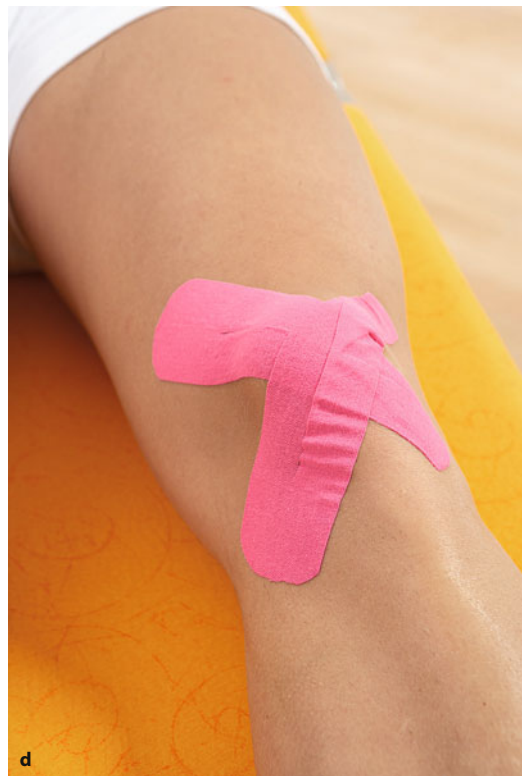
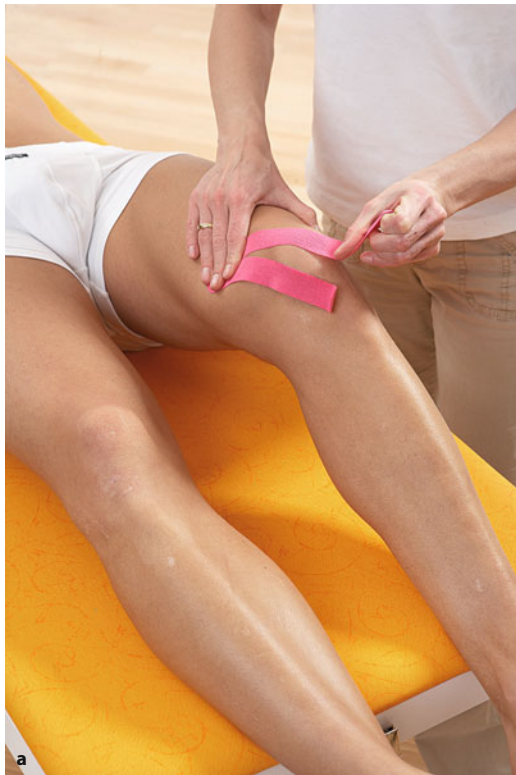
Fig. 2.10. **a** Anchor the base of tape 1 and affix the first tail strip, **b** affix the second tail strip in the upward movement position, **c** tape 2,

affix the first tail strip in the upward movement position, **d** completed corrective patella application in the resting position

2.3 Corrective applications

Corrective applications are divided into **functional correction** and **fascia correction**. Functional correction is used for osseous misalignments, e.g. patella misalignment, and brings about a **position shift** of the osseous structure. Fascia corrections are used for adhesions in muscle fibers and bring about a **loosening of the fascia** as well as **pain reduction**.

2.3.1 Functional correction

Functional corrective applications are always affixed over the osseous structures, since their position is to be corrected. In most cases, Y-tapes are used. The base and skin displacement are firmly anchored and the two tail strips are applied over the structure to be corrected. Functional corrective applications are affixed with **maximum pre-stretching** of the tape. The correction is thus directed towards the base. This must be taken into account when affixing the base. For applications to joints, the two tail strips are affixed with movement; in other cases, e.g. spine, they are affixed in the elongated muscle position. It should be noted that for a functional corrective application, the tail strips of the Y-tape are affixed individually, one after the other.

Causes of osseous misalignments

In most cases, osseous misalignments result from overexertion or one-sided strain on the musculature, tension, atrophy, or congenital misalignments. In all cases, misalignments lead to **disharmony of the musculature**, a disturbed balance between agonists and antagonists. Osseous misalignments may also be triggers for unilateral muscle use if they cause impairment of **functional processes** (e.g. through external trauma and the resulting protective posture and consequent disturbed movement sequences).

Mode of action of corrective functional applications

In functional corrective applications, two modes of action work together. On the one hand, there is a **gentle mechanical correction** stimulated by skin displacement, and on the other hand, there is the effect of receptor excitation on interactions in the affected muscle-tendon apparatus.

Executing the corrective functional application

- Measure the tape over the structure to be corrected
- Cut the tape strips and round off the corners

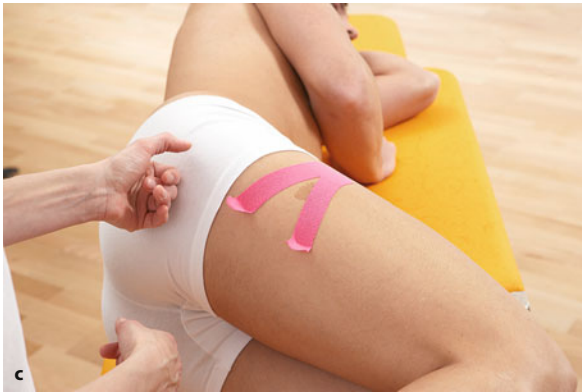- **Tape 1:** Affix the base in the relaxed position (■ Fig. 2.10a)
- Anchor the base and displace the skin maximally towards the desired correction
- Affix tail strip 1 with maximum tension over the structure to be corrected
- Affix the tape end (tail strip 2) unstretched with the joint maximally stretched or in the pre-stretched position (■ Fig. 2.10b)
- **Tape 2:** Affix tail strip 1 with maximum tension over the structure to be corrected in the upward movement position
- Affix tape end (tail strip 1) unstretched with the joint maximally stretched or in the pre-stretched position
- Affix tail strip 2 without stretch over the patella with the knee bent maximally (■ Fig. 2.10c)
- Rub the application in the pre-stretched position.

Memo

- Anchor the base and skin displacement firmly.
- The application is carried out **with maximum tape tension**.
- The correction via the tape strips runs towards the base.
- Y-tapes are predominantly used for functional correction, but I-tapes are also possible.



■ Fig. 2.11.
Red Y-tape



Fix. 2.12. **a** Measure the tape at right angles to the direction of the muscle direction, **b** rhythmically pull tail tapes, **c** affix the stretched tail

tapes; the tension-free ends are not yet affixed, **d** completed corrective fascia application using two Y-tapes

2.3.2 Fascia correction

Fascia corrective applications are used for fascia adhesions of the musculature and are carried out using a **Y-tape**. In contrast to functional corrections, the tail strips are fixed simultaneously. The base is not anchored, but is moved along through the parallel tension in the tails, thus displacing the pain point. Viewed from the position of the force direction, the base is in front of the **pain point**. The therapist checks the direction in which the fascia can more easily be displaced beforehand. This direction is the force direction in which the tail tapes are affixed. Unlike the previous applications, which are affixed with equal speed, the tape is applied with rhythmic extension. The tail tapes are applied slowly with a **rhythmic movement** up to the maximum possible tension. This does not mean the maximum stretch capacity of the tape fibers, but the **threshold range** that can be applied over the structure. This can be, e.g., overlapping of skin folds. The tape strips are affixed when the threshold state is reached. The tape ends are affixed without tension here, too. During the execution of this application, the patient is in the resting position. Pre-stretching is only necessary in the area of the joints, in order to affix the tape ends.

The fascia correction technique can be used in individual cases as a substitute for functional correction if a more finely-tuned correction is desired. In this case, instead of the Y-tape, an I-tape is used, and the tape strips are applied evenly with variable tension and not rhythmically. The critical effect here is the forward displacement of the base.

Causes of fascia adhesions

Fascia adhesions can arise from tension, one-sided strain, and overstrain of the musculature.

Mode of action of corrective fascia applications

The fascia is mechanically shifted through the forward displacement of the base. To determine the base position, the direction in which the fascia is freely displaceable is first manually determined. Though bodily movement, the fascia application causes the muscle fibers to work continuously against the fascia. This results in a gradual loosening and separating of the adhesions.

Executing the corrective fascia application

- Test the fascia displaceability.
- Measure the tape in the resting position and cut the Y-tape (corners rounded) (■ Fig. 2.12a)
- Affix the base below the pain point
- Rhythmically pull the tail strips up to the threshold state, thereby displacing the base (■ Fig. 2.12b)
- Affix the tail strips while retaining the tension (■ Fig. 2.12c)
- Affix the tension-free tape ends.

Memo

- The patient is in the resting position.
- The **rhythmic pulling technique** is possible up to maximum stretch, but the limits of the structure must always be considered
- The base is not fixed.
- The correction runs in the direction of tension of the tape strips.
- Y-tape is used for the corrective fascia application.
- Functional correction is also possible using I-tape.



■ Fig. 2.13.
Red Y-tape

2.4 Lymphatic applications

Lymphatic applications are used in **disorders of lymphatic drainage**. The lymphatic application brings about lifting of the skin. The space between the skin and subcutaneous tissue is thus increased, thereby stimulating the lymphatic **collectors** to resume their function. The collectors are the active **vascular transport systems** of the human body. To prevent a back-flow of lymph, there are valves within the transport system which ensure a central flow. The segment between two valves is called a **lymphangion** and through its contractions, it can propel the lymph forwards.

In addition, through the lifting by the tape in combination with bodily movement, the skin and underlying tissue are stretched. The result of this is that fibrous bridges can be loosened and/or prevented.

With lymphatic applications, a fundamental differentiation is made between

- an intact lymph node chain, and
- partial or complete removal of lymph nodes.

Intact lymph node chain

With intact lymph node chains, tapes are applied in most cases with a common base from which four narrow longitudinal strips are cut, radiating out from the base.

The common base creates a **low compression zone** which provides the lymph with a clearly defined drainage channel.

Defective lymph node chain

This technique is also used with defective lymph node chains; in this case, however, **individual tapes** cut into narrow strips are more frequently used. In the region of the extremities, these long, narrow strips are applied radially in the zone to be drained, thus leading to extensive drainage, with the advantage of **tissue connection** for preventing **fibrosis formation**.

When using K-Taping application with an intact lymph node chain, attention must be paid to the **anatomical watersheds**.

Watersheds are **zones low in lymphatic vessels** which separate the individual **lymph node groups** (tributary areas = drainage area of the lymph nodes) from each other. Watersheds, however, are not insurmountable barriers since a superficial, valveless lymphatic capillary network covers the entire body. Likewise, there are **pre-lymphatic channels** (junctions between blood and lymphatic capillaries) which bridge the **lymphatic watersheds**. At certain points between the large lymphatic vessels of the trunk wall there are also junctions to the **collectors** of adjacent **territories**

(interaxillary anastomoses between the right and left axillae in the area of the sternum and the scapulae and axillo-inguinal anastomoses in the area of the flank between axilla and groin).

The distribution of the watersheds gives rise to **four lymphatic territories**, also known as **quadrants**, in the trunk.

Two watersheds run horizontally, one at the height of the umbilicus, the other at the height of the clavicles, and one watershed runs vertically down the central axis of the trunk.

In the area of the buttocks, there is a **»seat of the pants« watershed** which forms a dorsomedial and dorsolateral thigh territory.

When the **lymph node chain** is **not intact**, the lymph capillaries and pre-lymphatic channels as well as the anastomoses are used, through K-Taping, to transport the accumulated **lymph-obligatory load** to a healthy quadrant with intact lymph nodes.

2.4.1 Causes of lymphostasis

Edemas have various causes. They are differentiated into high volume insufficiency, low volume insufficiency, and safety valve insufficiency.

High volume insufficiency

In high volume insufficiency, the lymphatic vessels are healthy and the transport capacity of the lymphatic system is normal. However, the **lymph-obligatory load** (lymph fluid) is higher than the possible transport capacity. This leads to **extracellular edema** (► Overview 2.1).

There are numerous reasons for this, e.g. trauma and organic disease. Trauma causes injury to the lymph vessels, and in organic disease, predominantly the heart (chronic venous insufficiency – Stage I, CVI I) and kidneys (hyperproteinuria) are impaired. Consequently, there is an excess of fluid through **pressure differences**. The organic disease must be adequately controlled with medication if K-Taping therapy is to be carried out.

Overview 2.1: High volume insufficiency

- healthy lymphatic vessels
- normal transport capacity
- however, the lymph-obligatory load (or »lymph fluid« or net filtrate) is temporarily greater than that which the body can currently remove
- **Result:** fluid is retained in the tissue and extracellular edema results

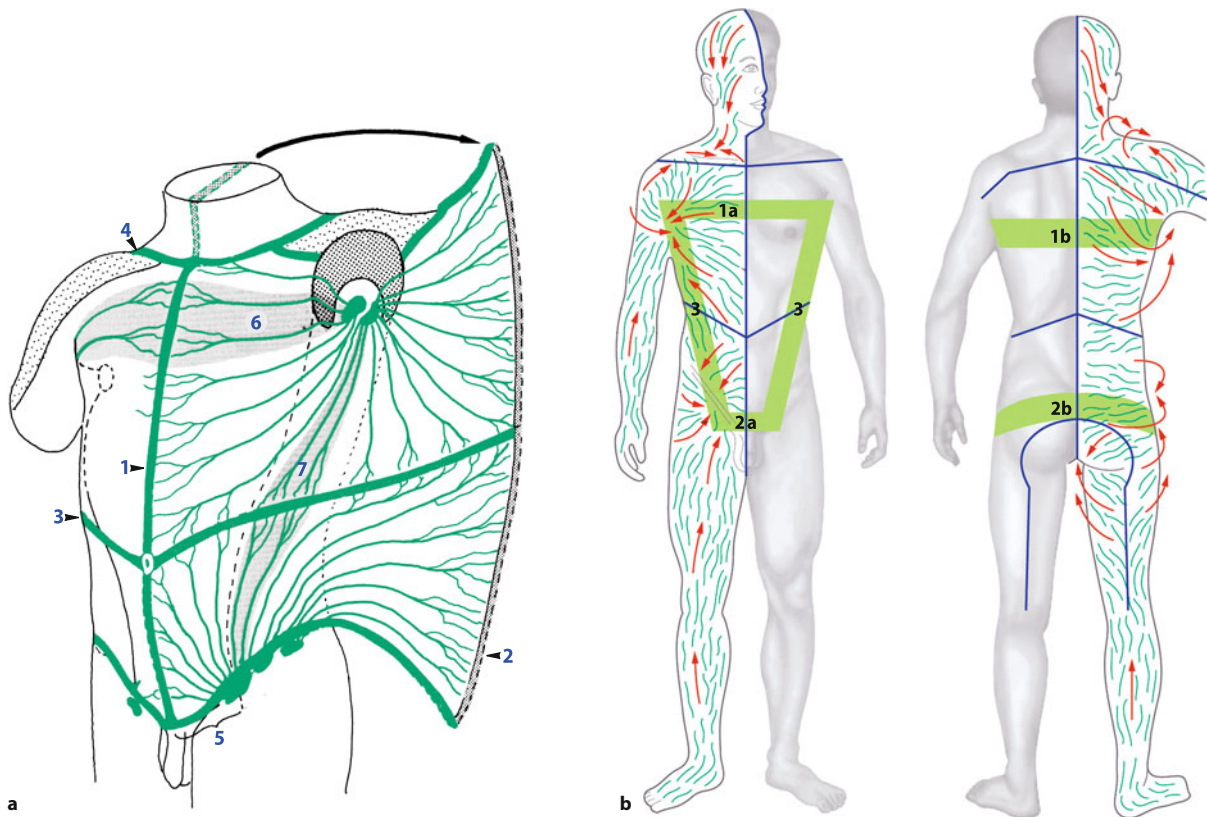


Fig. 2.14. **a** Superficial lymphatic vascular system with therapy-relevant watersheds, a ventral and dorsal overview, 1 ventral vertical watershed, 2 dorsal vertical watershed, 3 transverse watershed, 4 watershed at clavicular height, 5 "seat of the pants" watershed, 6 ventral interaxillary anastomosis, 7 axillo-inguinal anastomosis;

b diagram of trunk wall with the watersheds and direction of drainage of the lymph; the anastomotic pathways are shown in green, 1a ventral interaxillary anastomosis, 1b dorsal interaxillary anastomosis, 2a ventral interinguinal anastomosis, 2b dorsal interinguinal anastomosis, 3 axillo-inguinal anastomosis

Low volume insufficiency

In low volume insufficiency, there are disorders of the lymph vessels and **limited transport capacity** of the lymph system; the lymph-obligatory load, in contrast, is within the normal range. Lymphedema requiring treatment develops (► Overview 2.2).

The causes may be **primary** or **secondary lymphedema**:

- Primary lymphedemas are congenital developmental disorders or damage to the lymphatic vessels and/or lymph nodes.

Secondary lymphedemas arise from damage to the lymph vessels and lymph nodes by tumors, surgery, or radiation and these are the cases where K-Taping lymph applications are most frequently used in daily practice.

Overview 2.2: Low volume insufficiency

- diseased lymphatic systems
- restricted transport capacity with normal accumulation of lymph-obligatory loads

Result: lymphedema requiring treatment arises

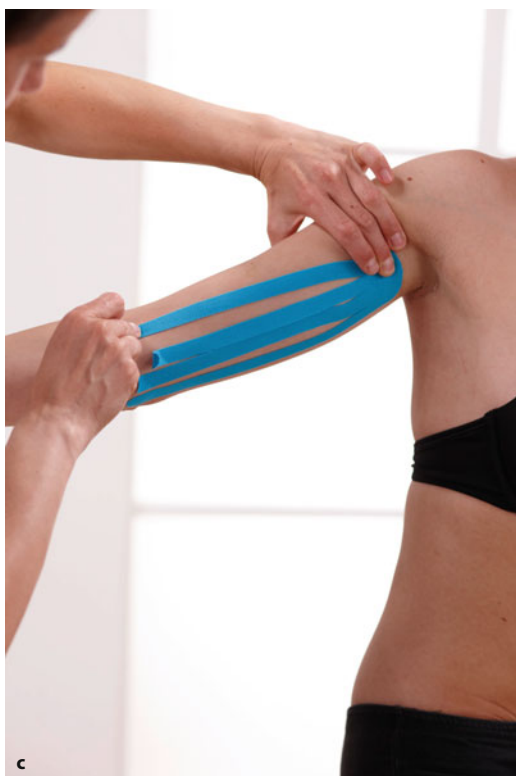
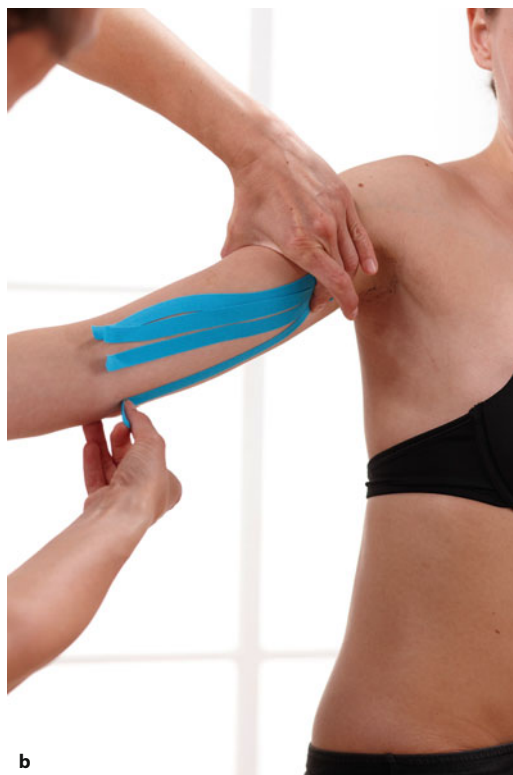
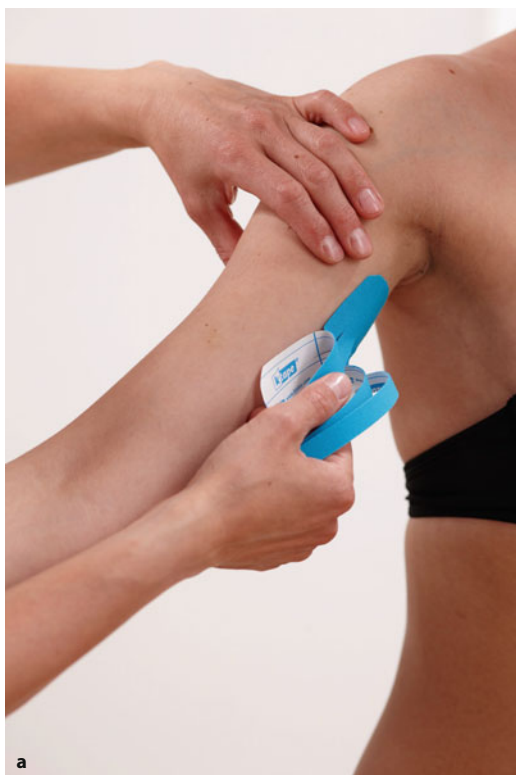Fig. 2.15. **a** Affix the base in area of the axilla, completely remove the backing paper and lightly fix the ends, **b-c** position the joint with the required pre-stretch, anchor the base with skin displacement,

detach the tape strips one after the other and apply them evenly with 25% tension to the inner side of the upper arm **d** completed application to inner side of upper arm

Safety valve insufficiency

Safety valve insufficiency is a reaction to undiagnosed or untreated high volume insufficiency (► Overview 2.3).

Safety valve insufficiency is a reaction to a persistent, high volume insufficiency that results in a lowering of the transport capacity. The lymphangions have to work too hard and the pressure in the lymphatic vessels is too high (lymphatic hypertension). The consequence is **valve insufficiency** with subsequent **mural insufficiency**. This eventually results in hardening of the lymphatic vessels (lymph-angiosclerosis). In the worst case, there is cell death in the affected area.

In this case, too, the K-Taping lymphatic application supports **manual lymph drainage** and **compression treatment**.

Overview 2.3: Safety valve insufficiency

diseased lymphatic systems
diminished transport capacity with increased lymph-obligatory load

Result: valve insufficiency, mural insufficiency, lymph-angiosclerosis, cell death in the affected area.

2.4.2 Mode of action of lymphatic applications

The elasticity of the material together with pre-stretching the body during the application brings about **lifting of the skin**. In this way the subdermal substance is pulled towards the epidermis, resulting in an **opening of the initial lymphatic valve**.

The everyday **bodily movements** of the patient against the self-adhesive tape on the skin bring about interposition of connective tissue towards the epidermis, thereby loosening the connective tissue. As a consequence, the filaments between the epithelial cells of the **lymphatic capillaries** (initial lymphatic vessels) and the elastic fibers of the connective tissue are more mobile. Thus the valves of the initial lymphatic vessels open more easily and the lymph drains more quickly. Any existing protein bridges can be more easily broken down and **fibrosclerotic changes** can be retarded or prevented.

A further effect is the **channeling function of the tape**. Fluid has the property of flowing along predetermined

channels and being affected by pressure differences. The affixed tape strips cause a pressure difference between the taped area and the adjacent tissue and thus determine the direction of flow. The K-Tape ensures rapid movement of lymph along the affixed channels in the desired direction.

These three **primary effects** form the basis of a **continuous lymphatic drainage** during the entire period of wear (► Chap. Overview 2.4).

Overview 2.4: Primary effects of continuous lymphatic drainage

creating space by lifting the skin
loosening the connective tissue through bodily movements against the tape
channeling function of the tape

Execution of lymphatic applications with a common base:

- Measure the required tape strips with the affected part in the elongated position
- Cut the tape strip longitudinally into 4 equal strips
- Round the corners of the tape ends with scissors
- Place the patient in a the resting position
- Affix the base (► Fig. 2.15a)
- Completely remove the tape backing and lightly affix the ends
- Place the patient in the required stretched joint position
- The therapist fixes the base with one hand and adjusts the skin displacement
- With the other hand, detach the tape strips one after the other and distribute them evenly over the area to be treated with 25% tension (► Fig. 2.15b-c)
- Affix the tape ends without tension
- Carefully rub the tape strips with the patient in the pre-stretched position

Memo

- The lymphatic application is affixed with **25% tension** in the tape.
- The patient is in the pre-stretched position.
- Exclusively fan tapes are used.

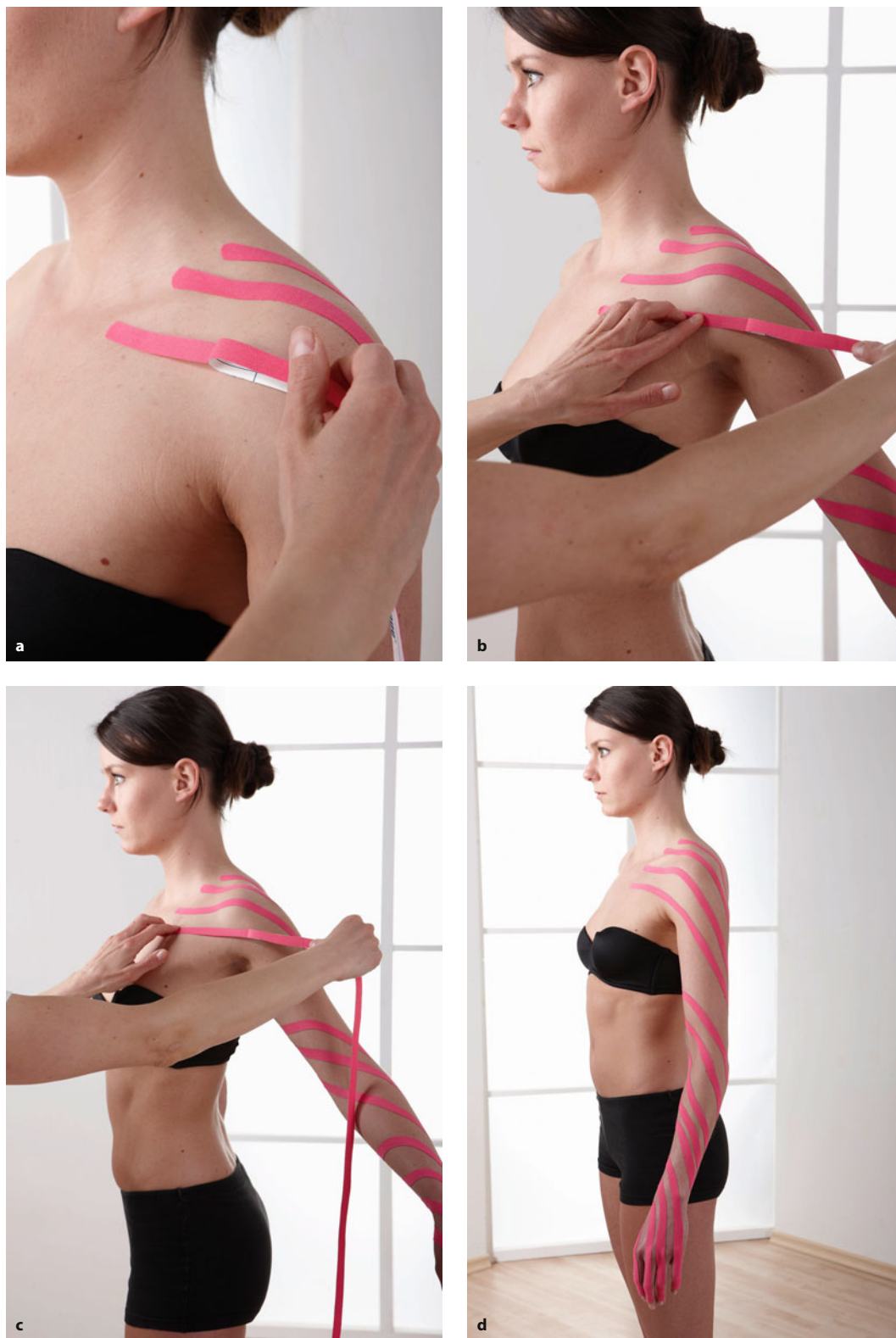

Fig. 2.16. **a** Affix the base in the area of the terminus and below the clavicle, remove tape backing gradually; the extremity is slightly abducted, **b-c** fix the base with skin displacement and apply the tape

strips without tension radially around the extremity, carefully rubbing the tape strips, **d** completed application

Execution with individually quartered I-tape strips:

- The tape is measured by wrapping it round the extremity in four to five spirals.
- Cut the tape strips longitudinally into four strips of equal width
- Round the corner of the tape with scissors
- Place the patient in the resting position
- Affix the base
- Always remove the tape backing gradually during the application (■ Fig. 2.16a)
- The extremity is slightly abducted
- The therapist fixes the base with one hand and displaces the skin
- Apply the tape strips radially around the extremity without tape tension (■ Fig. 2.16b-c)
- Carefully rub the tape strips

Memo

- The lymphatic application is affixed **without tape tension**.
- The patient is in the resting position.
- Exclusively I-tapes are used.



3 Muscle Applications

3.1 Muscle applications for the upper extremities – 37

- 3.1.1 Trapezius – 37
- 3.1.2 Deltoid – 39
- 3.1.3 Biceps brachii – 41
- 3.1.4 Triceps brachii – 43
- 3.1.5 Infraspinatus – 45
- 3.1.6 Extensor carpi radialis longus muscle – 47

3.2 Muscle applications for the trunk – 49

- 3.2.1 Pectoralis minor – 49
- 3.2.2 Pectoralis major – 51
- 3.2.3 Rectus abdominis – 53
- 3.2.4 External oblique – 55
- 3.2.5 Internal oblique – 57
- 3.2.6 Iliacus – 59
- 3.2.7 Intrinsic back musculature (erector spinae), application for the lumbar region – 61

3.3 Muscle application for the lower extremities – 63

- 3.3.1 Adductor longus – 63
- 3.3.2 Rectus femoris – 65
- 3.3.3 Biceps femoris – 67
- 3.3.4 Semimembranosus – 69
- 3.3.5 Iliacus maximus – 71
- 3.3.6 Tibialis anterior – 73
- 3.3.7 Extensor hallucis longus – 75

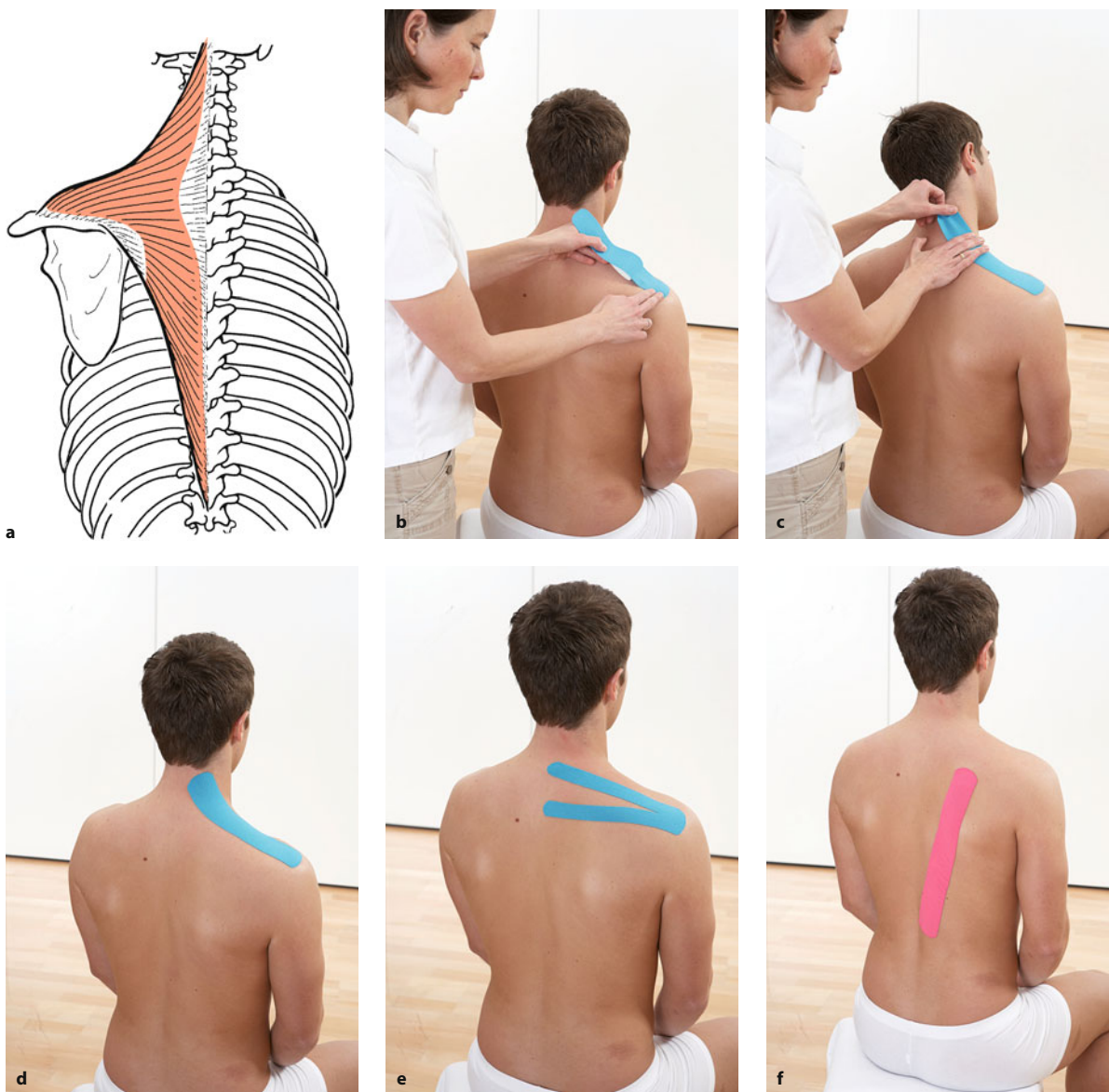

Fig. 3.1. **a** Trapezius muscle, **b** affix the base in the resting position, **c** affix the tape with the muscle in the elongated position, **d** tonus-decreasing application [blue], descending trapezius muscle fibers, base acromion, **e** tonus-decreasing application [blue], transverse trapezius muscle fibers, base acromion, **f** tonus-increasing application [red], ascending trapezius muscle fiber, base T12.

3.1 Muscle applications for the upper extremities

- 3.1.1 Trapezius
- 3.1.2 Deltoid
- 3.1.3 Biceps brachii
- 3.1.4 Triceps brachii
- 3.1.5 Infraspinatus
- 3.1.6 Extensor carpi radialis longus

3.1.1 Trapezius

Origin

- Descending: superior nuchal line, external occipital protuberance, ligamentum nuchae
- Transverse: C7–T3
- Ascending: T2/3–T12

Insertion

- Descending: lateral third of clavicle
- Transverse: end of clavicle, acromion, spine of the scapula
- Ascending: trigonum spinae

Function

Positioning the pectoral girdle; it actively pulls the scapula and clavicle towards the spine. The upper fibers lift and turn the scapula outwards; the lower fibers lower and turn the scapula inwards.

Innervation

Accessory nerve

Application

This example illustrates a tonus-decreasing muscle application to the descending fibers of the trapezius muscle.

The tape is measured from the middle of the acromion to the hairline on the nape of the neck. The descending part

of the trapezius muscle is in the elongated position, i.e. the cervical vertebrae (CV) are tilted towards the opposite side, flexion and rotation to the same side.

The base is affixed to the insertion site of the acromion in the resting state (■ Fig. 3.1b)

The muscle is elongated and the base anchored with skin displacement, then the tape is affixed with 10% tension over the belly of the muscle to the point of origin at the hairline on the nape of the neck (■ Fig. 3.1c)

The tape is rubbed in the elongated muscle position.

■ Fig. 3.1d shows the completed muscle tonus-decreasing application for the descending fibers of the trapezius muscle.

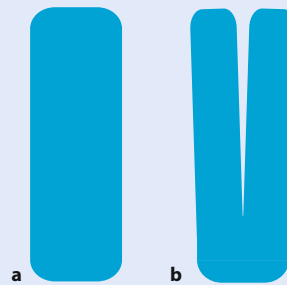
■ Fig. 3.1e shows the completed tonus-decreasing muscle application for the transverse fibers of the trapezius muscle using a Y-technique. The base lies over the acromion.

■ Fig. 3.1f shows the completed tonus-increasing muscle application for the ascending fibers of the trapezius muscle. The base lies over the 12th thoracic vertebral body.

Memo

Application: Muscle technique

Cutting technique: I-tape and Y-tape respectively in the application for the transverse fibers and in combination with the descending fibers



■ Fig. 3.2. a blue I-tape, b blue Y-tape

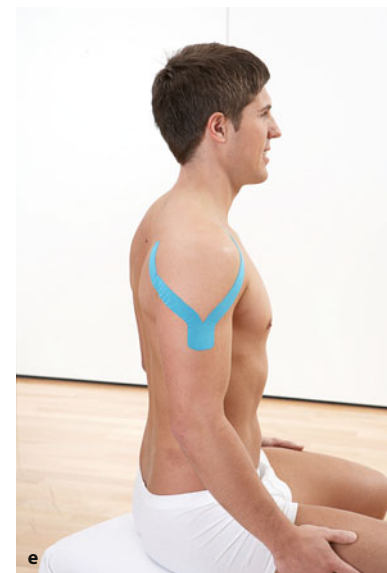
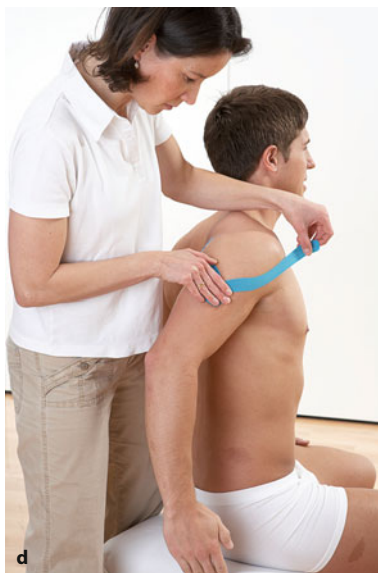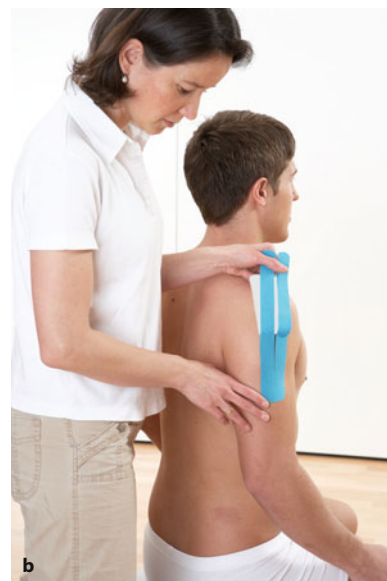
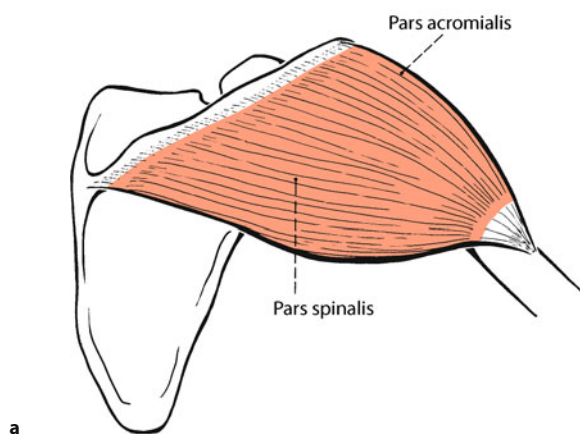


Fig. 3.3. a Deltoid muscle, b tonus-reducing application [blue]. Base is affixed below the insertion. The insertion lies approximately at the

bifurcation point of the Y-tape. Application to posterior fibers c Application to anterior fibers, d completed application in resting position

3.1.2 Deltoid

Origin

- Anterior fibers: lateral third of clavicle
- Middle fibers: acromion
- Posterior fibers: lower lip of the spine of the scapula

Insertion

Deltoid tuberosity of humerus

Function

Abduction, adduction, anteversion and retroversion of the shoulder joint

Innervation

Axillary nerve

Application

This example illustrates a tonus-decreasing application to the deltoid muscle.

The tape is measured from the middle of the acromion to 3-4 finger widths below the deltoid tuberosity. The addition of the 3-4 finger widths of tape means that measurement in the elongated position is unnecessary

The base is affixed in the resting position at the point of insertion below the deltoid tuberosity so that the bifurcation point of the Y-tape lies on the deltoid tuberosity and the individual tail strips can thus be fixed more easily along the muscle margin (■ Fig. 3.3b).

The muscle is elongated and the base anchored with skin displacement. For the posterior fibers of the deltoid muscle, the arm is placed in the flexed position. Affix the tape with 10% stretch along the muscle margin to the point of origin at the spine of the scapula (■ Fig. 3.3c).

For the anterior fibers of the deltoid muscle, the arm is placed in the extended position and the tape affixed with 10% stretch along the muscle margin to the point of origin at the clavicle (■ Fig. 3.3d).

The tape is rubbed in the elongated muscle position.


■ Fig. 3.3e shows the completed muscle application for the deltoid muscle.

Memo

Application: Muscle technique

Cutting technique: Y-tape

The base lies below the insertion.



■ Fig. 3.4. Blue Y-tape

! Tip

Measuring the tape without pre-stretching the shoulder is also possible. The tape is then measured in the resting position from origin to insertion and, in addition, the tape length is increased by 3-4 finger widths.

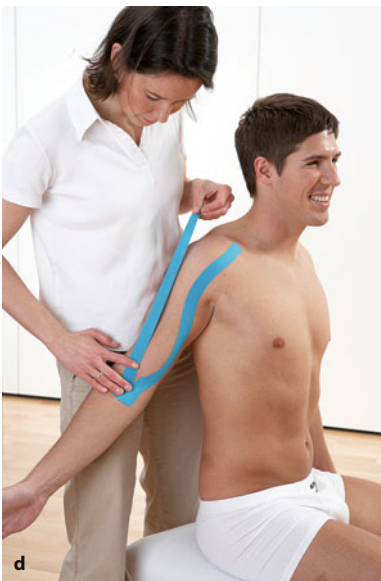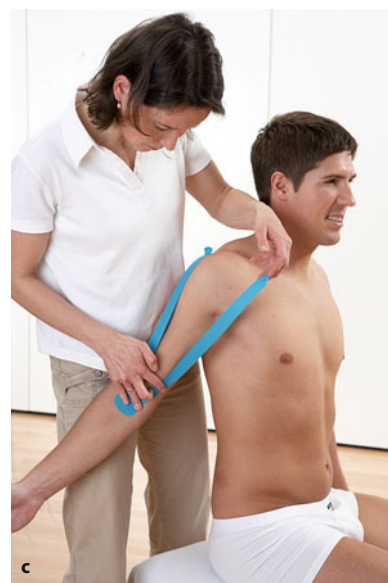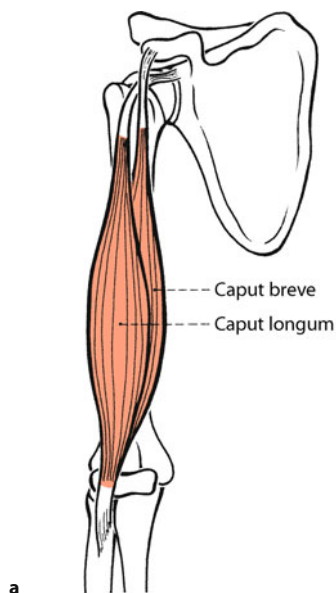


Fig. 3.5. **a** Biceps brachii muscle, **b** tonus-reducing application [blue]. Measure with the muscle in the elongated position, **c** base at the point of insertion. Apply the first tail strip in the elongated position, **d** apply the second tail strip round the margin of the muscle, **e** completed application for the short head

3.1.3 Biceps brachii

Origin

- Long head (two-joint muscle): Supraglenoid tubercle (long tendon). The first section of the tendon passes freely through the shoulder joint
- Short head: short tendon from the apex of the coracoid process of the scapula

Insertion

Radial tuberosity and bicipital aponeurosis insert into the deep fascia of the ulnar side of the forearm

Function

- Flexes and supinates the forearm, tenses the antebrachial fascia.
- Effect on the shoulder joint: the long head abducts and the short head adducts the shoulder joint.

Innervation

Musculocutaneous nerve (brachial plexus)

Application

This example illustrates a tonus-reducing muscle application to the biceps brachii muscle (short head).

The tape is measured from the crook of the elbow to the coracoid process. The arm is extended and lightly pronated. The small degree of pronation makes it easier to affix the tape (■ Fig. 3.5b).

The base is attached to the insertion point of the muscle in crook of the elbow in the resting position.

The muscle is elongated with extension and pronation and the base anchored with skin displacement. The tape is affixed with 10% stretch along the muscle margin up to the origin of the short biceps head at the coracoid process (■ Fig. 3.5c-d).

The tape is rubbed in the elongated muscle position.

■ Fig. 3.5e shows the completed muscle application for the biceps brachii (short head).

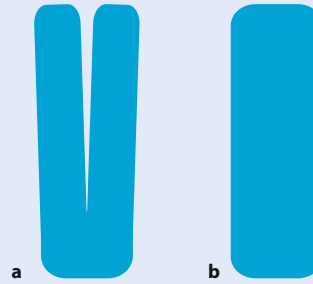
Memo

Application: Muscle technique

Cutting technique: Y-tape is use for the treatment of the **short** and **long head**.

I-tape is used for the treatment of the short head.

For greater muscle masses, the application can also be carried out using the Y-technique with both tail strips culminating on the short head.



■ Fig. 3.6. a Blue Y-tape, b Blue I-tape

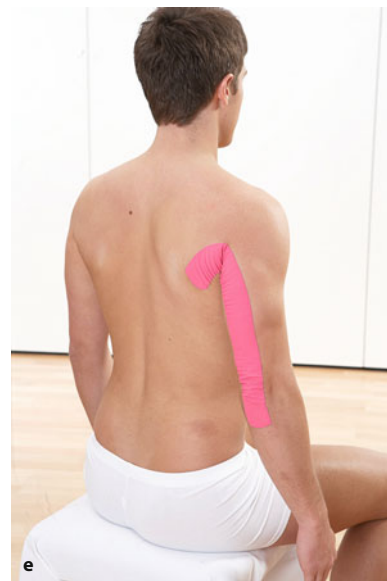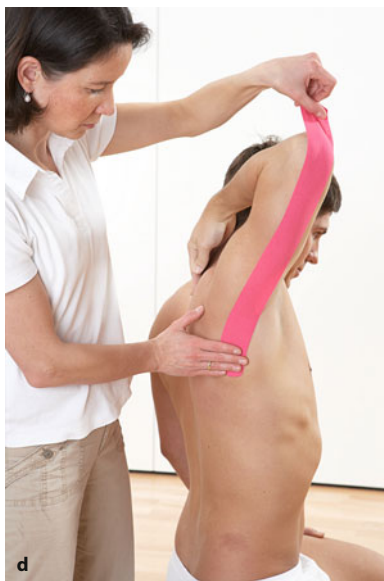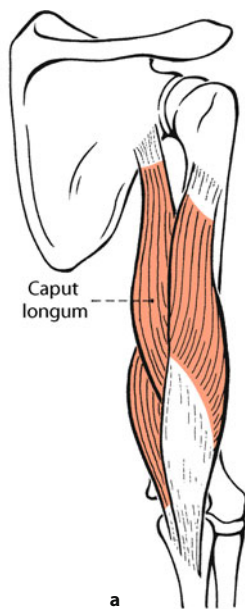


Fig. 3.7. **a** Triceps brachii muscle, **b** measure the tape with the muscle in the elongated position, **c** muscle-toning application [red]. Base affixed to origin, **d** apply and rub tape with the muscle in the elongated position, **e** completed application in the resting position

3.1.4 Triceps brachii

Origin

- Long head (two-joint muscle): infraglenoid tubercle of scapula
- Lateral head (one-joint muscle): lateral and proximal to the groove of the radial nerve, from the dorsal surface of the humerus
- Medial head (one-joint muscle): distal to the groove of the radial nerve, from the dorsal surface of the humerus, and from the medial and lateral intermuscular septa

Insertion

Olecranon process of the ulna; the fibers of the three heads of the muscle converge to form a single tendon.

Function

Extension in elbow joint; adduction and retroversion in shoulder joint

Innervation

Radial nerve (brachial plexus)

Application

This example illustrates a tonus-increasing muscle application to the triceps brachii muscle. The tape is measured from the shoulder blade to the elbow. The arm is positioned with shoulder and elbow flexion (■ Fig. 3.7b).

The base is affixed to the point of origin at the shoulder blade in the resting position (■ Fig. 3.7c).

The muscle is elongated and the base anchored with skin displacement. The tape is then affixed with 10% stretch over the belly of the muscle to the point of insertion at the elbow (■ Fig. 3.7d).

The tape is rubbed in the elongated muscle position. ■ Fig. 3.7e shows the completed muscle application for the triceps brachii.

Memo

Application: Muscle technique

Cutting technique: I-tape



■ Fig. 3.8. Red I-tape

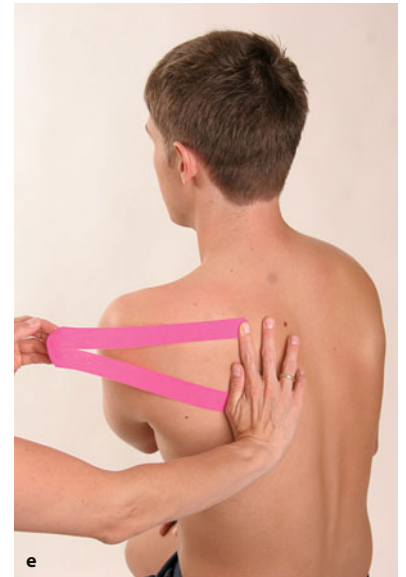
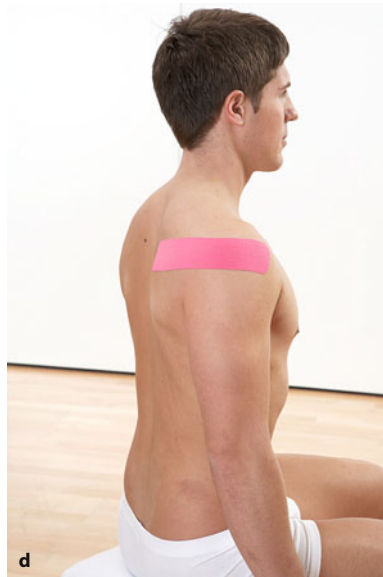
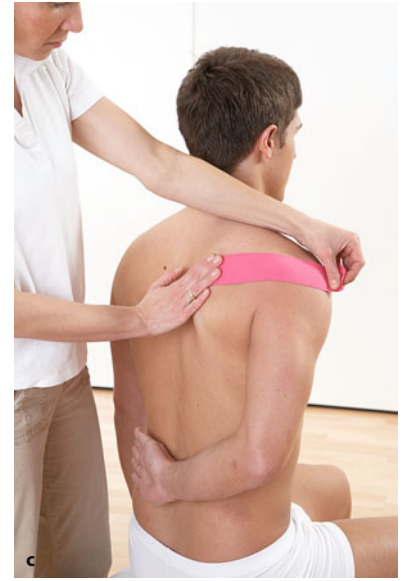
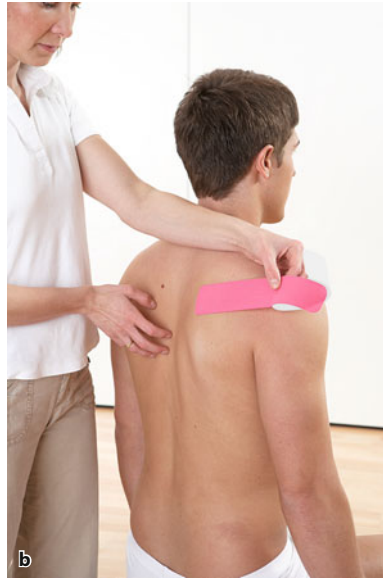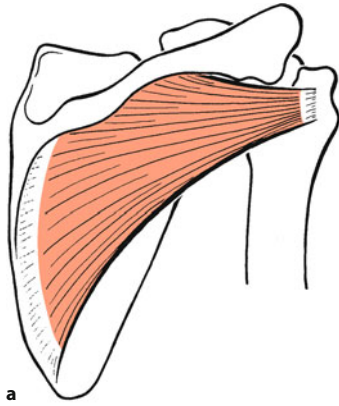


Fig. 3.9. **a** Infraspinatus muscle, **b** affix the base on the origin, **c** apply the tape to the elongated muscle, **d** completed application, **e** alternative: because there is a large origin area, the Y-technique may be used here with the base on the tail tape side

3.1.5 Infrapinatus

Origin

Infraspinous fossa, caudal edge of the spine of the scapular

Insertion

Middle facet of the greater tubercle of the humerus

Function

Externally rotates in the shoulder (rotator cuff) and abducts (cranial fibers), strengthens the shoulder joint capsule and thus acts as capsule tensor.

Innervation

Suprascapular nerve (supraclavicular part of the brachial plexus)

Application

This example illustrates a muscle-toning application to the infrapinatus muscle.

The tape is measured from the vertebral border of the scapula to the greater tubercle (of humerus) with adduction and inner rotation of the arm.

The base is affixed to the origin at the infrapinatus fossa in the resting position (■ Fig. 3.9b).

The muscle is elongated and the base anchored with skin displacement. The tape is then affixed with 10% stretch over the muscle belly to the insertion at the greater tubercle (■ Fig. 3.9c).

The tape is rubbed in the elongated muscle position.

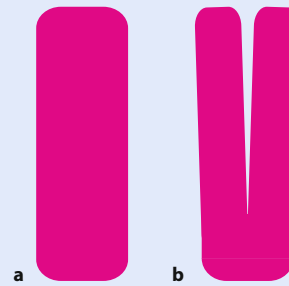
■ Fig. 3.9d shows the completed muscle application for the infrapinatus muscle.

■ Fig. 3.9e shows a Y-technique as a further variant. In this case it is important to anchor both tape tails simultaneously with skin displacement. In this example the patient is unable to fully achieve the inner rotation (IR) of the arm.

Memo

Application: Muscle technique

Cutting technique: I-tape or Y-tape



■ Fig. 3.10. a Red I-tape, b Red Y-tape

! Tip

The I-technique also affords the option of covering the trigger point.

With the Y-technique application, the base is affixed below the spine of the scapula and the inferior angle.

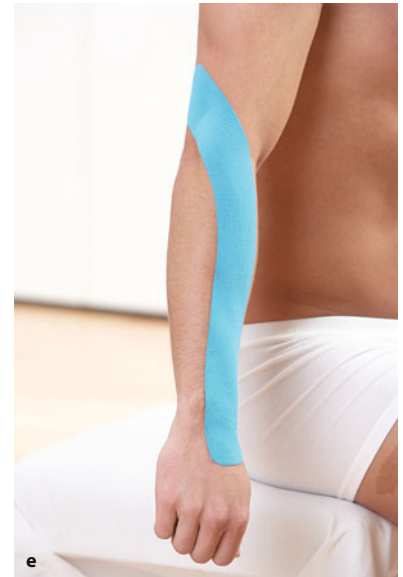
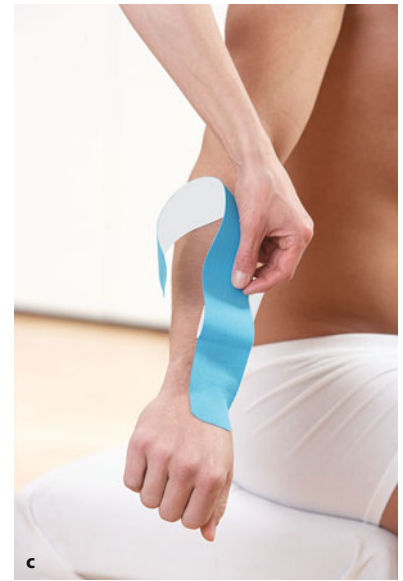
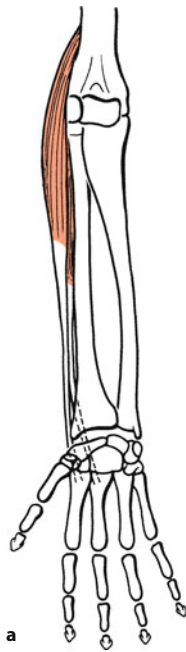

Fig. 3.11. **a** Extensor carpi radialis longus, **b** measure the tape in the elongated muscle position, **c** tonus-reducing application [blue]. Base on insertion, **d** apply the tape in the elongated muscle position, **e** completed application

3.1.6 Extensor carpi radialis longus muscle

Origin

Lateral supracondylar ridge of the humerus and lateral intermuscular septum, with a few fibers from the lateral epicondyle of the humerus

Insertion

Base of the 2nd metacarpal

Function

- Flexion of the elbow, weak pronator for bent arm, and supinator for extended arm.
- Responsible for dorsiflexion and radial abduction of hand (closed fist)

Innervation

Radial nerve (ramus profundus)

Application

This example illustrates a tonus-reducing muscle application of the extensor carpi radialis longus muscle.

The tape is measured from the area of the 2nd metacarpal on the back of the hand to the lateral supracondylar ridge of the humerus with palmar flexion and pronation of the hand (■ Fig. 3.11b).

The base is affixed at the insertion of the second metacarpal on the back of the hand in the resting position (■ Fig. 3.11c).

The muscle is elongated and the base anchored with skin displacement. The tape is then affixed with 10% stretch over the muscle belly to the origin of the lateral supracondylar ridge of the humerus (■ Fig. 3.11d).

The tape is rubbed in the elongated muscle position.

■ Fig. 3.11e shows the completed muscle application for the extensor carpi radialis longus muscle.

Memo

Application: Muscle technique

Cutting technique: I-tape



■ Fig. 3.12. Blue I-tape

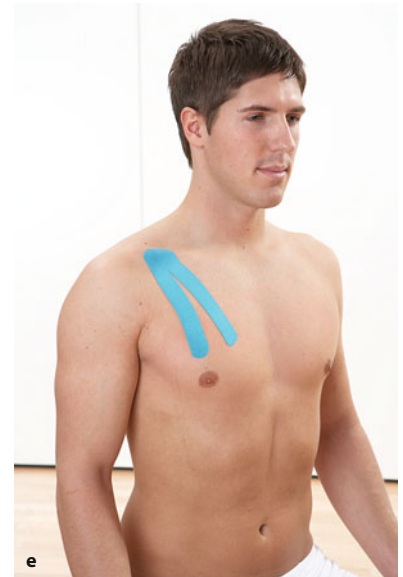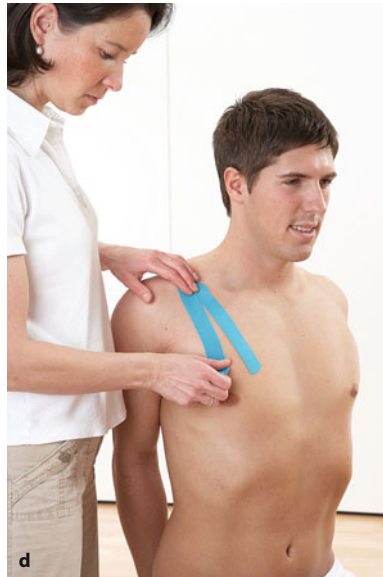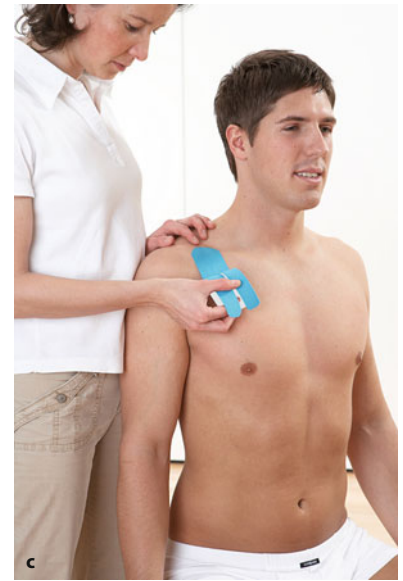


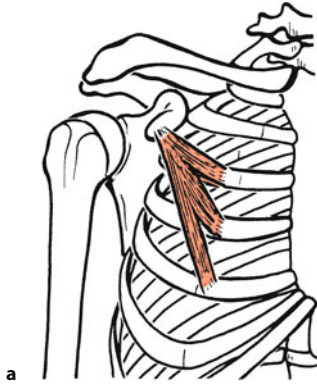Fig. 3.13. **a** Pectoralis minor muscle, **b** measure the tape in the elongated muscle position, **c** tonus-reducing application [blue]. Affix the base to the muscle insertion in the resting position, **d** strong dorsal skin displacement. Apply the tail strips with the muscle in the elongated position, **e** completed muscle application

3.2 Muscle applications for the trunk

- 3.2.1 Pectoralis minor
- 3.2.2 Pectoralis major
- 3.2.3 Rectus abdominis
- 3.2.4 Abdominal external oblique
- 3.2.5 Abdominal internal oblique
- 3.2.6 Iliacus
- 3.2.7 Intrinsic back muscles (erector spinae)

3.2.1 Pectoralis minor

Origin

Tendonous from the bones of the 2nd – 5th ribs near the cartilage-bone border

Insertion

Apex of the coracoid process

Function

Lowering the pectoral girdle, elevating the ribs during inspiration, rarely functions alone (mainly with serratus anterior and trapezius muscles)

Innervation

Medial and lateral pectoralis nerves (infraclavicular brachial plexus)

Application

This example illustrates a tonus-reducing muscle application to the pectoralis minor.

The tape is measured from the 5th rib to the coracoid process with the trunk in the maximum upright position (■ Fig. 3.13b).

The base is affixed to the insertion at the rib in the resting position (■ Fig. 3.13c).

The muscle is elongated and the base anchored with strong dorsal skin displacement. The tape is then affixed with 10% stretch over the muscle belly to the origin of the coracoid process (■ Fig. 3.13d).

The tape is rubbed with the muscle in the elongated position.

■ Fig. 3.11e shows the completed muscle application for the pectoralis minor.

Memo

Application: Muscle technique

Cutting technique: Y-tape



■ Fig. 3.14. Blue Y-tape

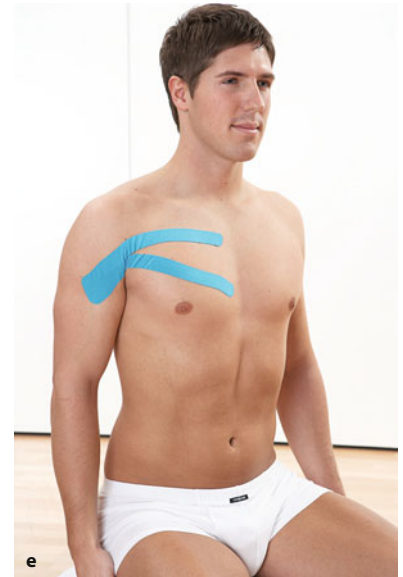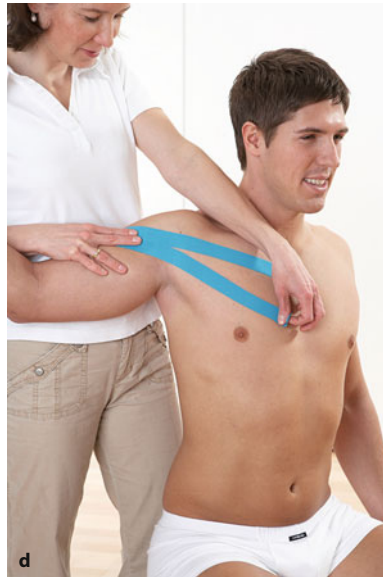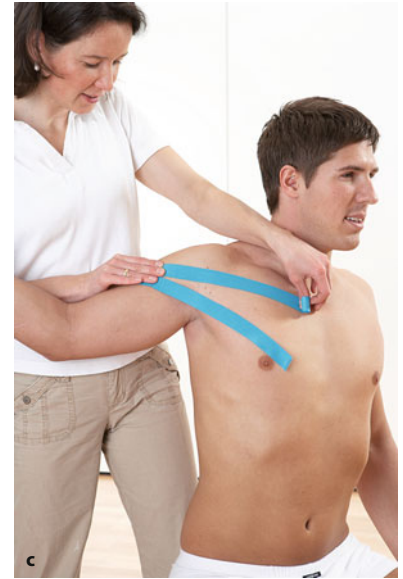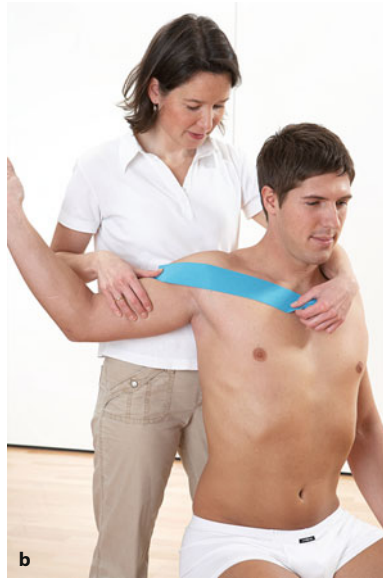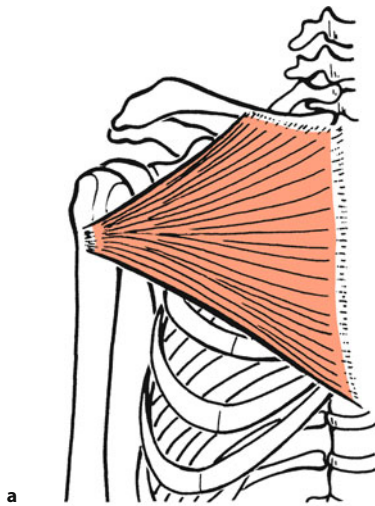


Fig. 3.15. **a** Pectoralis major muscle, **b** measure the tape in the elongated muscle position, **c** tonus-reducing application [blue]. Fix the base and attach the first tape tail in the elongated muscle position, **d** apply the second tape tail, **e** completed muscle application in resting position

3.2.2 Pectoralis major

Origin

- Clavicular head: sternal half of the clavicle
- Sternocostal head: ventral surface of the manubrium and body of the sternum, cartilages of 2nd – 6th ribs
- Abdominal head: Tendonous from abdominal aponeurosis (sheath of rectus abdominis muscle)

Insertion

Intertubercular groove of the humerus, fibers converge to a broad, flat tendon which is inserted into the crest of the greater tubercle of the humerus (the fibers of the clavicular head are inserted distally, those of the abdominal head proximally).

Function

Strong adduction; inner rotation of arm towards the ventral surface of the body.

Innervation

Medial and lateral nerves (infraclavicular brachial plexus)

Application

This example illustrates a tonus-reducing muscle application to the pectoralis major.

The tape is measured from the insertion at the crest of the greater tubercle of the humerus to the sternum with adduction and external rotation (ER) of the arm (■ Fig. 3.15b).

The base is affixed to the insertion in the resting position (■ Fig. 3.15c).

The clavicular head and sternocostal head of the pectoralis major are elongated and the base anchored with skin displacement. The tape is then affixed with 10% stretch over the muscle to the origin at the sternum (■ Fig. 3.15d).

The tape is rubbed with the muscle in the elongated position.

■ Fig. 3.15e shows the completed muscle application for the pectoralis major.

Memo

Application: Muscle technique

Cutting technique: Y-tape



■ Fig. 3.16. Blue Y-tape



Tip

Tape is only ever applied to the affected part!
Apply the base with the muscle lightly elongated so that the crossing over of the muscle fibers at the insertion can be seen more clearly.

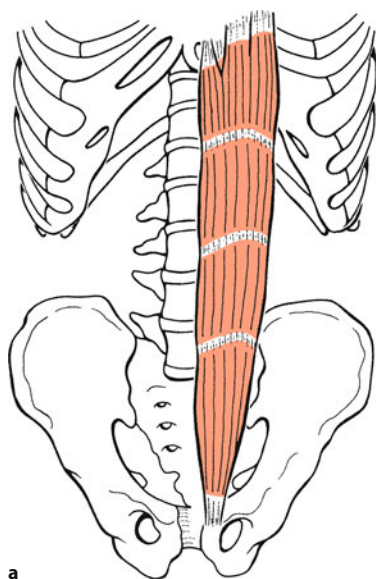
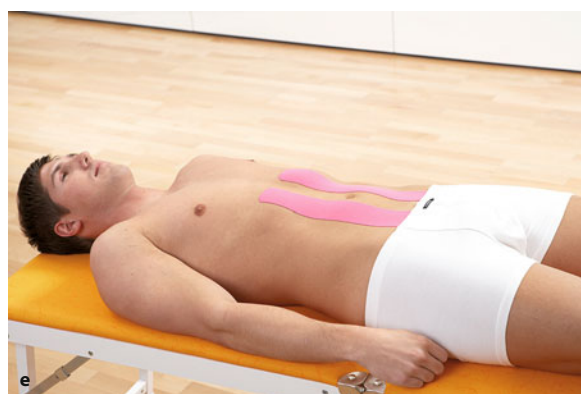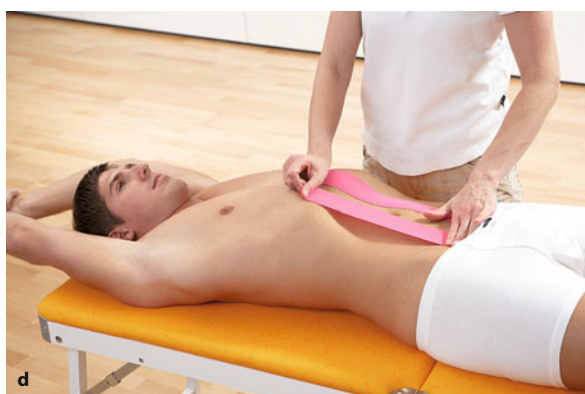

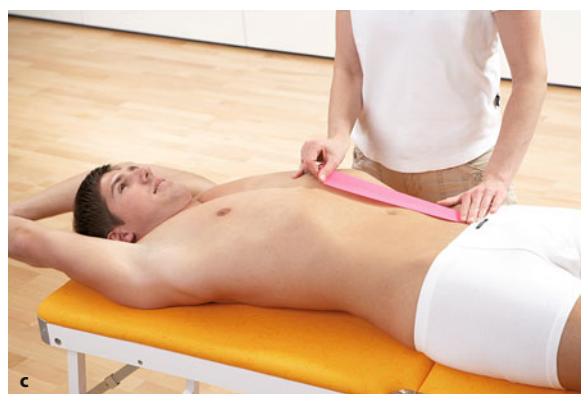
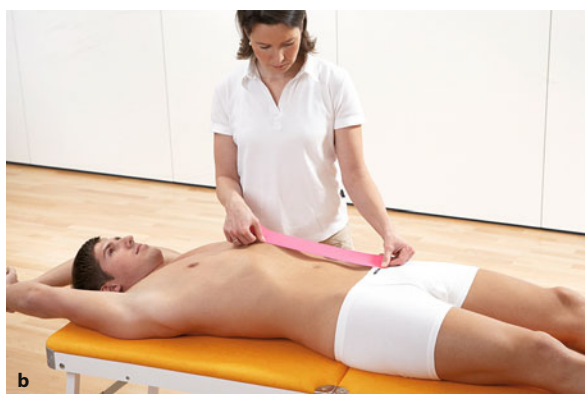Fig. 3.17. **a** Rectus abdominis muscle, **b** measure the tape in the elongated muscle position, **c** tonus-increasing application [red]. Fix the base and apply the first tape strip to the elongated muscle, **d** apply the second tape strip, **e** completed muscle application in resting position



3.2.3 Rectus abdominis

Origin

Cartilages of 5th, 6th, and 7th ribs, xiphoid process, and the ligaments between the xiphoid process and the ribs.

Insertion

Pubic crest

Function

- Distal origin: draws the sternum towards the pubis, most effective flexor for bending the trunk forwards.
- Proximal origin: draws the pubic bone towards the sternum while tilting the pelvis backwards.

Innervation

Intercostal nerves (T5-T12).

Application

This example illustrates a tonus-increasing muscle application to the rectus abdominis. The base lies on the distal origin with the muscle function of drawing the sternum towards the pubis.

The tape is measured from the origin at the crest of the pubis to the xiphoid process with trunk extension and flexion of the arm (■ Fig. 3.17b).

The base is affixed to the origin in the resting position (■ Fig. 3.17c).

The muscle is elongated and the base anchored with skin displacement. The tapes are then affixed with 10% stretch over the left (■ Fig. 3.17c) and right (■ Fig. 3.17d) parts of the muscle up to the insertion at the ribs.

The tape is rubbed with the muscle in the elongated position

■ Fig. 3.15e shows the completed muscle application for the rectus abdominis.

Important

The muscle is subject to constant change from the **punctum fixum** (fixed end) and **punctum mobile** (mobile end). Experience has shown that for a tonus-increasing application, the tape should be applied from the pubic crest to the ribs, contrary to the **insertion-origin rule** (► Chap. 2.1). Der Muskel unterliegt einem ständigen Wechsel von **Punktum fixum** und **Punktum mobile**. Here, the base is therefore affixed to the pubic crest and then applied upwards towards the ribs.

! Tip

Based on experience: The tape is applied from the pubis to the ribs and is thus a tonus-increasing application.

Memo

Application: Muscle technique

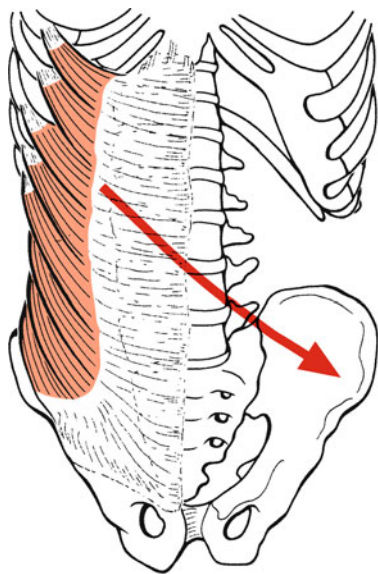
Cutting technique: I-tape



■ Fig. 3.18. Red I-tape

! Tip

If the patient's abdomen sags, as depicted (■ Fig. 3.17c), he or she should be asked to push it out to preclude excessive tension in the tape

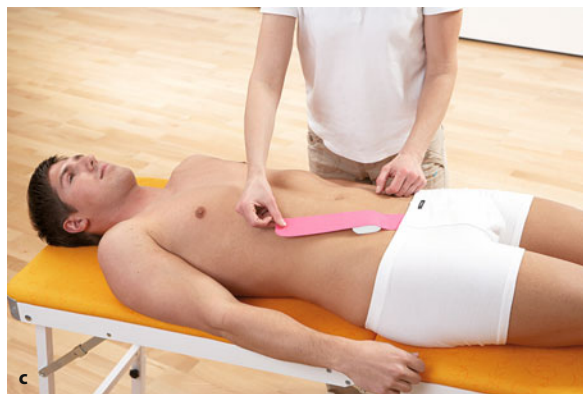


a

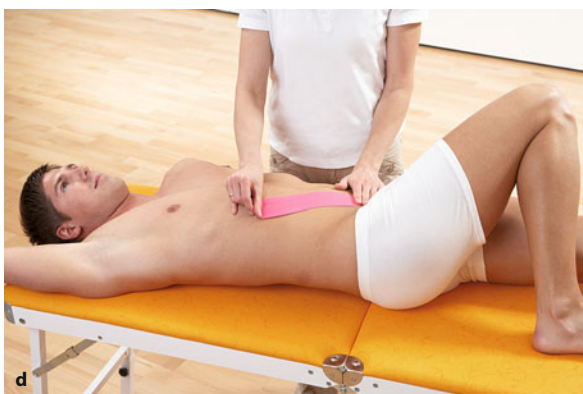
Fig. 3.19. **a** External oblique abdominal muscle, **b** tonus-increasing application [red]. Measure the tape in the elongated muscle position, **c** affix the base in the resting position, **d** fix the base and apply the tape strip to the elongated muscle, **e** completed muscle application in resting position



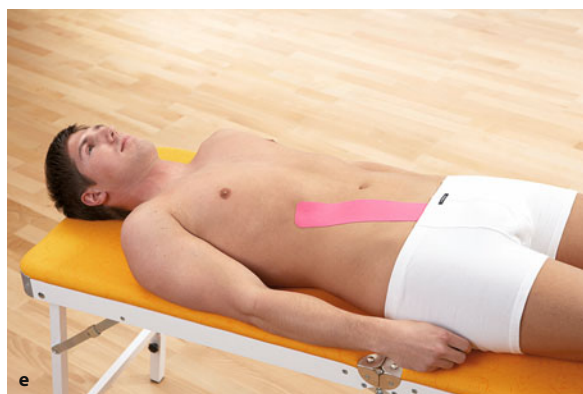
b



c



d



e

3.2.4 External oblique

Origin

Arises from eight fleshy digitations, each originating from the external surfaces and inferior borders of the 5th to 12th ribs.

Insertion

Iliac crest, inguinal ligament; caudally and ventrally the fibers terminate in the aponeurosis.

The aponeuroses from either side merge on the anterior side of the linea alba.

Function

- **Proximal origin:**
Pelvic extension and flexion of the lumbar vertebrae (LV)
- **Distal origin:**
Unilaterally: bends the vertebral column to the same side and rotates to the opposite side
Bilaterally: trunk flexor, lowers ribs during exhalation

Innervation

Intercostal nerves (T5-T12)

Application

This example illustrates a tonus-increasing muscle application to the external oblique abdominal muscle; the origin lies distally.

The tape is measured from the origin at the iliac crest and the inguinal ligament to the 5th to 12th ribs with flexion of the right arm and flexion of the hip and knee of the right leg with hip adduction (■ Fig. 3.19a).

The base is affixed to the insertion in the resting position (■ Fig. 3.19b).

The muscle is elongated and the base anchored with skin displacement. The tape is then applied with 10% stretch

over the right part of the muscle to the insertion at the ribs (■ Fig. 3.19c).

The tape is rubbed with the muscle in the elongated position.

■ Fig. 3.19d shows the completed muscle application for the external oblique abdominal muscle.

Important

Here, too, the muscle is subject to constant change from the **punctum fixum** (fixed end) and **punctum mobile** (mobile end). Experience has shown that for a tonus-increasing application, the tape should be applied from the iliac crest/inguinal ligament to the ribs, i.e. contrary to the **origin-insertion rule** (► Chap. 2.1). The base is therefore affixed between the iliac crest and the inguinal ligament and then applied towards the ribs.

Memo

Application: Muscle technique

Cutting technique: I-tape



■ Fig. 3.20. Red I-tape

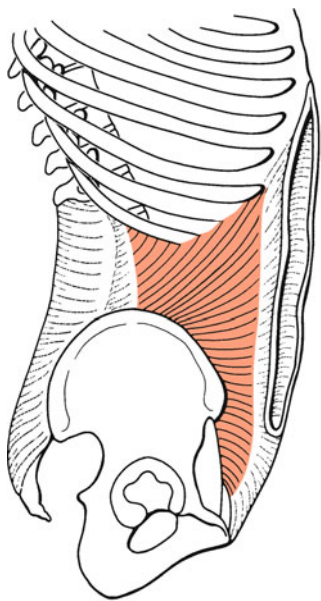
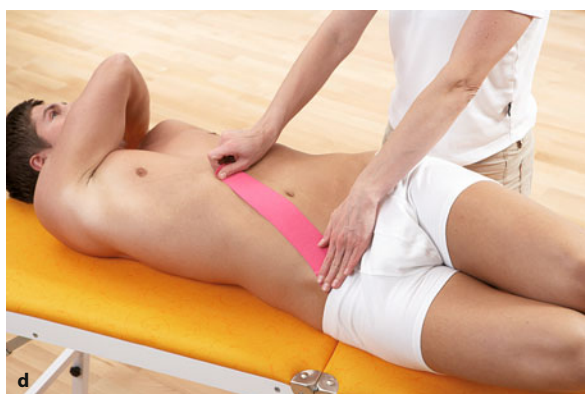
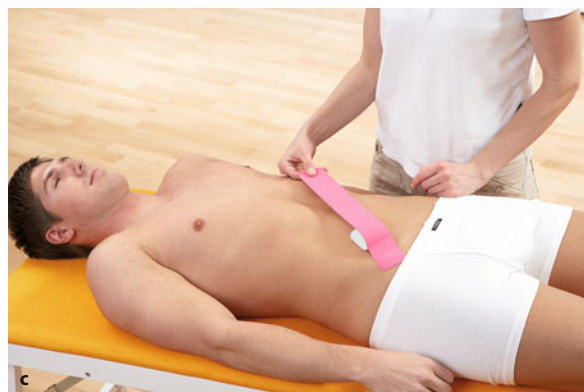
Fig. 3.21. **a** Internal oblique abdominal muscle, **b** tonus-increasing application [red]. Measure the tape in the elongated muscle position, **c** affix the base in the resting position, **d** anchor the base and apply the tape strip to the elongated muscle, **e** completed muscle application in resting position



3.2.5 Internal oblique

Origin

Arises from inguinal ligament, iliac crest, and the thoracolumbar fascia.

Insertion

Fan-shaped at 8th-12th ribs with aponeurosis at rib cartilages, at the sternum, and below at the pubis. Anteriorly, the ligament fibers insert into the linea alba on the opposite side.

Function

- Proximal origin:
Pelvic extension and continues as flexor of the lumbar vertebrae
- Distal origin:
Unilateral: bends trunk and rotates to the same side
Bilateral: trunk flexor, lowers the ribs during exhalation

Innervation

Intercostal nerves (T10-T12) and L1

Application

This example illustrates a tonus-increasing muscle application to the internal oblique abdominal muscle; the origin lies distally.

The tape is measured from the origin at the iliac crest to the 8th to 12th ribs, with both legs bent and turned to the right (■ Fig. 3.21b).

The base is affixed to the origin in the resting position (■ Fig. 3.21c).

The muscle is elongated and the base anchored with skin displacement. The tape is then affixed with 10% stretch over the muscle on the right up to the point of insertion at the ribs (■ Fig. 3.21d).

The tape is rubbed with the muscle in the elongated position.

■ Fig. 3.21e shows the completed muscle application for the internal oblique abdominal muscle.

Memo

Application: Muscle technique

Cutting technique: I-tape



■ Fig. 3.22. Red I-tape

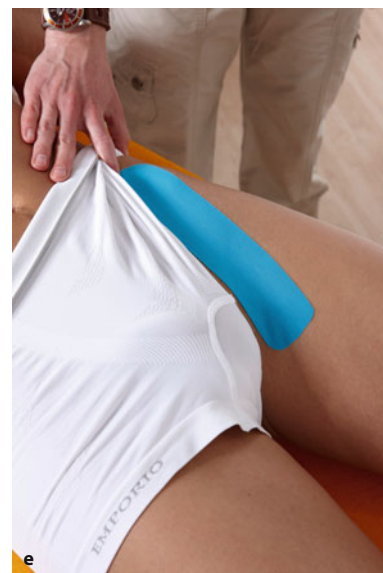
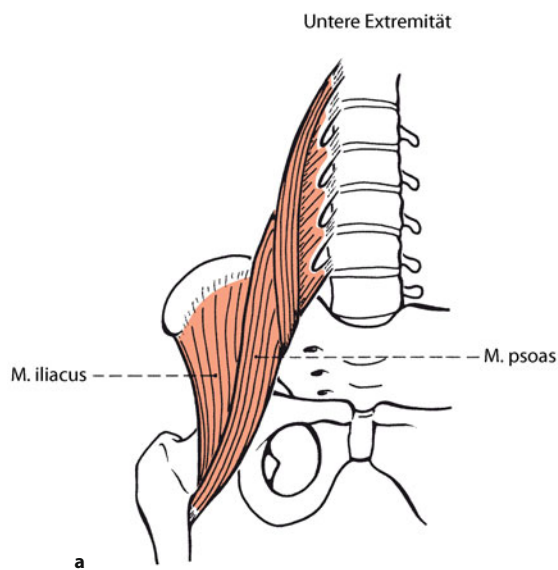


Fig. 3.23. a Iliacus muscle, b tonus-decreasing application [blue]. Measure the tape in the elongated muscle position, c affix the base in

the resting position, d anchor the base and apply the tape strip to the elongated muscle, e completed muscle application in resting position

3.2.6 Iliacus

Origin

- Iliac fossa,
- Anterior inferior iliac spine,
- Anterior capsule of hip joint.

Insertion

Lesser trochanter, adjacent to medial lip of the linea aspera

Function

- Origin **ilium**: powerful flexion in the hip joint; involvement in adduction and external rotation
- Origin **femur**: attempts forward tilting of pelvis on both sides simultaneously

Innervation

Muscular branches (rami musculares) of the lumbar plexus

Application

This example illustrates a tonus-decreasing muscle application to the iliacus. The origin in this example is at the ilium.

The tape is measured from the insertion at the lesser trochanter to the anterior inferior iliac spine, with hip extension, abduction, and internal rotation (■ Fig. 3.23b).

The base is affixed to the insertion in the resting position (■ Fig. 3.23c).

The muscle is elongated and the base anchored with skin displacement. The tape is then affixed with 10% stretch over the muscle up to the origin at the anterior inferior iliac spine (■ Fig. 3.23d).

The tape is rubbed with the muscle in the elongated position.

■ Fig. 3.23e shows the completed muscle application for the iliacus.

Memo

Application: Muscle technique

Cutting technique: I-tape



■ Fig. 3.24. Blue I-tape

! Tip

To pre-stretch the leg to be treated, allow it to hang down from the side of the treatment table.

The untreated leg is bent at the knee with the foot flat on the table.

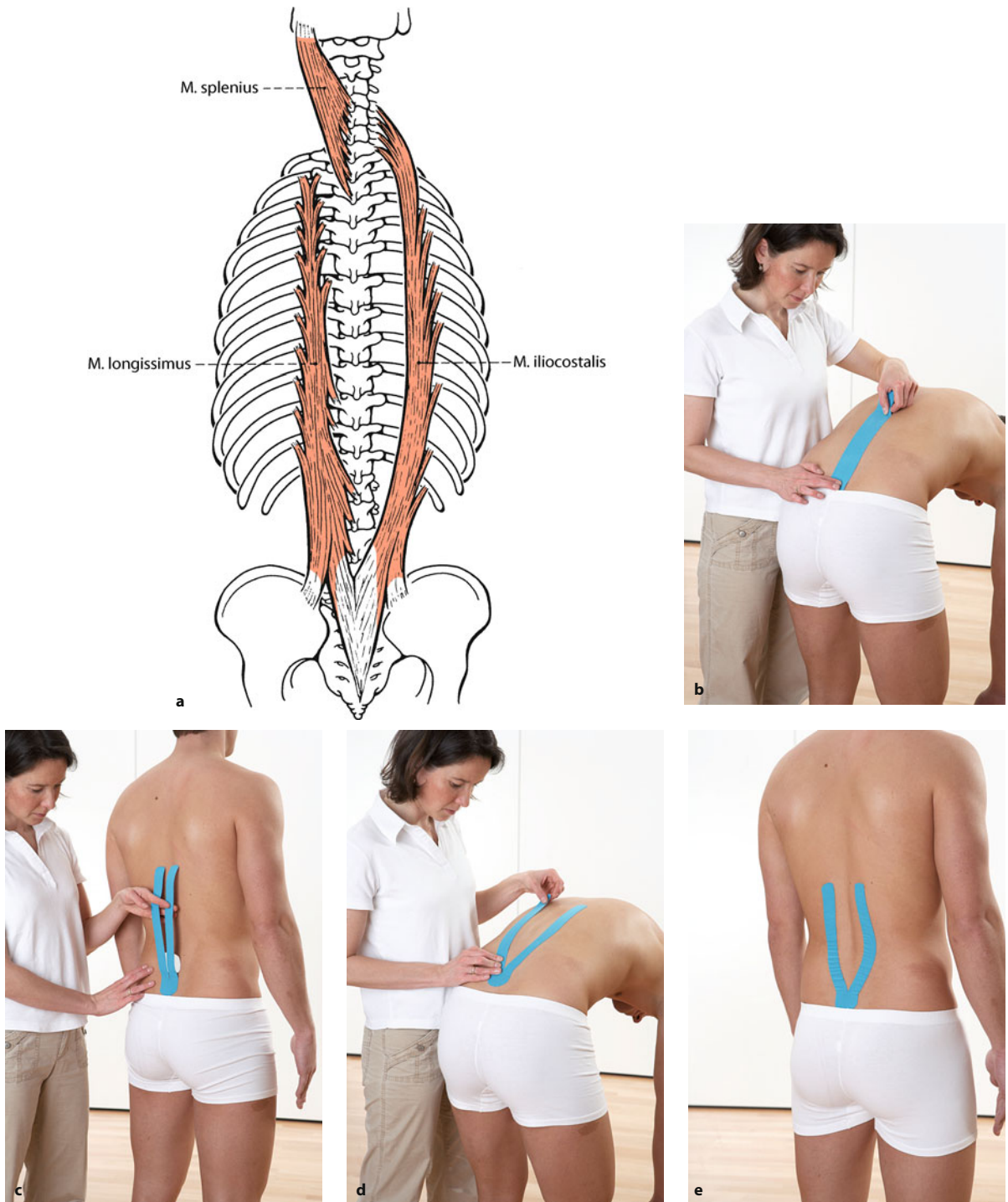

Fig. 3.25. **a** Erector spinae, **b** tonus-reducing muscle application [blue]. Measure the tape in the elongated muscle position, **c** affix the

base in the resting position, **d** anchor the base and apply the second tail strip to the elongated muscle, **e** completed muscle application

3.2.7 Intrinsic back musculature (erector spinae), application for the lumbar region

Origin/Insertion

- **Lateral superficial tract:** runs from the pelvis to the skull, long muscle bundles, divided into intertransversal and spinatransversal muscles
- **Medial deep tract:**
 - Straight system: interspinal and intertransversal
 - Oblique system: transversospinal

Function

Extension of the trunk

Innervation:

Dorsal rami of the spinal nerves

Application

This example illustrates a tonus-reducing muscle application to the lumbar region.

The tape is measured from the sacrum to the 12th thoracic vertebra with forward flexion of the trunk (■ Fig. 3.25b).

The base is affixed to the insertion in the resting position (■ Fig. 3.25c).

The muscle is elongated and the base anchored with skin displacement. The tape is then affixed with 10% stretch paravertebrally over the muscle bundles up to T12 (■ Fig. 3.25d).

The tape is rubbed with the muscle in the elongated state.

■ Fig. 3.25e shows the completed muscle application for the intrinsic back muscles.

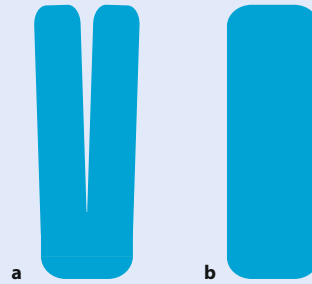
Important

The different directional courses and lengths of the muscle bundles give rise to **muscle interactions**. Experience has shown that for a tonus-reducing application in the lumbar region, the base should be affixed to the sacrum and the Y-tape tails affixed paravertebrally up to the thoracic vertebrae. This rule is valid for the entire **intrinsic back musculature**. The base is always positioned below and then affixed in an upward direction.

Memo

Application: Muscle technique

Cutting technique: Y-tape or 2 I-tapes paravertebrally



■ Fig. 3.26. a Blue Y-tape, b Blue I-tape

! Tip

Each individual section of the cervical, thoracic, and lumbar spine can be taped separately or in combination with the other spinal sections to tone or support muscles.

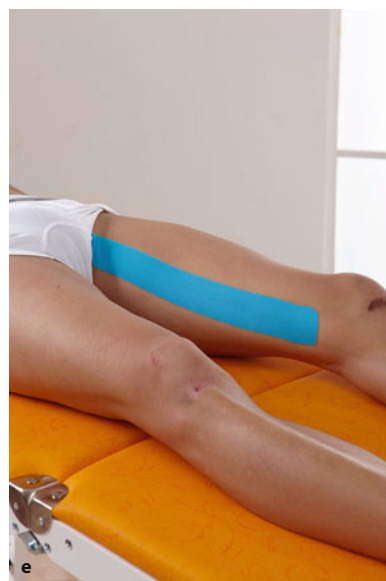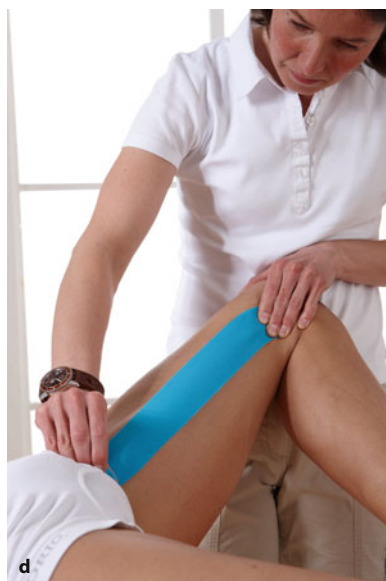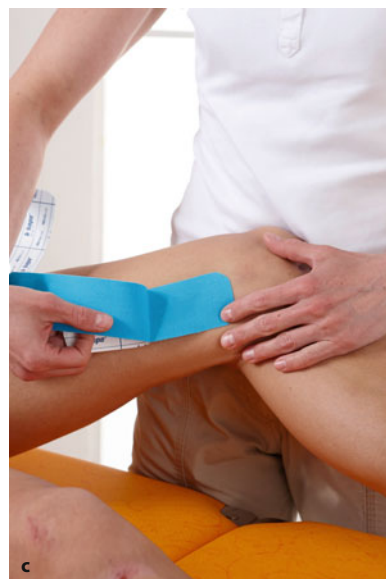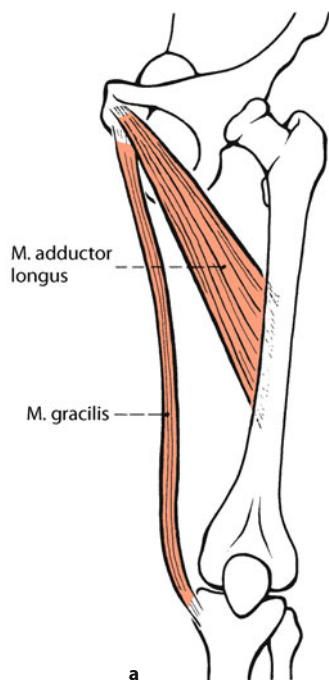


Fig. 3.27. **a** Adductor longus muscle, **b** tonus-reducing application [blue]. Measure the tape in the elongated muscle position, **c** affix the base in the resting position. At the same time, the therapist supports the patient's leg, **d** anchor the base and apply the tape strip to the elongated muscle, **e** completed muscle application

3.3 Muscle application for the lower extremities

- 3.3.1 Adductor longus
- 3.3.2 Rectus femoris
- 3.3.3 Biceps femoris
- 3.3.4 Semimembranosus
- 3.3.5 Gluteus maximus
- 3.3.6 Tibialis anterior
- 3.3.7 Extensor hallucis longus

3.3.1 Adductor longus

Origin

Superior ramus of the pubis

Insertion

Middle third of the medial lip of the linea aspera, distally the fibers extend to the adductor canal.

Function

Adduction, external rotation, and minimal anteversion of the hip

Innervation

Anterior ramus of obturator nerve (L2-L4)

Application

This example illustrates a tonus-reducing muscle application to the adductor longus.

The tape is measured from insertion of the femoral condyle to the superior ramus of the pubis with hip adduction and knee flexion (■ Fig. 3.27b).

The base is affixed to the insertion in the resting position (■ Fig. 3.27c).

The muscle is elongated and the base anchored with skin displacement. The tape is then affixed with 10% stretch over the muscle belly up to the superior ramus of the pubis (■ Fig. 3.27d).

The tape is rubbed with the muscle in the elongated position.

■ Fig. 3.27e shows the completed muscle application for the adductor longus.

Memo

Application: Muscle technique

Cutting technique: I-tape



■ Fig. 3.28. Blue I-tape

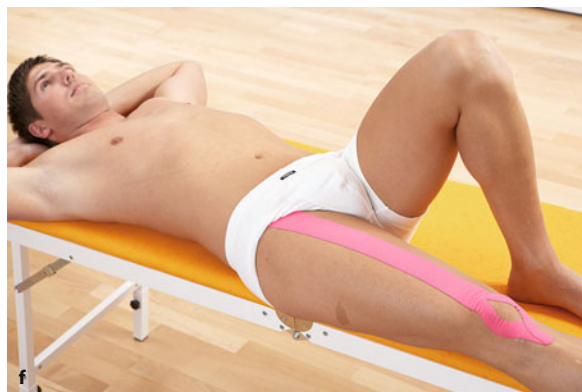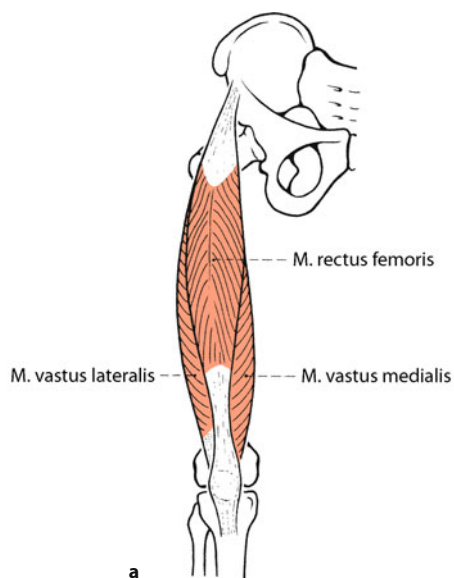


Fig. 3.29. **a** Rectus femoris muscle, **b** tonus-increasing application [red]. Measure the tape in the elongated muscle position, **c** affix the base to the origin in the resting position, **d** anchor the base and affix the I-tape up to one finger width above the patella. **e** affix the tape

tails round the patella up to the tibial tuberosity. The unstretched tape tail ends are affixed one over the other, **f** completed muscle application in resting position

3.3.2 Rectus femoris

Origin

- Anterior head: anterior inferior iliac spine
- Posterior head: cranial margin of the acetabulum

Insertion

Over the patella (a sesamoid bone), it joins with the patellar ligament the patellar retinacula to insert into the tibial tuberosity

Function

Extension of the knee, flexion of the hip

Innervation

Femoral nerve (lumbar plexus)

Application

This example illustrates a tonus-increasing muscle application to the rectus femoris.

The tape is measured from the origin of the anterior inferior iliac spine to the tibial tuberosity with maximum hip and knee flexion (■ Fig. 3.29b).

The base is affixed to the origin in the resting position (■ Fig. 3.29c).

The muscle is elongated and the base anchored with skin displacement. The tape is affixed with 10% stretch over the muscle belly up to a finger width above the patella; the cut tape is then affixed around the patella to the insertion at the tibial tuberosity. The unstretched tape tails are affixed one over the other (■ Fig. 3.29d).


The tape is rubbed with the muscle in the elongated position.

■ Fig. 3.29e shows the completed muscle application for the rectus femoris.

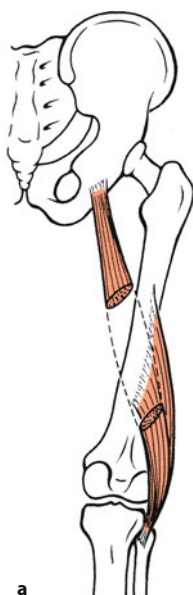
Memo

Application: Muscle technique

Cutting technique: I-tape changing to Y-tape



■ Fig. 3.30. Red Y/I combination tape



a



b



c



d



e

Fig. 3.31. **a** Biceps femoris muscle, **b** tonus-increasing application [red]. Measure the tape in the elongated muscle position with the patient bending over forwards, **c** affix the base to the origin in the resting position with the patient upright, **d** anchor the base and apply the tape strip to the elongated muscle, **e** completed muscle application in resting position

3.3.3 Biceps femoris

Origin

- Long head: ischial tuberosity
- Short head: middle third of the linea aspera

Insertion

Head of the fibula

Function

Hip retroversion, knee flexion with external rotation of lower leg

Innervation

Long head: tibial nerve. Short head: common peroneal nerve

Application

This example illustrates a toning-muscle application to the biceps femoris.

The tape is measured from the origin of the ischial tuberosity to the head of the fibula with maximum hip flexion and knee extension (■ Fig. 3.31b).

The base is affixed to the origin in the resting position (■ Fig. 3.31c).

The muscle is elongated and the base anchored with skin displacement. The tape is then affixed with 10% stretch over the muscle belly up to the insertion of the head of the fibula (■ Fig. 3.31d).

The tape is rubbed with the muscle in the elongated position.

■ Fig. 3.31e shows the completed muscle application for the biceps femoris.

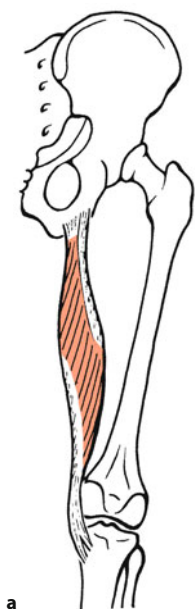
Memo

Application: Muscle technique

Cutting technique: I-tape



■ Fig. 3.32. Red I-tape



a



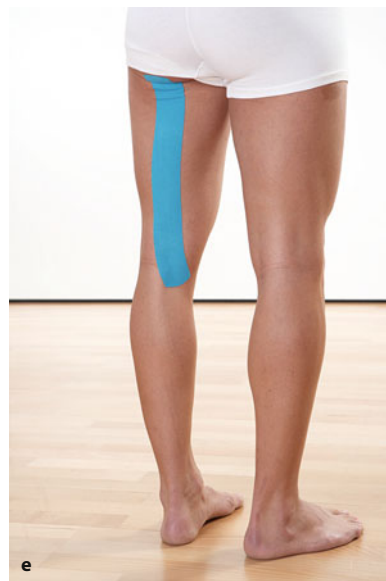b



c



d



e

Fig. 3.33. a Semimembranosus muscle, b tonus-reducing application [blue]. Measure the tape in the elongated muscle position, c affix the base to the insertion in the resting position, d anchor the base and apply the tape strip to the elongated muscle, e completed muscle application in resting position

3.3.4 Semimembranosus

Origin

Ischial tuberosity

Insertion

Semimembranosus: medial surface of the tibia, pes anserinus profundus

Function

Hip retroversion, knee flexion with inner rotation of the lower leg

Innervation

Tibial nerve

Application

This example illustrates a tonus-reducing application to the semimembranosus muscle.

The tape is measured from the insertion at the pes anserinus up to the ischial tuberosity with maximum hip flexion and knee extension (■ Fig. 3.33b).

The base is affixed to the insertion in the resting position (■ Fig. 3.33c).

The muscle is elongated and the base anchored with skin displacement. The tape is then affixed with 10% stretch over the muscle belly to the origin at the ischial tuberosity (■ Fig. 3.33d).

The tape is rubbed with the muscle in the elongated position.

■ Fig. 3.33e shows the completed muscle application for the semimembranosus.

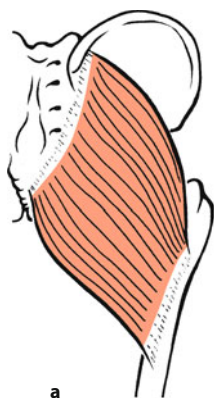
Memo

Application: Muscle technique

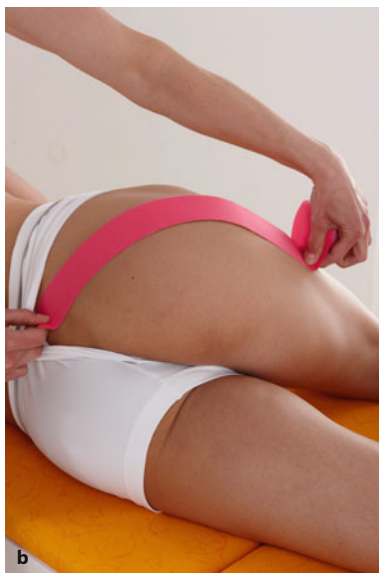
Cutting technique: I-tape



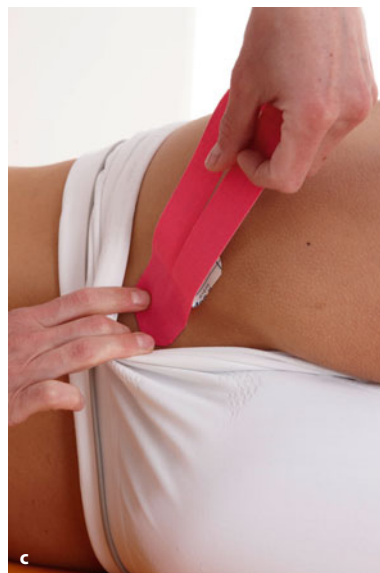
■ Fig. 3.34. Blue I-tape




a



b



c



d



e

Fig. 3.35. a Gluteus maximus muscle, b tonus-increasing application [red]. Measure the tape in the elongated muscle position and add a hand width of tape, c affix the base in the resting position, d anchor the base and apply the tape strip to the elongated muscle. The unstretched tape tail ends are affixed one over the other, e completed muscle application

3.3.5 Gluteus maximus

Origin

- **Superficial fibers:** iliac crest, posterior superior iliac spine, thoracolumbar fascia, dorsal surface of the sacrum,
- **Deep fibers:** dorsal wing of ilium (behind the posterior gluteal line), sacrotuberous ligament, and the fascia of the gluteus medius

Insertion

Proximal fibers in the iliotibial tract, distal fibers in the gluteal tuberosity

Function

Main extensor of hip joint; maintains erect position of the trunk, supports adduction (cranial fibers) and abduction (caudal fibers), is involved in external rotation, and tenses the iliotibial tract.

Innervation

Inferior gluteal nerve (sacral plexus)

Application

This example illustrates a tonus-increasing muscle application to the gluteus maximus.

The tape is measured from the origin at the sacrum to the insertion at the gluteal tuberosity (■ Fig. 3.35b) plus an additional hand width so that the entire muscle can be included.

The base is attached to the origin in the resting position (■ Fig. 3.35c).

The muscle is elongated and the base anchored with skin displacement. The tape is then affixed with 10% stretch over the muscle belly to the origin at the gluteal tuberosity; the unstretched tape tail ends are affixed one over the other (■ Fig. 3.35d).

The tape is rubbed with the muscle in the elongated position.

■ Fig. 3.35e shows the completed muscle application for the gluteus maximus.

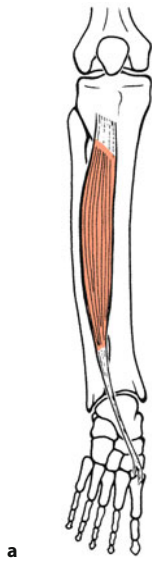
Memo

Application: Muscle technique

Cutting technique: Y-tape with long tape tails



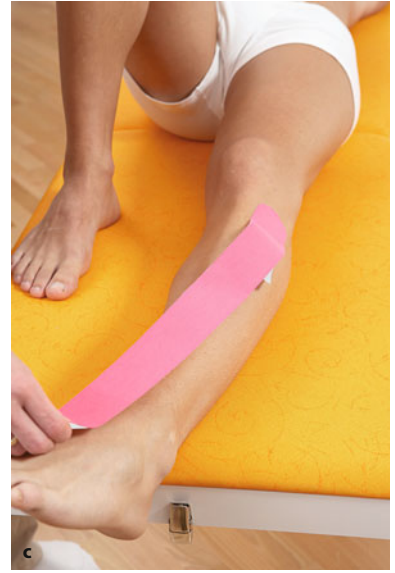
■ Fig. 3.36. Red Y-tape



a



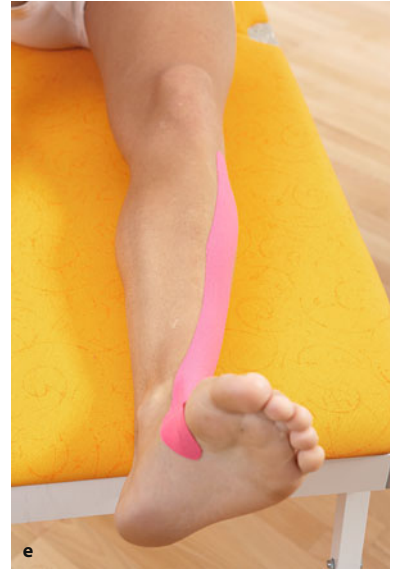
b



c



d



e

Fig. 3.37. a Tibialis anterior muscle, b tonus-increasing application [red]. Measure the tape in the elongated muscle position, c affix the base to the origin in the resting position, d anchor the base and apply the tape strip to the elongated muscle, e completed muscle application in the resting position

3.3.6 Tibialis anterior

Origin

Lateral condyle and lateral tibial fascia, interosseus membrane, crural fascia

Insertion

Medial cuneiform bone and first metatarsal

Function

- **Free leg - proximal origin:** dorsiflexion, supination (and adduction) of the foot
- **Supporting leg - distal origin:** brings the upper foot towards the shin

Innervation

Deep fibular (peroneal) nerve (L4-L5)

Application

This example illustrates a tonus-increasing muscle application to the tibialis anterior. Origin is proximal.

The tape is measured from the insertion at the cuneiform bone and first metatarsal up to the origin at the lateral epicondyle of the tibia with plantar flexion and pronation of the foot (■ Fig. 3.37b).

The base is affixed to the origin in the resting position (■ Fig. 3.37c).

The muscle is elongated and the base anchored with skin displacement. The tape is then affixed with 10% stretch over the muscle belly up to the insertion at the cuneiform bone and first metatarsal (■ Fig. 3.37d).

The tape is rubbed with the muscle in the elongated position.

■ Fig. 3.37e shows the completed muscle application for the tibialis anterior.

Memo

Application: Muscle technique

Cutting technique: I-tape



■ Fig. 3.38. Red I-tape

! Tip

Since the muscle is narrow, the tape can be cut so that it is also narrow, thereby improving comfort of wear.

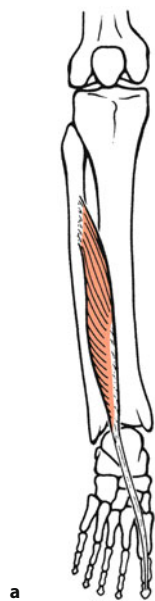


Fig. 3.39. **a** Extensor hallucis longus muscle, **b** tonus-increasing application [red]. Measure the tape in the elongated muscle position. Reduce the tape width to approximately 2/3, **c** affix the base to the origin in the resting position, **d** anchor the base and apply the tape strip to the elongated muscle, **e** completed muscle application in resting position



3.3.7 Extensor hallucis longus

Origin

Medial fibular fascia and the interosseus membrane

Insertion

Nail phalanx of big toe

Function

- **Free leg - proximal origin:** dorsal extension of the big toe and assists in dorsiflexion of the foot in the **free leg**; weak pronator and supinator of the foot.
- **Supporting leg - distal origin:** brings the upper foot towards the shin in the supporting leg

Innervation

Deep fibular (peroneal) nerve L4-S1

Application

This example illustrates a tonus-increasing muscle application to the extensor hallucis longus. The origin lies proximally.

The tape is measured from the insertion at the distal phalanx of the big toe up to the origin at the medial fibular fascia with plantar flexion of the foot and flexion of the big toe (■ Fig. 3.39b).

The base is affixed to the origin in the resting position (■ Fig. 3.39c).

The muscle is elongated and the base anchored with skin displacement. The tape is then affixed with 10% stretch

over the muscle belly to the insertion at the distal phalanx of the big toe (■ Fig. 3.39d).

The tape is rubbed with the muscle in the elongated position.

■ Fig. 3.39e shows the completed muscle application for the hallucis longus.

Memo

Application: Muscle technique

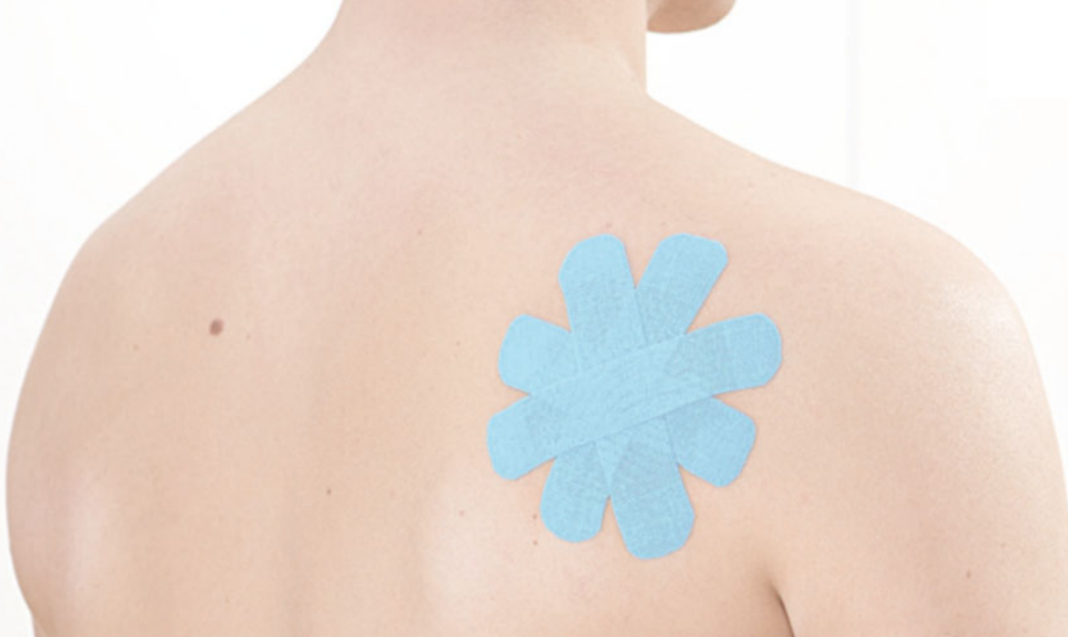Cutting technique: I-tape



■ Fig. 3.40. Red I-tape

! Tip

Since the muscle is thin and the tape application culminates on the big toe, the tape is cut so that it is 2/3 of the tape width.



4 Ligament Applications

4.1 Ligaments and tendons – 79

- 4.1.1 Collateral ligaments of the knee – 79
- 4.1.2 Patellar ligament – 81
- 4.1.3 Achilles tendon – 83
- 4.1.4 Lateral collateral ligaments of the ankle joint – 85

4.2 Special form of ligament application: spacetape – 87

- 4.2.1 Spacetape pain point – 87
- 4.2.2 Spacetape Trigger point – 89

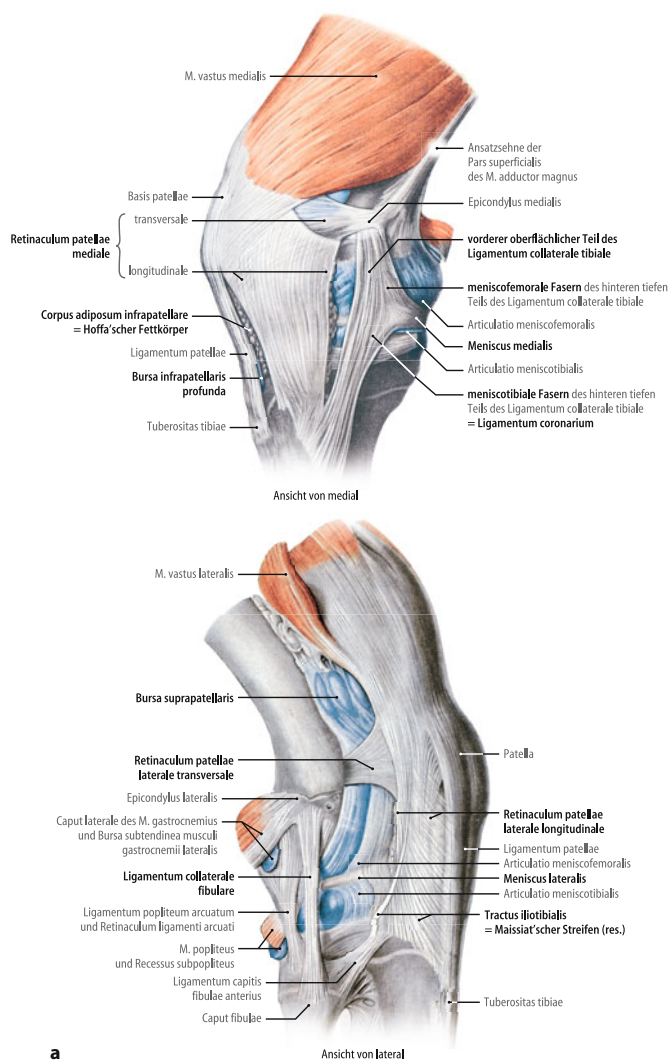
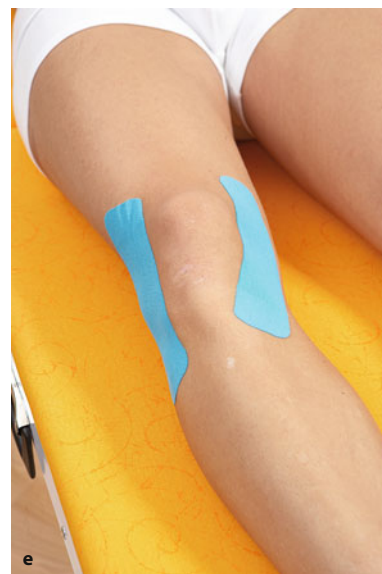
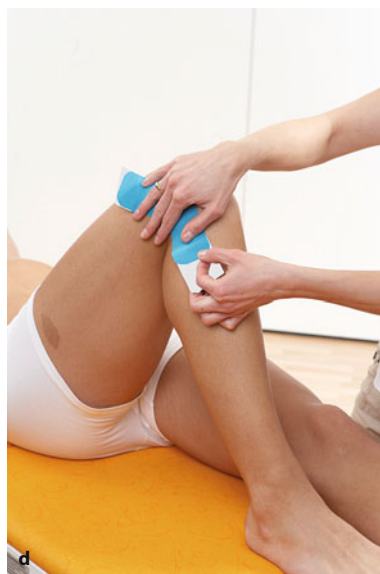
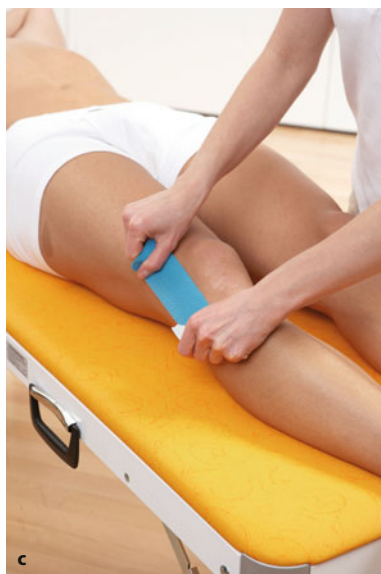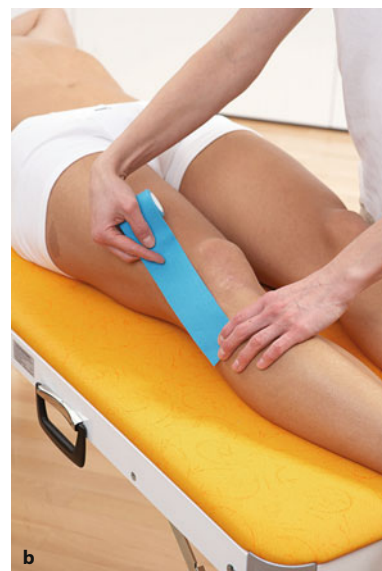Fig. 4.1. a-e. Collateral ligaments of the knee: **a** collateral ligaments of the knee, **b** measure the tape, knee in neutral position, **c** affix the tape in the neutral position. Stretch the tape to its maximum and affix en bloc, **d** position the knee with maximum flexion and anchor the affixed tape area with one hand, affix the tension-free ends, **e** completed bilateral application to the collateral ligaments



4.1 Ligaments and tendons

- 4.1.1 Collateral ligaments of the knee
- 4.1.2 Patella ligament
- 4.1.3 Achilles tendon
- 4.1.4 Lateral collateral ligament of the ankle-joint

4.1.1 Collateral ligaments of the knee

Course

Tibial (medial) collateral ligament: from the medial epicondyle of the femur to the medial condyle of the tibia.

The **medial ligament** is a triangular, flat band fused with the capsule and the medial meniscus. It is thicker than the **lateral ligament**.

Fibular (lateral) collateral ligament: from the lateral epicondyle to the head of the fibula.

The round lateral ligament has no attachment to the capsule or the lateral meniscus.

Function

The **collateral ligaments** (■ Fig. 4.1a) support and control the knee joint. They prevent lateral bending open of the knee as well as exterior rotation of the tibia. The collateral ligaments are extended during stretching and lateral rotation of the lower leg and relaxed during flexion and internal rotation.

Indications

Overloading and stretching of collateral ligaments

Application

The tape is measured from insertion to insertion for the tibial collateral ligament and fibular collateral ligament. The knee is placed in the neutral position (■ Fig. 4.1b).

The tape is affixed in the neutral position. Stretch the tape maximally, apply the stretched area en bloc, and rub the tape well (■ Fig. 4.1c).

Place the knee in the position of maximum flexion and anchor the affixed tape with one hand to prevent loosening of the tape. Remove both parts of the backing paper and affix the ends without tension (■ Fig. 4.1d).

The applications for the two ligaments are carried out successively. Measure the tape for the lateral ligament, then affix the stretched tape and anchor the ends with maximum flexion. Repeat this procedure for the medial side.

■ Fig. 4.1e show the completed bilateral taping application for the collateral ligaments.

Memo

Application: Ligament technique

Cutting technique: I-tape



■ Fig. 4.2. Blue I-tape



Tip

To prevent loosening of the tape, the therapist must anchor the tape during the entire flexion process, i.e., from the neutral position to maximum flexion.

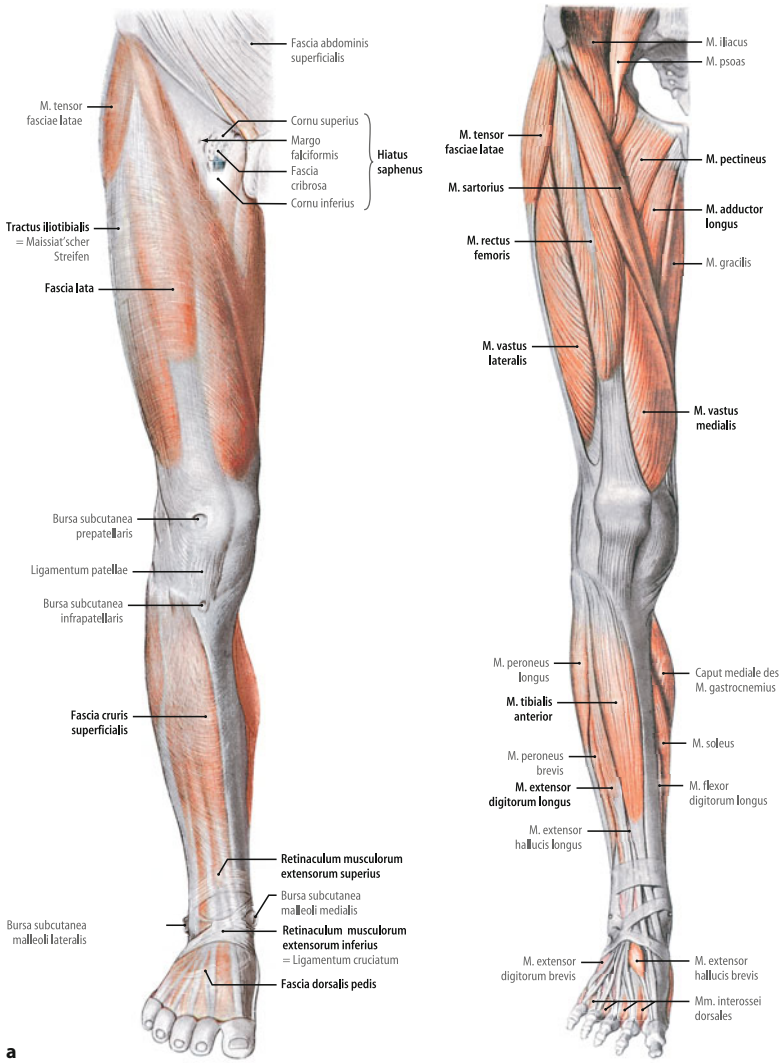
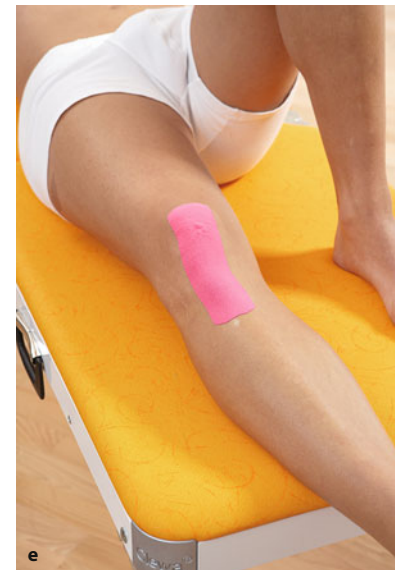
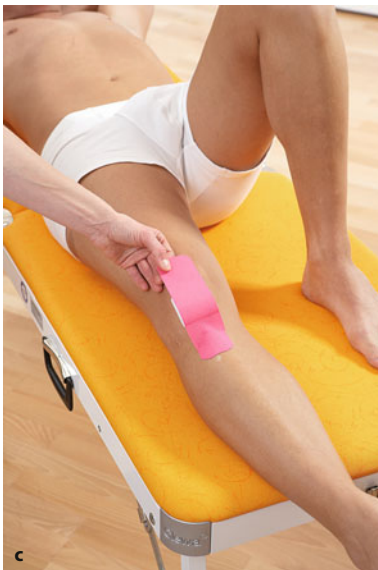

Fig. 4.3. a-e. Patellar ligament: **a** patellar ligament, **b** measure the tape with maximum knee flexion, **c** affix the base to the ligament insertion without tension, **d** knee in maximum flexion, anchor base with skin displacement, stretch tape to its maximum extent and affix up to the apex of the patella. Leave knee in maximum flexion and affix tape ends without flexion. Rub the tape with the knee flexed, **e** completed application in neutral position



4.1.2 Patellar ligament

Course

Patellar ligament: A continuation of the quadriceps tendon, it runs from the patella to the tibial tuberosity (■ Fig. 4.3a)

Function

Force transmission of anterior thigh musculature to the lower leg during extension and flexion of the knee.

Indications

Overloading and stretching of the **patellar ligament**; **patellar apex syndrome**

Application

The tape is measured from the tibial tuberosity to the upper margin of the patella with maximum knee flexion (■ Fig. 4.3b). The base is affixed to the ligament insertion without tension, then the knee is brought into a position of maximum flexion and the base anchored with skin displacement. The maximally stretched tape is affixed up to the apex of the patella (■ Fig. 4.3c).

Leave the knee in maximum flexion and affix the tape ends without tension. The completed tape application is rubbed with the knee flexed. (■ Fig. 4.3d).

■ Fig. 4.3e shows the completed application in the neutral position.

Memo

Application: Ligament technique

Cutting technique: I-tape



■ Fig. 4.4. Red I-tape

! Tip

Only stretch the tape up to the **apex of the patella** and not beyond this point, otherwise the tape will tilt the patella dorsally.

If the patient is unable to tolerate the tension-free tape end over the patella, it should be cut into a V-shape and affixed around the patella.

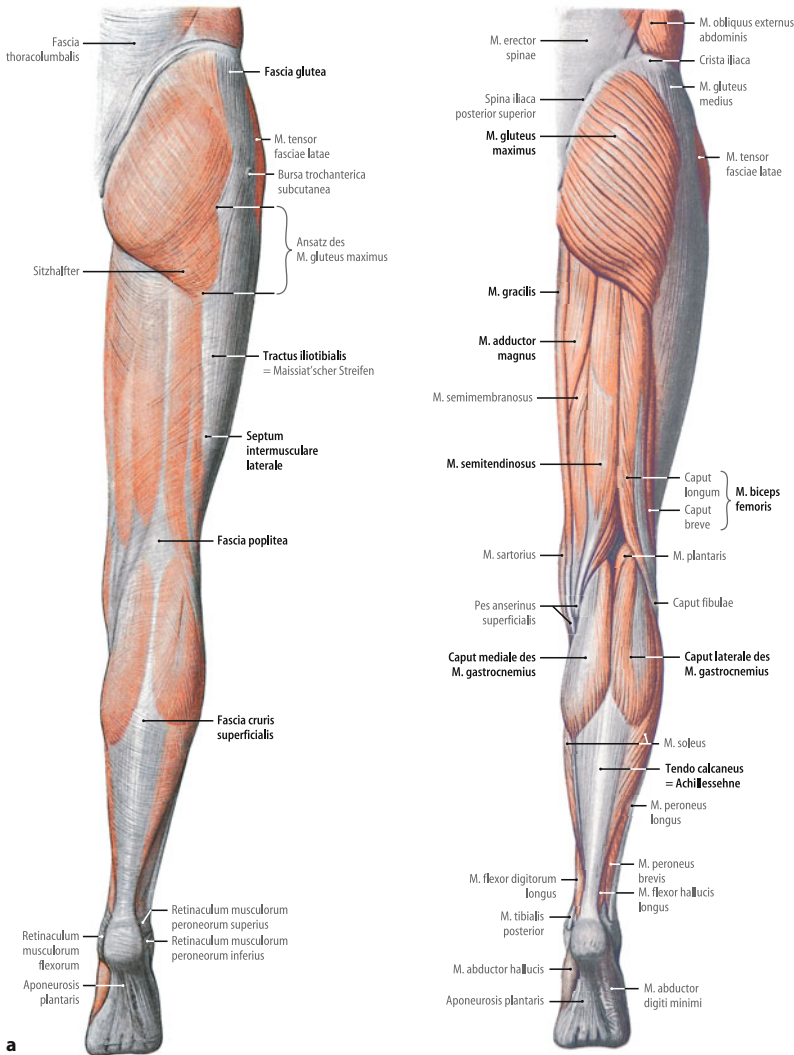
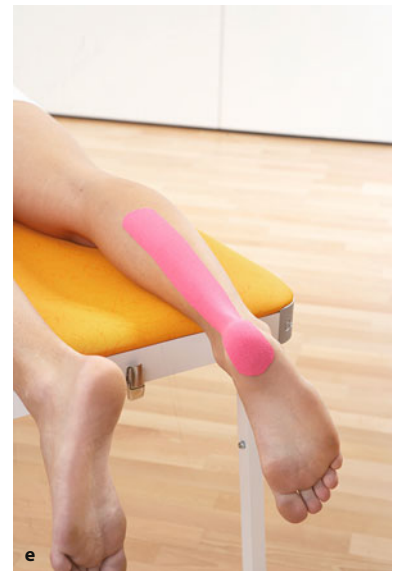
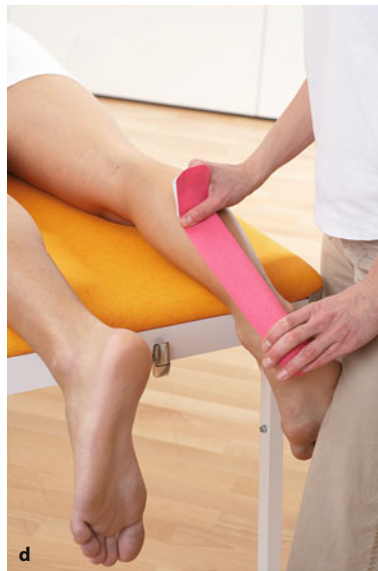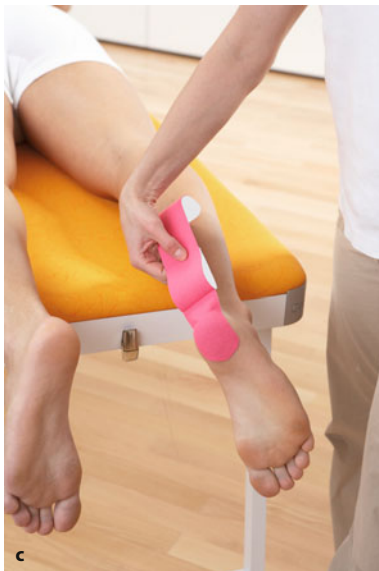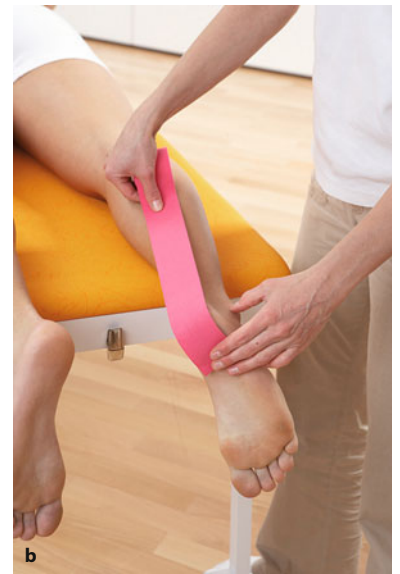


Fig. 4.5. a-e. Achilles tendon: **a** Achilles tendon, **b** measure the tape with the joint in the neutral position, **c** ankle joint in neutral position and affix the base to the sole of the foot without tension for better adhesion, **d** anchor the base, elongate the muscle, and affix the tape with maximum stretch over the tendon up to the muscle insertion. Affix tape ends without tension. **e** completed application in the resting position



4.1.3 Achilles tendon

Course

Calcaneal tendon (■ Fig. 4.5a): Tendonous extension of the soleus and gastrocnemius muscles, inserting into the posterior surface of the calcaneus bone below the bursa.

Function

- Transmission of force of the calf muscle to the ankle joint in plantar flexion
- Plantar flexion, flexion of the knee

Indications

Overloading and stretching of the achilles tendon, achillobursitis

Tape application

The tape is measured from the calcaneus bone on the sole of the foot up to the muscle-tendon junction with the gastrocnemius muscle; the patient is in the prone position with maximum dorsal extension of the foot (■ Fig. 4.5b).

Place the ankle in the neutral position and affix the base to the sole of the foot without tension to facilitate better adhesion (■ Fig. 4.5c).

Elongate the muscle and anchor the base, then affix the tape with maximum stretch over the tendon up to the muscle insertion.

Affix the tape ends without tension (■ Fig. 4.5d).

■ Fig. 4.5e shows the completed application in the resting position.

Memo

Application: Ligament technique

Cutting technique: I-tape



■ Fig. 4.6. Red I-tape

! Tip

Affix a Cross-Tape to the pain spot of the achilles tendon.

It makes sense to affix the spacetape (► Chap. 4.2.2) to the thoracolumbar junction, since this is the »reference area« for the autonomic nerve supply to the lower extremities.

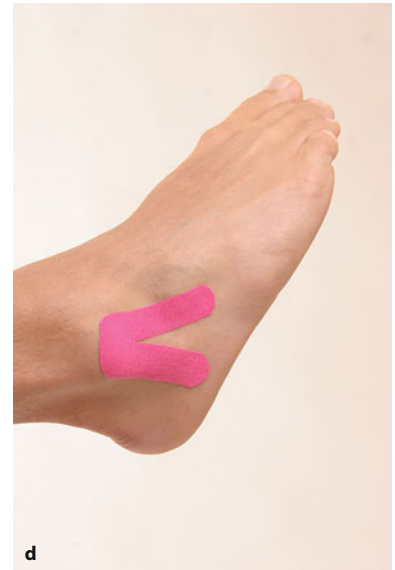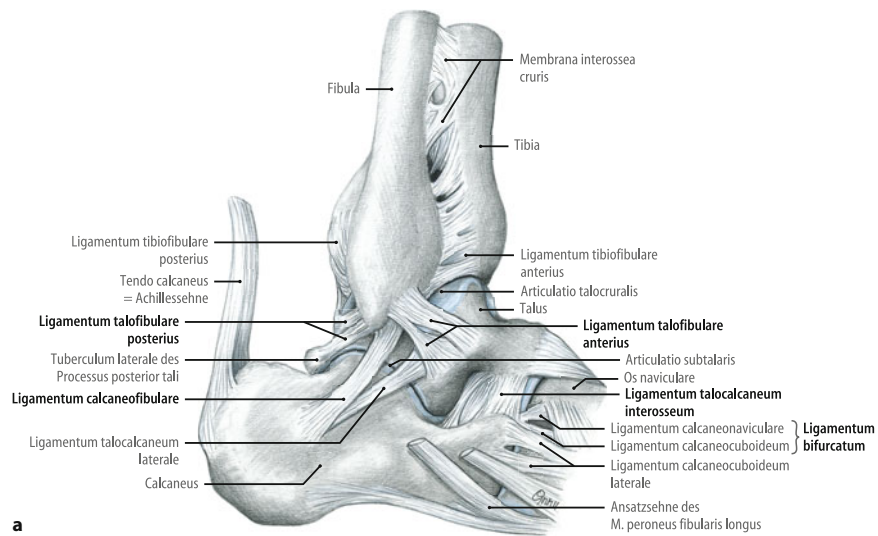


Fig. 4.7. a-d. Lateral collateral ligaments of the ankle joint: **a** Affix the tape strip maximally stretched along its entire length, **b** completed application with individual strip for anterior talofibular ligament,

c alternative: Y-technique for anterior talofibular and calcaneofibular ligaments.

4.1.4 Lateral collateral ligaments of the ankle joint

Course

Anterior talofibular ligament runs from the fibula to the talus (■ Fig. 4.7a)

Posterior talofibular ligament runs from the fibula to talus

Calcaneofibular ligament runs from the fibula to the calcaneus

Function

Support of plantar and dorsal flexion of the ankle joint

Indications

Overloading and stretching of the lateral collateral ligaments

Application

The tape strip is affixed maximally stretched over its entire length (■ Fig. 4.7b).

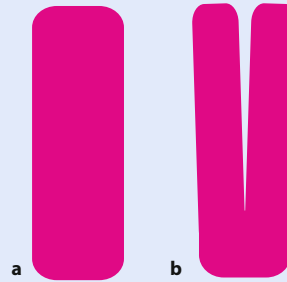
■ Fig. 4.7c shows the completed application with individual strip for the **anterior talofibular muscle**. This application can be used for the three ligaments mentioned.

Alternative: The Y-technique for the **anterior talofibular** and **calcaneofibular ligaments** (■ Fig. 4.7d).

Memo

Application: Ligament technique

Cutting technique: I-tape, alternative: Y-tape



■ Fig. 4.8. a Red I-tape, b Red Y-tape

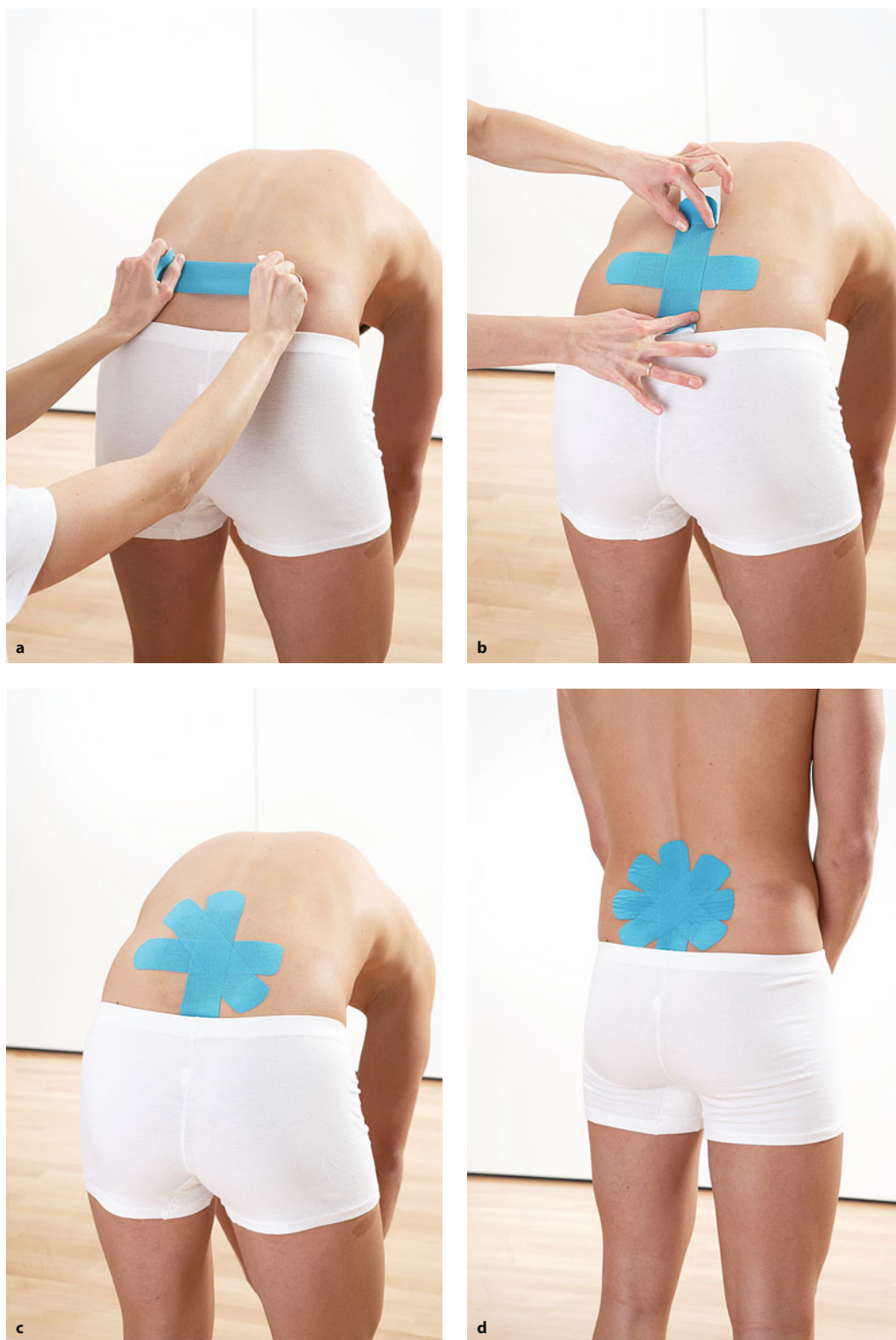

Fig. 4.9. a-d. Spacetape pain point: **a** Lumbar spine flexed, affix the tape strip with maximum stretch. First tape strip horizontal over the lumbar spine, the pain point in the center of the tape. Affix tape

ends without tension, **b** affix the second tape at 90° to the first, here vertically, **c** repeat the application technique for the diagonal tape strips, **d** completed application

4.2 Special form of ligament application: spacetape

- 4.2.1 Spacetape pain point
- 4.2.2 Spacetape trigger point

4.2.1 Spacetape pain point

Spacetape is a special form of ligament application affixed to **pain** and **trigger points** for pain attenuation.

Four tape strips, each approximately 15 cm long, are used. The application is affixed in a star shape. For problems with intervertebral disks, the first tape strip is applied at right angles to the spinal column and for muscle problems, at right angles to the course of the muscle.

Function

Pain attenuation, lifting the tissue

Application

In the following example, the spacetape application is used for an intervertebral disk problem.

The lumbar spine is flexed and the tape strips affixed with maximum stretch.

The first tape strip is affixed horizontally over the lumbar spine with the pain spot in the center of the tape strip. The tape ends are affixed without tension (■ Fig. 4.9a).

The second tape strip is affixed at a 90° angle to the first strip (■ Fig. 4.9b).

The application technique is repeated for the diagonal tape strips (■ Fig. 4.9c).

■ Fig. 4.9d shows the completed spacetape application.

Memo

Application: Ligament technique

Cutting technique: I-tape



■ Fig. 4.10. Blue I-tape

! Tip

For a spacetape application to a facet joint, the spine is positioned three-dimensionally (flexion/lateral flexion/rotation). In this case, the tape length is generally only 10cm.

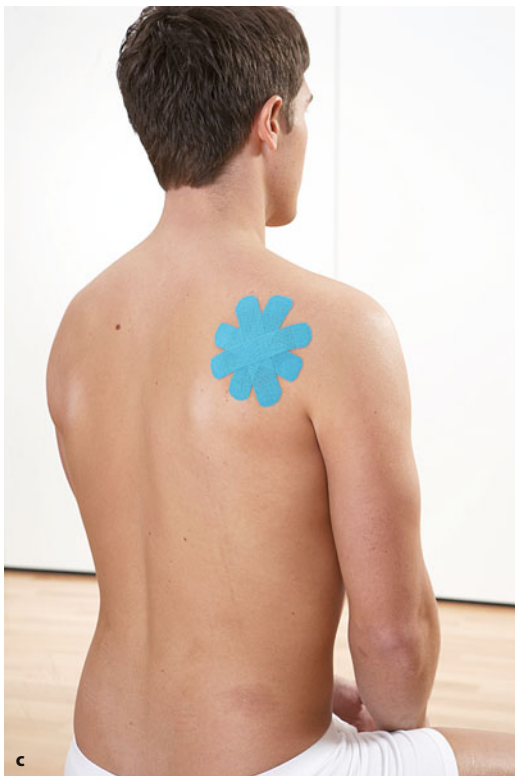
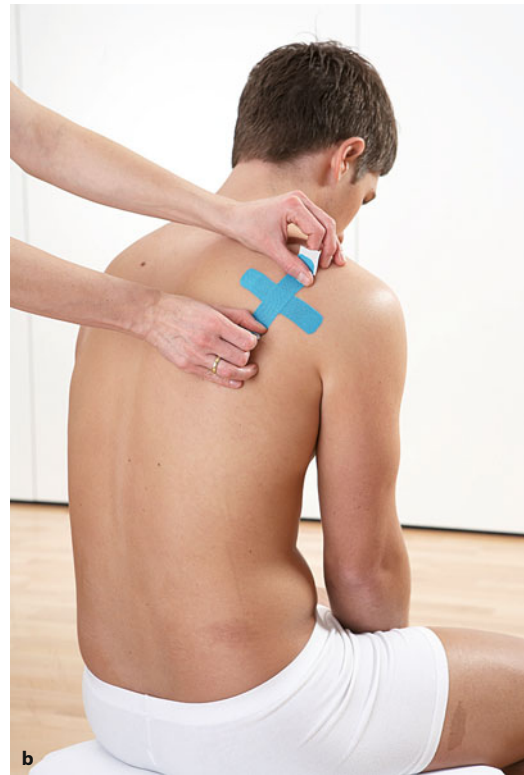
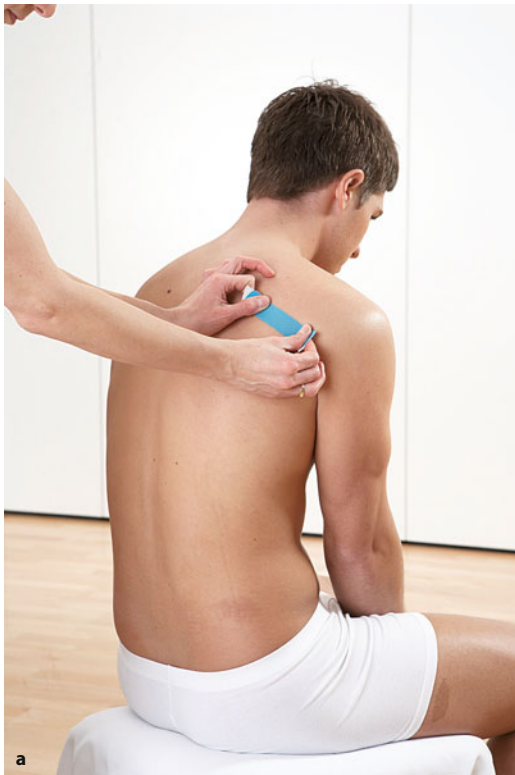Fig. 4.11. a-c Spacetape trigger point: **a** Shoulder protracted, affix the entire length of the maximally stretched tape strips. Affix tape ends without tension, **b** repeat the application technique for each tape strip. Sequence: horizontal, vertical, diagonal, **c** completed application

4.2.2 Spacetape Trigger point

As with a pain point, 4 tape strips are used for the treatment of **trigger points**. The tape width as well as the tape length is adapted to the location of the trigger point. As a general rule, the tape width is halved.

Function

Pain attenuation, lifting the tissues

Application

In the following example, the spacetape application is used for an **infraspinatus problem**.

The shoulder is placed in the protracted position. The tape is affixed with maximum stretch along its entire length. The tape ends are affixed without tension (■ Fig. 4.11a).

Repeat the application technique for each tape strip. The sequence of application is: horizontal, vertical, diagonal (■ Fig. 4.11b).

■ Fig. 4.11c shows the completed application.

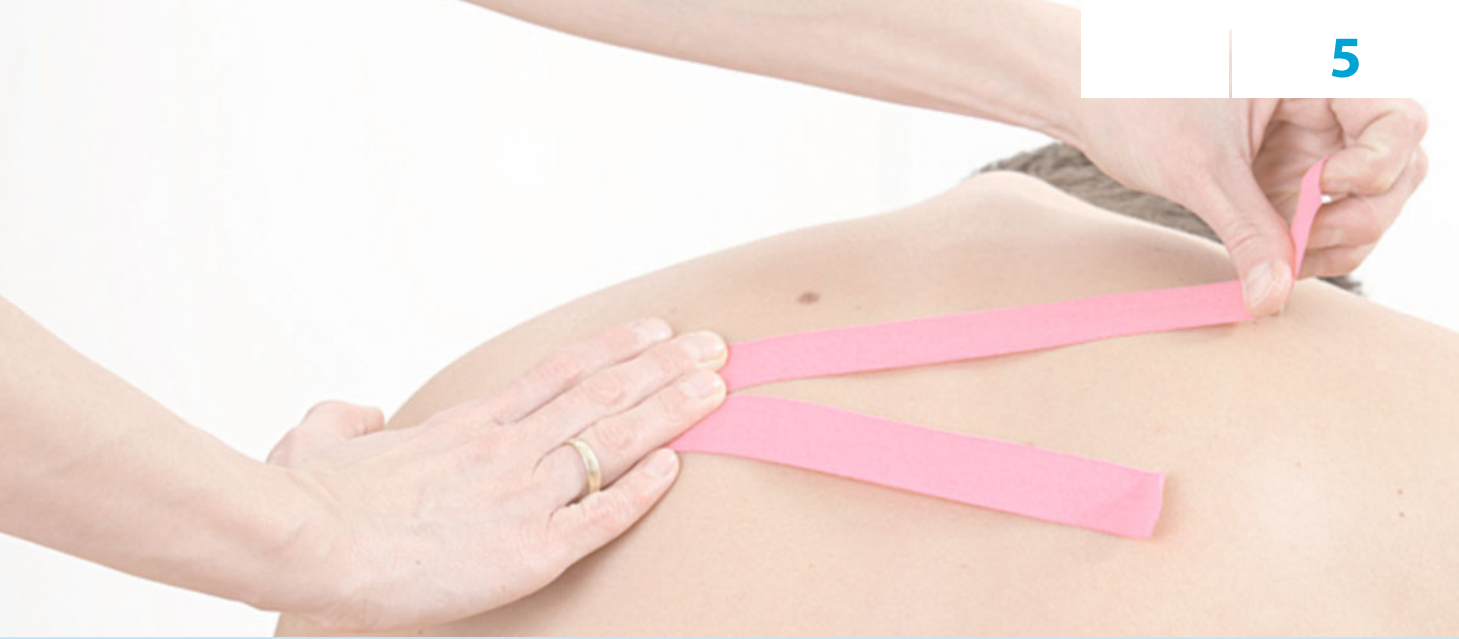Memo

Application: Ligament techniques

Cutting technique: Halved I-tape



■ Fig. 4.12. Blue I-tape



5 Corrective Applications

5.1 Functional correction – 93

- 5.1.1 Patella correction – 93
- 5.1.2 Scoliosis – 95
- 5.1.3 Spinous process correction – 97

5.2 Fascia correction – 99

- 5.2.1 Fascia correction of iliotibial tract – 99
- 5.2.2 Inflammation of the superficial pes anserinus – 101
- 5.2.3 Frontal headache – 103
- 5.2.4 Anterior shoulder instability – 105
- 5.2.5 Hallux valgus – 107

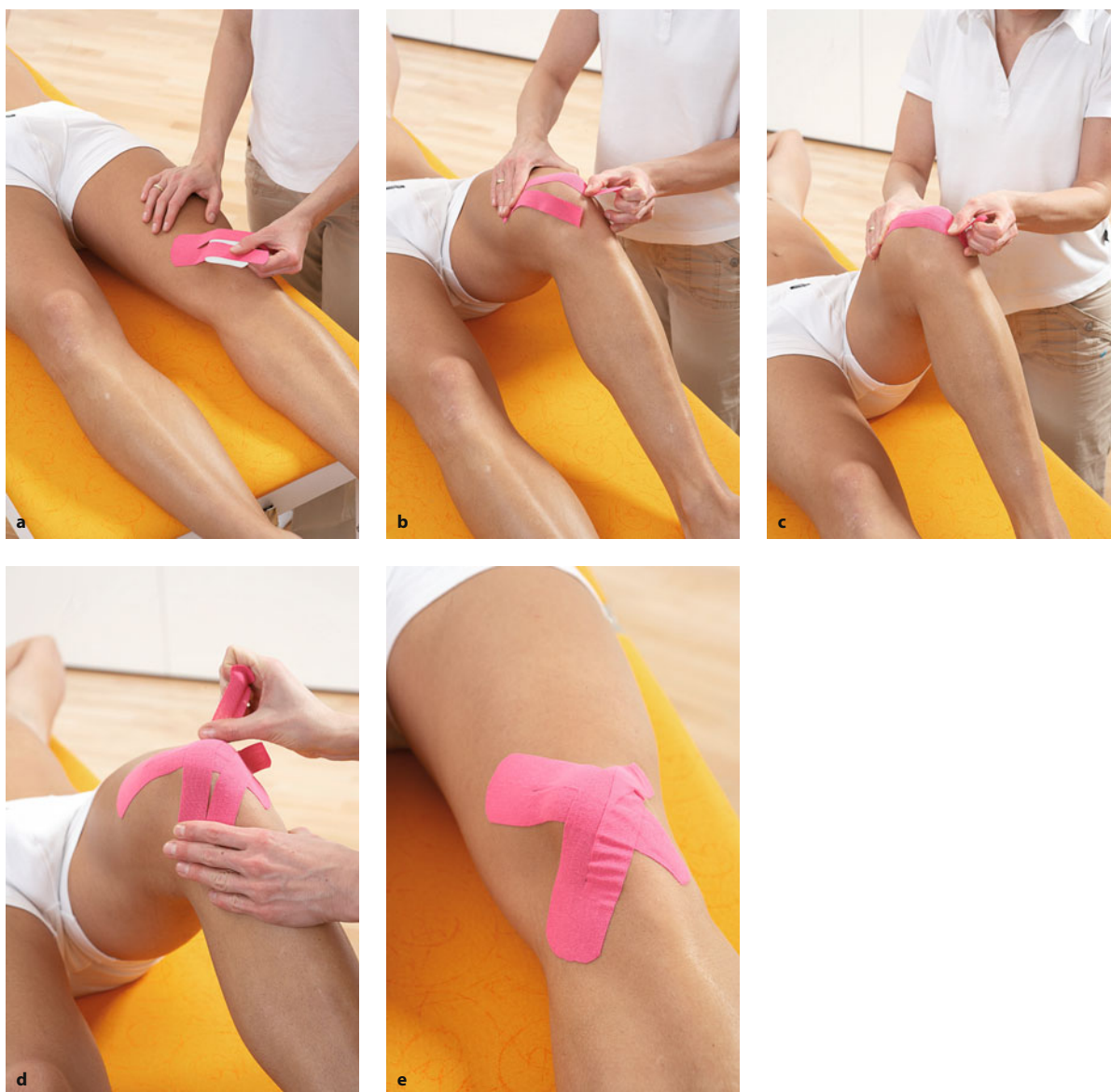

Fig. 5.1 a-e. Patella fracture: **a-c Application Part 1.** **a** Knee in neutral position. Affix the base medially and proximally. Place both tape tails on the skin in the direction of the correction, **b** anchor the base with maximum skin displacement. The patient slowly moves the knee from the neutral to the flexed position. During this movement, the upper tape tail is affixed over the patella up to its lateral margin with maximum tension. Affix tape end without tension in maximum

knee flexion position, **c** place knee in the neutral position again. Affix tape tail 2 as for tape tail 1. **d-e Application Part 2.** **d** Knee in the neutral position. Affix base medially and distally. Upper tape tail is affixed over the patella up to its lateral margin with maximum tension during movement, as described for the previous tape strip. The lower tape tail is affixed without tension and with maximum knee flexion, **e** completed corrective application

5.1 Functional correction

- 5.1.1 Patella correction
- 5.1.2 Scoliosis
- 5.1.3 Spinous process correction

5.1.1 Patella correction

Correction

In the following example, there is a **lateralization of the patella**. A functional correction adjusts the patella medially and proximally, thus supporting the generally weak muscular tension in the vastus medialis muscle.

Base

- Base 1: Medial proximal to the vastus medialis muscle
- Basis 2: Medial distal in the region of the pes anserinus

Application

- **Application Part 1:** Both tape strips are measured from the medial condyle of the femur diagonally over the patella up to the lateral outer margin of the patella with the knee extended. With the knee in the neutral position, the base is affixed medially and proximally to the vastus medialis, and then the two tail tapes are placed on the skin in the direction the correction is to be made (■ Fig. 5.1a).

With maximum skin displacement, the base is anchored with the hand, and the patient moves the knee slowly from the neutral into the flexed position. During this movement, the upper tape tail is affixed with maximum tension over the patella up to its lateral margin. The tape end is affixed without tension in the maximum knee flexion position (■ Fig. 5.1b).

The knee is brought into the neutral position again and the second tape tail is affixed over the patella, slightly offset, in the same way as the first (■ Fig. 5.1c).

- **Application Part 2:** The knee is in the neutral position and the base affixed medially and distally in the region of the pes anserinus. The upper tape tail is affixed over the patella up to its lateral margin with maximum tension while the knee is being brought into the flexed position, as described for the previous tape strips. The lower tape tail is affixed without tension in the maximum knee flexion position (■ Fig. 5.1d).

■ Fig. 5.1e shows the completed application.

Memo

Application: Functional corrective technique

Cutting technique: Y-tape



■ Fig. 5.2. Red Y-tape

! Tip

To retain maximum freedom of movement of the knee joint, a large amount of skin displacement should be applied against the direction of pull of the tail tape.

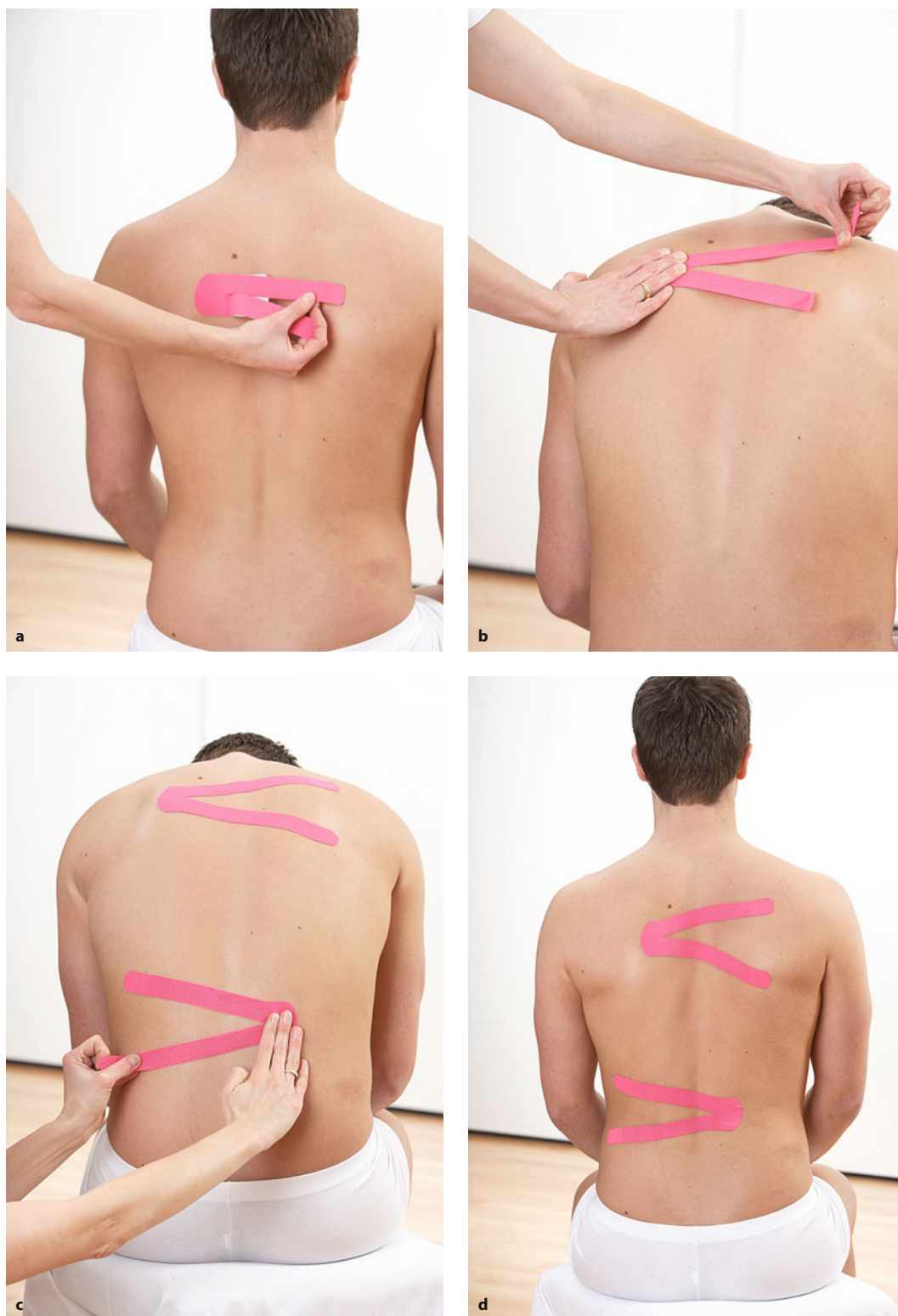

Fig. 5.3 a-d. Scoliosis: **a** Affix base laterally to the left of the cervical spine. Place the tape tails on the skin in the direction of the correction, **b** upper body bent forwards. Anchor cervical spine base with strong skin displacement against the direction of pull of the tape tails. Affix tape tails one after the other over the cervical spine in the bent

position. Affix ends without tension, **c** affix base laterally to the right of the lumbar spine and anchor with strong skin displacement against the direction of pull of the tail tapes. Affix tail tapes one after the other over the lumbar spine in the bent position. Affix ends without tension, **d** completed scoliosis application

5.1.2 Scoliosis

In scoliosis, the spine can no longer be held completely upright.

There is **sideways curvature** of the spine with concomitant **rotation of the vertebrae**. In order to maintain balance, the spine forms several opposing curves which mutually compensate each other.

In 80% of cases, scoliosis is a **growth deformity** of unknown cause (**idiopathic scoliosis**). The remaining 20% of cases arise through vertebral malformation, differences in leg length, nerve and muscle disorders, bone metabolism, connective tissue disorders, and severe scar formation, e.g., following thoracic surgery, accidents, or tumor surgery.

In this example, the functional correction is applied to a scoliotic malposition of less than a **15° Cobb angle** (determination of the angle of curvature according to John Robert Cobb) without rotation.

Progressive scolioses greater than a 20° Cobb angle must be treated individually with K-Taping applications and, if necessary, with the addition of a spinal brace.

Correction

In this example, a **convexity of the thoracic vertebrae** to the right is corrected with a **functional corrective application** to the left, and a **convexity of the lumbar vertebrae** is corrected with the same application technique to the right.

Bases

- Base 1: Thoracic vertebrae left
- Base 2: Lumbar vertebrae right

Application

- **Application Part 1:** A tape strip length of 15-20 cm is generally sufficient. The base is affixed laterally to the left of the thoracic spine. Place the tape tails on the skin in the direction that the correction is to be made (■ Fig. 5.3a). The patient is requested to bend forwards.

Anchor the base to the cervical spine with strong skin displacement against the direction of pull of the tape tail. Affix the tape tails one after the other over the cervical spine with the patient bent forwards. Affix the tape ends without tension (■ Fig. 5.3b).

- **Application Part 2:** Anchor the base laterally to the right of the lumbar spine with strong skin displacement against the direction of pull of the tape tails. Affix the tape tails one after the other over the lumbar spine with the patient bent forwards. Affix the tape ends without tension (■ Fig. 5.3c).

■ Fig. 5.3d shows the completed scoliosis application.

Memo

Application: Functional correction technique

Cutting technique: Y-tape



■ Fig. 5.4. Red Y-tape

! Tip

Through the malposition, the muscles are generally subjected to unphysiological muscle strain. The application is therefore frequently carried out in combination with a muscle application (see Applications for Specific Indications Scoliosis ► Chap. 6.2.3).

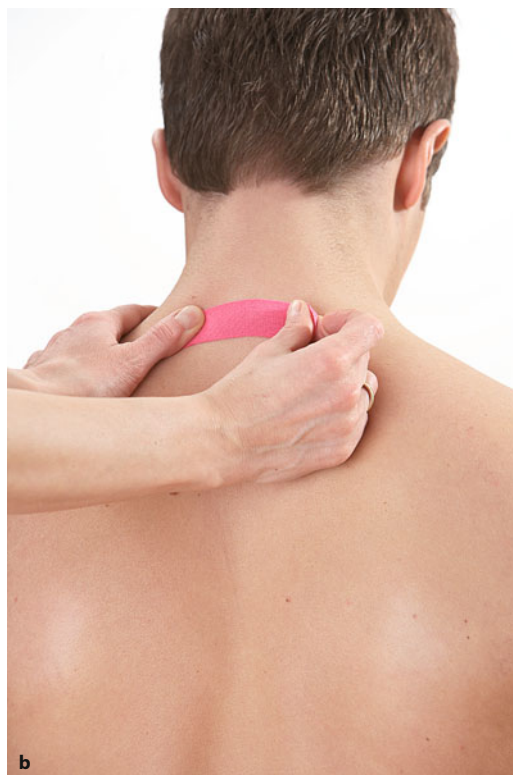
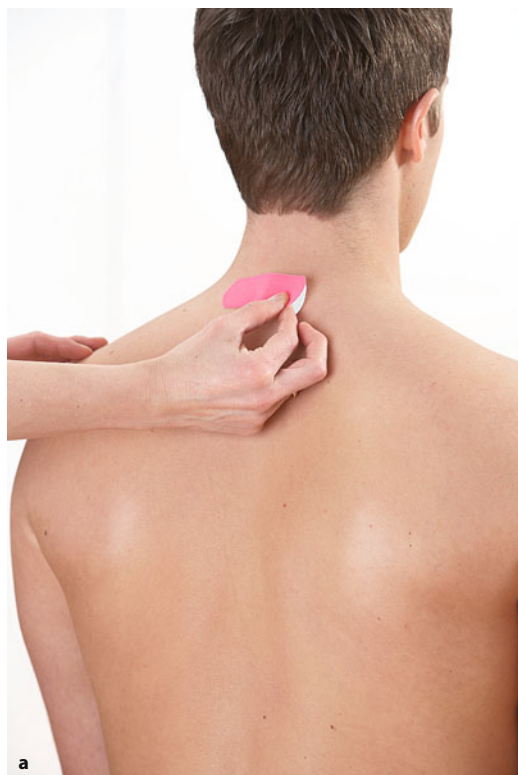
Fig. 5.5 a-c. Spinous process correction: **a** Affix the base to the left adjacent to the C7 spinous process, **b** bend the head forwards. Affix the base with strong skin displacement against the direction of pull. Affix tape strip with maximum tension over the C7 spinous process, with tension only over C7. Tape is fastened behind the spinous process, **c** completed correction of spinous process

5.1.3 Spinous process correction

Correction

Spinous process correction is frequently used following mobilization or manipulation of the cervical vertebrae by a physician or physiotherapist. K-Tape provides the opportunity to positively support the treatment results and to prolong the effects

In this example, a right rotation of the C7 spinous process is corrected.

Base

Laterally to the left adjacent to C7

Application

The base is affixed on the left next to the spinous process of the C7 vertebra (■ Fig. 5.5a).

The head is bent forwards. The tape strip is affixed over the C7 spinous process with maximum tension and strong skin displacement against the direction of pull. The tension runs only slightly beyond the C7 vertebra. The tape is fastened, in effect, behind the spinous process (■ Fig. 5.5b).

■ Fig. 5.5c shows the completed application for spinous process correction.

Memo

Application: Functional correction technique

Cutting technique: I-tape



■ Fig. 5.6. Red I-tape

! Tip

The spinous process of C7 is frequently displaced from its position by tension in the shoulder-neck muscles. It is therefore expedient to use a combination of the corrective technique and a muscle application to the transverse trapezius muscle and rhomboideus minor muscle.

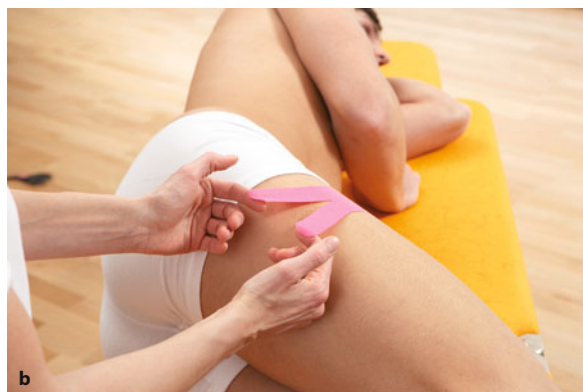

Fig. 5.7 a-d. Fascia correction of the iliotibial tract: **a** Thigh in resting position. Tape is measured according to muscle width, **b** affix base. Place tape tail on the skin in the direction of the correction, transversely to the muscle fiber course. The pain point lies between the

tape tails, **c** stretch the tape tails rhythmically in the direction of the correction and affix them at the moment the required skin displacement is attained. Affix the ends without tension, **d** completed fascia correction

5.2 Fascia correction

- 5.2.1 Fascia correction to the iliotibial tract
- 5.2.2 Inflammation of the superficial pes anserinus
- 5.2.3 Frontal headache
- 5.2.4 Anterior shoulder instability
- 5.2.5 Hallux valgus

5.2.1 Fascia correction of iliotibial tract

Correction

The following example illustrates the loosening of muscle fascia adhesions in the iliotibial tract using a **fascia correction**.

Base

In order to mobilize the affected tissue towards the free area, the tape is applied anterior to the pain point opposite the free direction. In this example, the base is positioned ventrally to the iliotibial tract, transversely to the course of the muscle fibers, to mobilize the tissue dorsally towards the unaffected area.

Application

The thigh is in the resting position. The length of the tape strip corresponds to the muscle width (■ Fig. 5.7a). The base is affixed anterior to the pain point. The tape tails are placed on the skin in the direction of the correction, transversely to the muscle fiber course. The pain point lies be-

tween the tape tails (■ Fig. 5.7b). The tail strips are stretched rhythmically in the direction of the correction and affixed to the skin at the moment of maximum possible skin displacement. The ends are affixed without tension (■ Fig. 5.7c). ■ Fig. 5.7d shows the completed application for fascia correction of the iliotibial tract.

Memo

Application: Fascia correction

Cutting technique: Y-tape



■ Fig. 5.8. Red Y-tape

! Tip

Manually test the displaceability of the fascia in all directions to determine the best position for the base. To facilitate easier loosening of the fascia, the correction is made towards the free tissue. Depending on the diagnostic findings, the tapes can also be affixed in opposing directions.

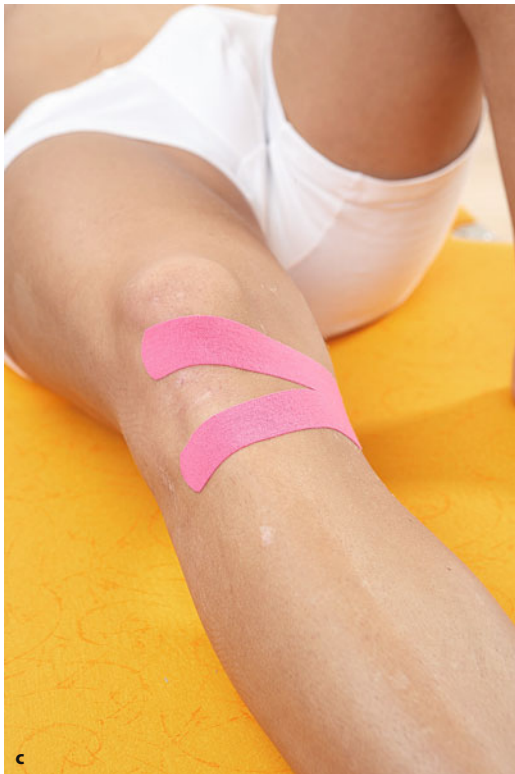
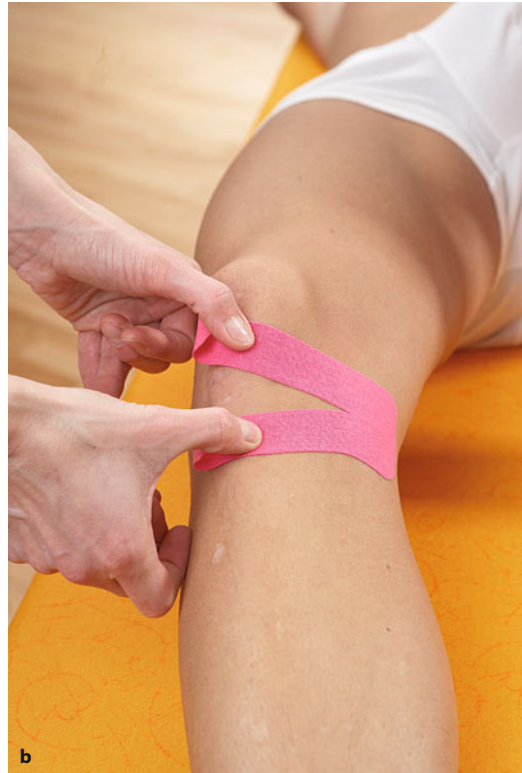
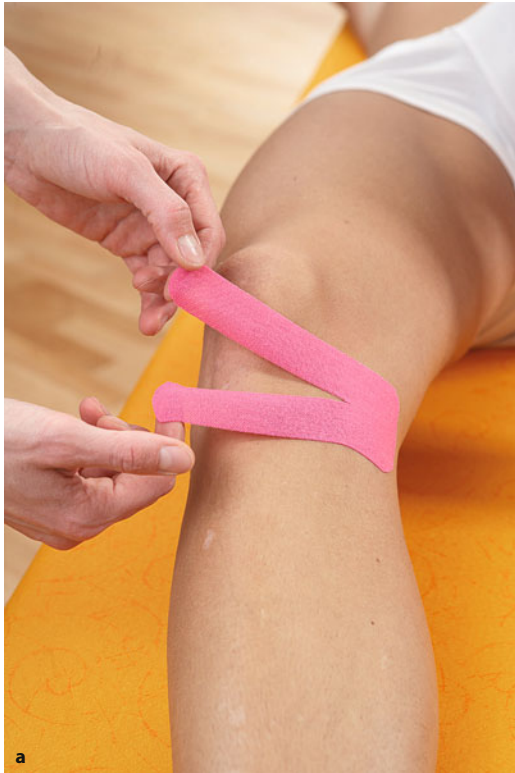Fig. 5.9 a-d. Fascia correction to the pes anserinus: **a** Knee in slightly flexed position. Base anterior to the pain point, **b** fascia technique: transversely to muscle fiber course, **c** completed fascia correction, **d** muscle application: tonus-reducing application to the three muscles, sartorius, gracilis, and semitendinosus

5.2.2 Inflammation of the superficial pes anserinus

Correction

Inflammation of the **superficial pes anserinus** may arise from overloading the muscles that insert there.

This condition can be relieved by applying a **fascia correction** to the pes anserinus.

Base

The application is positioned anterior to the pain point. In this example, the base is affixed laterally to the pes anserinus to mobilize the tissue medially in the direction of the free area.

Application

The knee is slightly flexed. The length of the tape strip corresponds to the width of the pes anserinus. The base is anterior to the **pain point** (■ Fig. 5.9a). The tape tails are rhythmically stretched and placed on the skin in the direction of the correction, transversely to the course of the muscle fibers. The ends are affixed without (■ Fig. 5.9b). ■ Fig. 5.9c shows the completed application for fascia correction of the pes anserinus.

Combination with a muscle application

For optimum relief, the fascia correction is used in combination with a **tonus-reducing muscle application** for the following muscles: sartorius, gracilis, and semitendinosus (■ Fig. 5.9d).

Memo

Application: Fascia correction, muscle technique

Cutting technique: Y-tape, I-tape



■ Fig. 5.10.
Red Y-tape



■ Fig. 5.11.
Blue I-tape



Tip

Pain relief for the superficial pes anserinus can also be effected by the application of a spacetape (► Chap. 4.2.1.).

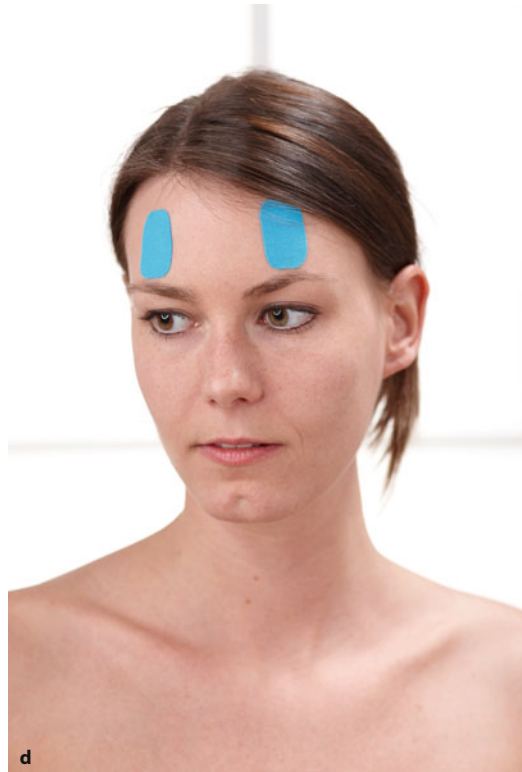
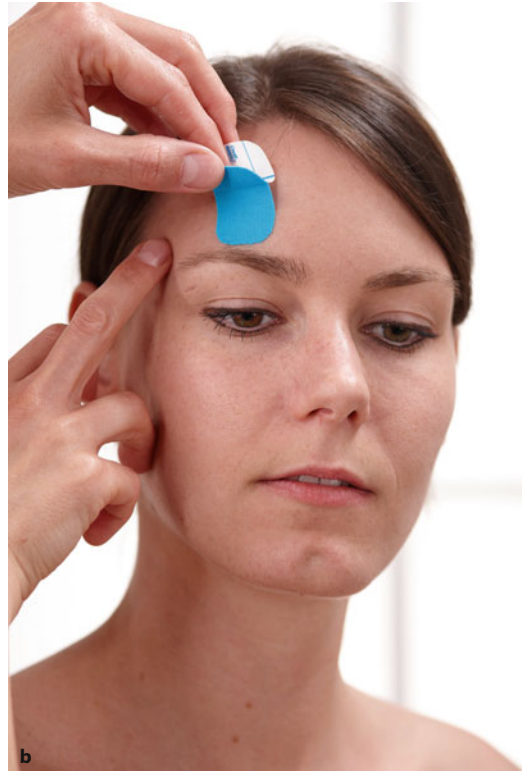
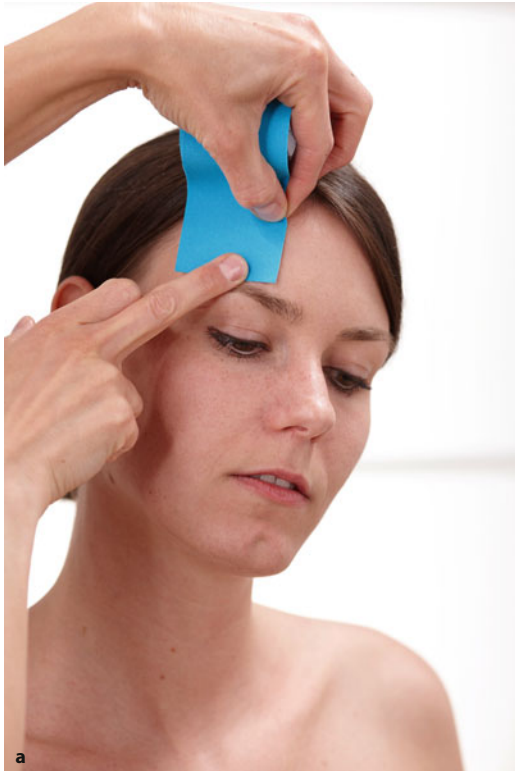Fig. 5.12 a-d. Frontal headache: **a** Measure the tape from above the eyebrow to below the hairline, **b** affix base above the eyebrow,

c displace the skin manually toward the hairline; fascia correction over the forehead; fascia is pulled cranially, **d** completed fascia correction

5.2.3 Frontal headache

Correction

One possible cause of a **frontal headache** is frontal sinusitis. Fascia correction results in relief of the forehead fascia.

Base

In this example, the base lies above the eyebrow so that the forehead fascia can be mobilized cranially towards the free area.

Application

The tape is measured from above the eyebrow to below the hairline and then cut in half (■ Fig. 5.12a). The base is anchored above the eyebrow and the remaining backing paper is removed from the tape (■ Fig. 5.12b). The skin is manually displaced towards below the hairline while the tape is affixed without tension and without rhythmic pull. The forehead fascia is pulled cranially (■ Fig. 5.12c). For optimum relief of the forehead fascia, both sides of the forehead are taped. ■ Fig. 5.12d shows the completed application for fascia correction of the forehead fascia.

Memo

Application: Fascia correction

Cutting technique: I-tape



■ Fig. 5.13. Blue I-tape

! Tip

Manually test the displaceability of the fascia cranially and caudally to determine the best position for the base.

To guarantee uniform tension in the tape and to avoid any strong stimulus to the face, it is imperative to ensure that the tape strip is affixed without tension.

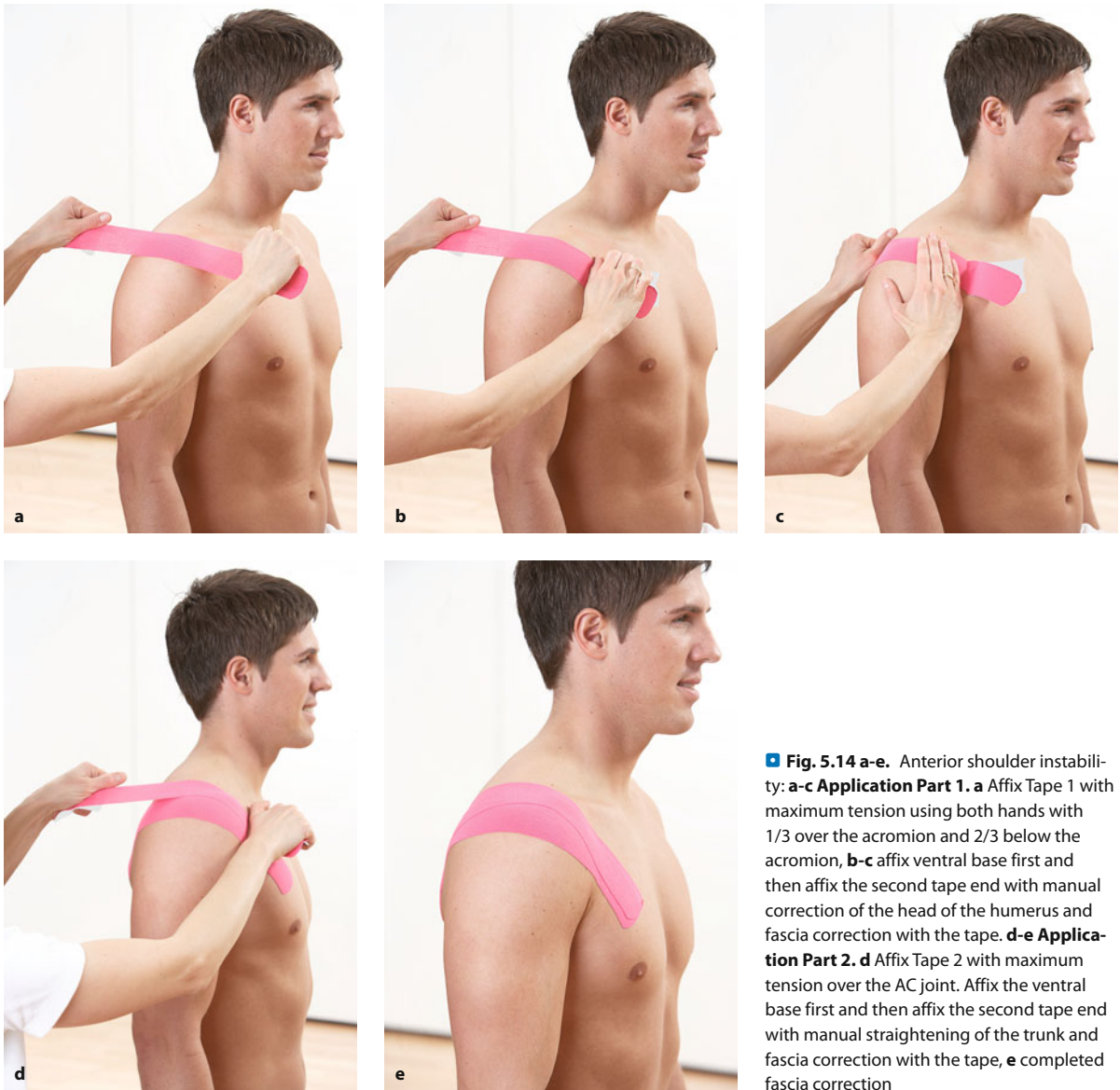


Fig. 5.14 a-e. Anterior shoulder instability: **a-c Application Part 1.** **a** Affix Tape 1 with maximum tension using both hands with 1/3 over the acromion and 2/3 below the acromion, **b-c** affix ventral base first and then affix the second tape end with manual correction of the head of the humerus and fascia correction with the tape. **d-e Application Part 2.** **d** Affix Tape 2 with maximum tension over the AC joint. Affix the ventral base first and then affix the second tape end with manual straightening of the trunk and fascia correction with the tape, **e** completed fascia correction

5.2.4 Anterior shoulder instability

In this tape application, two corrective techniques are combined: a **functional correction** to the head of the humerus over a **corrective fascia application**.

Features: I-tape-application with two separate strips that are affixed in the manner described for a functional correction. The base, however, is displaced dorsally over a manual correction of the head of the humerus carried out by the therapist.

Correction

The head of the humerus is corrected in a dorsal direction by means of the fascia correction.

Base

Unlike the other applications, which start with the base, the middle of the tape is affixed laterally to the acromion before the base is anchored ventrally

Application

— **Application Part 1:** The patient is as upright as possible. Both tapes are measured from the ventral axillary fold over the acromion to the dorsal axillary fold. Tape 1 is positioned with maximum tension using both hands so that 1/3 lies over the acromion and 2/3 below the acromion but with only the mid-section of the tape anchored (■ Fig. 5.14a). The ventral base is anchored first. The dorsal base is then anchored with a manual correction of the head of the humerus and an additional fascia correction with the tape. The ventral tape end is affixed without tension with the arm extended, and the dorsal tape end is affixed with the arm flexed (■ Fig. 5.14b-c).

— **Application Part 2:** Tape 2 is placed with maximum tension over the acromioclavicular joint (AC joint) but with only the mid-section of the tape anchored. As described for Tape 1, the ventral base is anchored first, and then the dorsal base is anchored with manual straightening of the trunk and an additional fascia correction with the tape. The ventral tape end is affixed without tension with the arm extended and the dorsal tape end is affixed with the arm flexed (■ Fig. 5.14d). ■ Fig. 5.14e shows the completed application for functional correction of the head of the humerus with a fascia correction.

Memo

Application: Fascia correction

Cutting technique: I-tape



■ Fig. 5.15. Red I-tape



Tip

To prevent compression in the joint and premature detaching of the tape, the tape is affixed with maximum tension only around the humerus

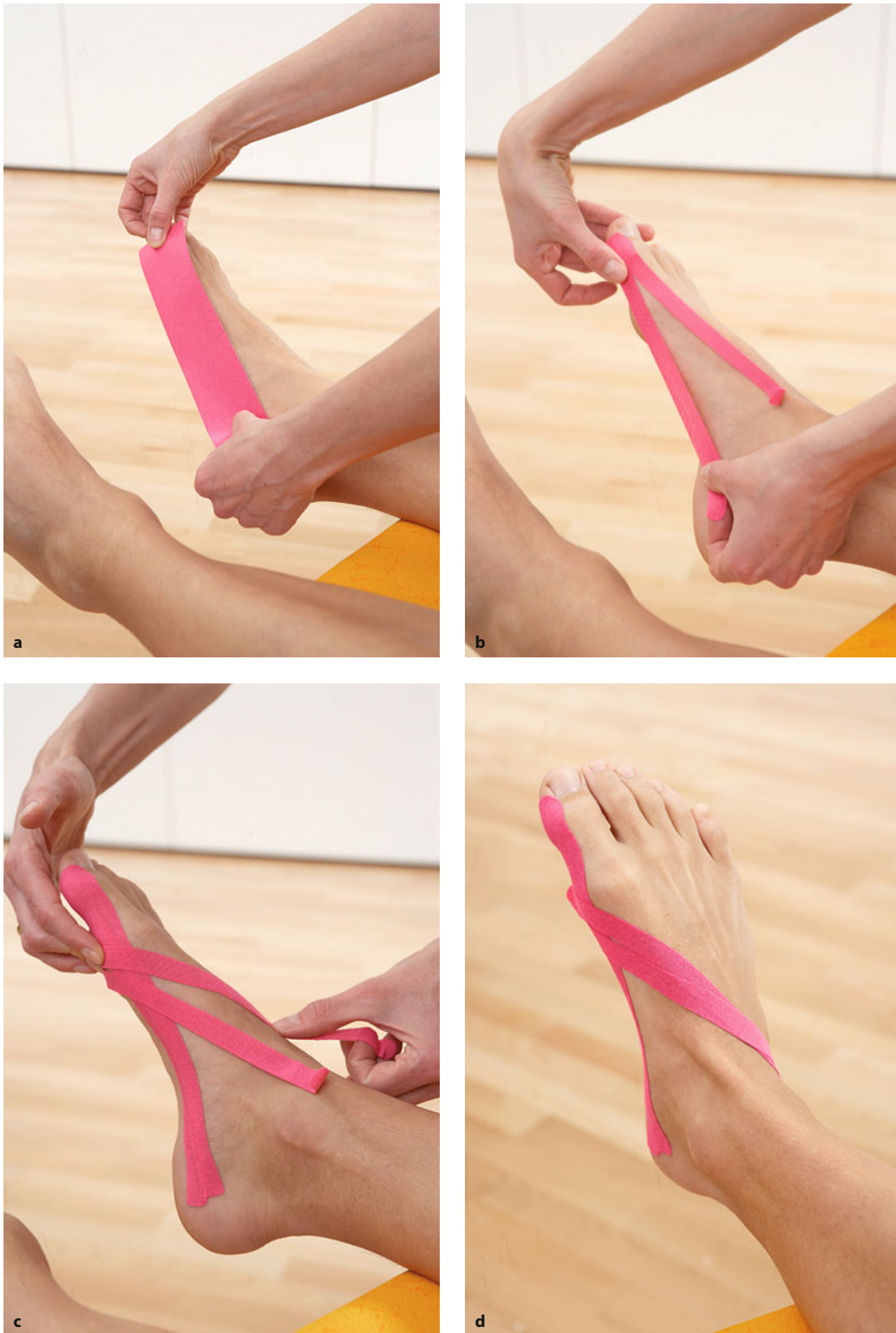

Fig. 5.16 a-d. Hallux valgus: **a-b Application Part 1.** **a** The tape is measured from the metatarsophalangeal joint to just before the calcaneus, **b** anchor the base of Tape 1 to the distal phalanx. Adjust the position of the big toe to correct its position. The fascia is corrected towards the heel. Affix both Y-tape tails using the same technique.

c-d Application Part 2. **c** Anchor the base of Tape 2 beneath the metatarsophalangeal joint. Adjust the metatarsophalangeal joint to correct its position. The fascia correction is made over the dorsum of the foot, **d** completed fascia correction

5.2.5 Hallux valgus

Correction

In the following example, there is a **malposition of the big toe** in adduction and extension.

By means of the fascia correction, relief and correction of the joint at the base of the big toe (metatarsophalangeal joint) in abduction and flexion are attained.

This application also combines a functional correction with a fascia correction.

Base

- Base 1: on the distal phalanx
- Base 2: under the metatarsophalangeal joint

Application

- **Application Part 1:** The foot is in the resting position. The tape is measured from the distal phalanx of the big toe to just before the calcaneus. The tape is cut in half along its length and each half is cut into a Y-form (■ Fig. 5.16a). The base of Tape 1 is affixed laterally to the distal phalanx. The first tail tape of the Y-tape is affixed along the medial foot margin with a manual correction to the big toe in abduction and a fascia correction with the tape. The tape end is affixed without tension. The second tape tail of the Y-tape is affixed next to the first tape tail, slightly offset, using the same technique. The tape end is affixed without tension (■ Fig. 5.16b).
- **Application Part 2:** The base of Tape 2 is anchored under the metatarsophalangeal joint. The metatarsophalangeal joint is then manually flexed. The first tape tail is affixed over the dorsum of the foot with a fascia correction. The tape end is affixed without tension. The second tape tail of the Y-tape is affixed next to the first tape tail, slightly offset, using the same technique. The tape end is affixed without tension. ■ Fig. 5.16d shows the completed application for the fascia correction in hallux valgus.

Memo

Application: Fascia correction

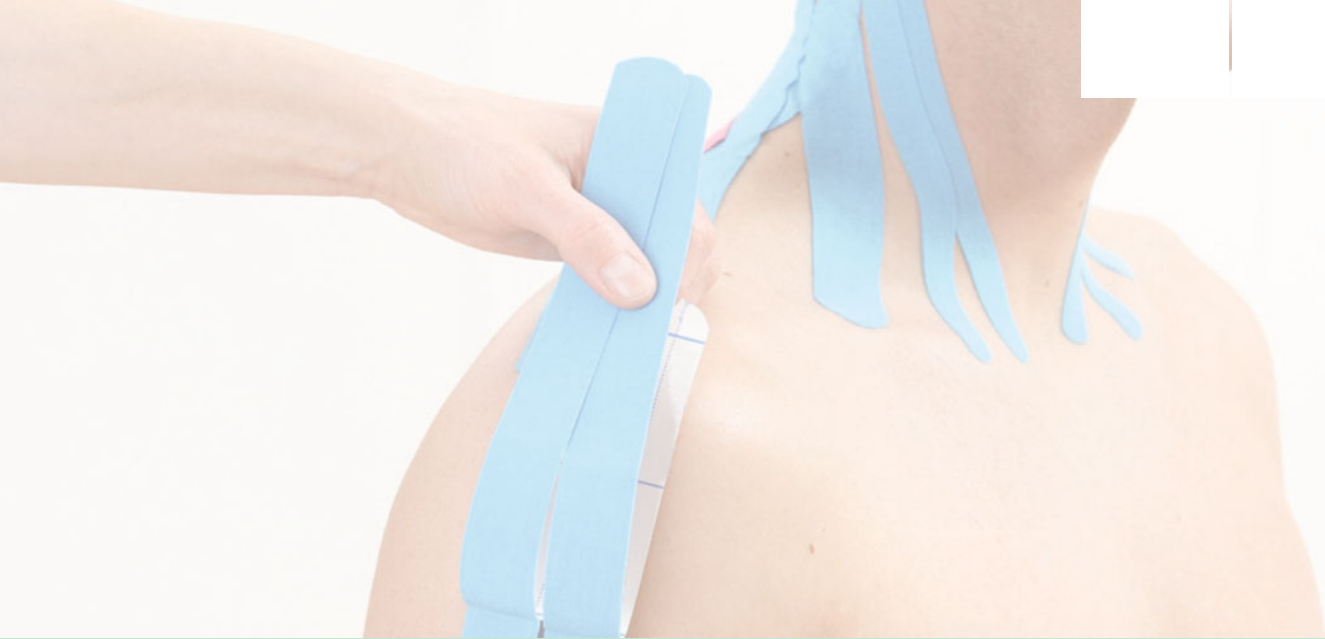Cutting technique: Y-tape



■ Fig. 5.17. Red Y-tape

! Tip

A too intensive correction of the big toe may lead to pain in the proximal joint. It is therefore better to carry out the correction gradually.



6 Applications for Specific Indications

6.1 Head – 111

- 6.1.1 Tinnitus – 111
- 6.1.2 Migraine – 113
- 6.1.3 Whiplash – 115
- 6.1.4 Temporomandibular joint – 117

6.2 Trunk – 119

- 6.2.1 Thoracic outlet syndrome (TOS) – 119
- 6.2.2 Asthma – 121
- 6.2.3 Scoliosis – 123
- 6.2.4 Lumbar vertebral syndrome (LVS) – 125
- 6.2.5 Micturition disorders – 127
- 6.2.6 Menstrual disorders – 129
- 6.2.7 Uterine prolapse – 131
- 6.2.8 Scar tape – 133

6.3 Upper extremities – 135

- 6.3.1 Impingement syndrome – 135
- 6.3.2 Biceps tendonitis – 137
- 6.3.3 Epicondylitis – 139
- 6.3.4 Carpal tunnel syndrome – 141
- 6.3.5 Wrist stabilization – 143
- 6.3.6 Finger contusion – 145

6.4 Lower extremities – 147

- 6.4.1 Hip problems – 147
- 6.4.2 Torn muscle fibers – 149
- 6.4.3 Osteoarthritis of the knee joint – 151
- 6.4.4 Achillodynia – 153
- 6.4.5 Ankle joint distortion – 155
- 6.4.6 Splayfoot, fallen arch, and flatfoot – 157

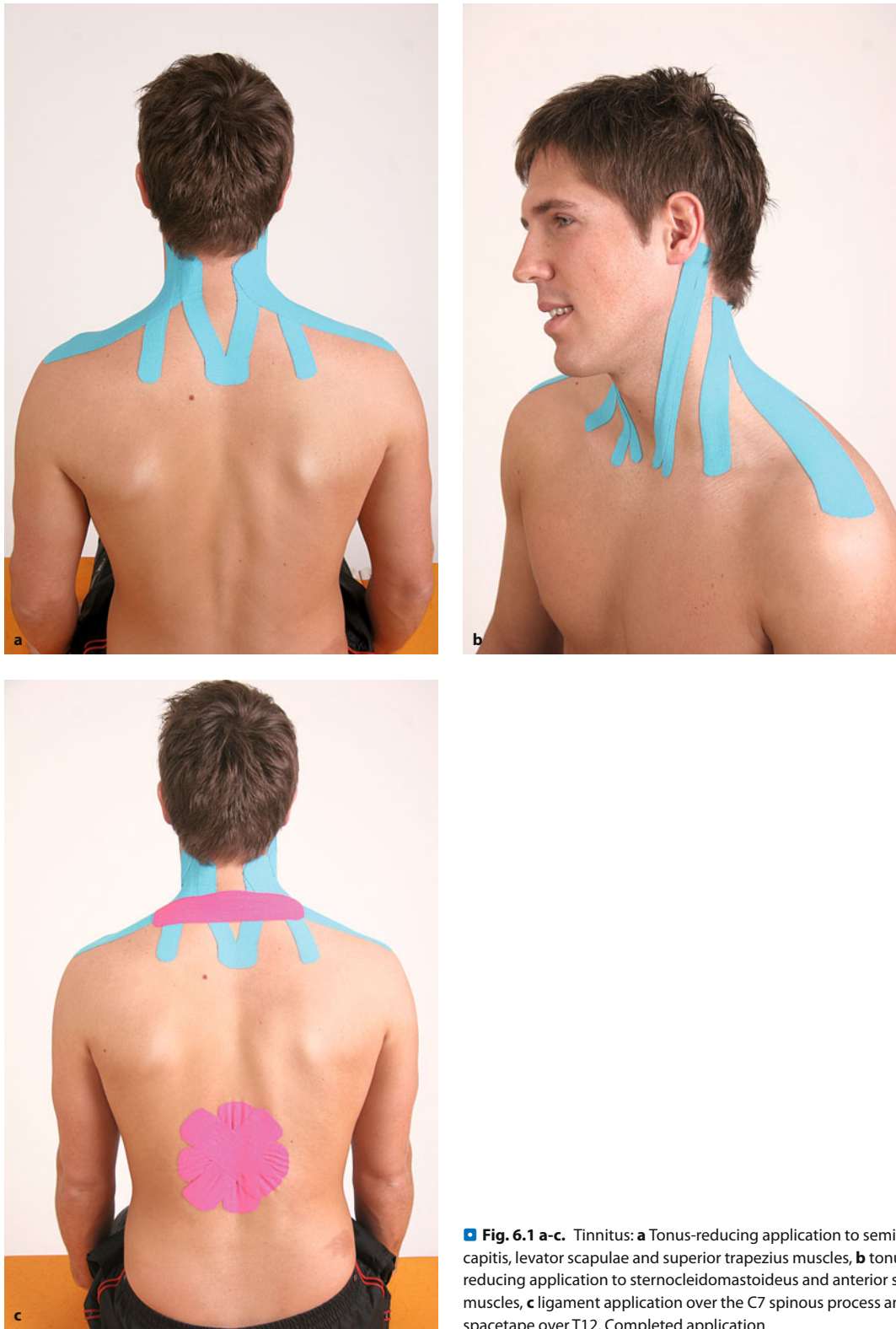

Fig. 6.1 a-c. Tinnitus: **a** Tonus-reducing application to semispinalis capitis, levator scapulae and superior trapezius muscles, **b** tonus-reducing application to sternocleidomastoideus and anterior scalene muscles, **c** ligament application over the C7 spinous process and spacetape over T12. Completed application

6.1 Head

- 6.1.1 Tinnitus
- 6.1.2 Migraine
- 6.1.3 Whiplash
- 6.1.4 Temporomandibular joint

6.1.1 Tinnitus

Definition

Tinnitus expresses itself as a permanent or rhythmic tone or noise in the ear.

The causes of tinnitus are varied and it is often a symptom of other illnesses.

Possible causes are loud noise, ear infections, faulty signal processing in the brain, and psychological stress.

It is assumed to result from the interaction of various factors leading to changes in the blood circulation of the inner ear.

The frequently-occurring, concomitant tension in the neck musculature is treated with K-Taping therapy.

Aim

Using various muscle applications to the **neck musculature**, relief of tension in these structures is achieved.

Application

The following muscles are treated with a tonus-reducing muscle application (■ Fig. 6.1a-b):

- semispinalis capitis muscle
- levator scapulae muscle
- superior region of the trapezius muscle
- sternocleidomastoideus muscle
- anterior scalene muscle

To preclude the patient experiencing a sensation of asymmetry, the neck musculature is taped bilaterally even in unilateral tinnitus.

In addition, the **CTM Head zones** are treated with two ligament application via the **cutivisceral reflex arc**. The skin stimulation is transmitted at the spinal level via a **sympathetic efferent** pathway, thus increasing the efficiency of the entire body and accelerating the chemical breakdown process (■ Fig. 6.1c):

- Spinous process C7
- Spacetape T12

Memo

Application: Muscle technique, ligament technique

Cutting technique: I- and Y-tape



■ Fig. 6.2.
Blue Y-tape



■ Fig. 6.3.
Blue I-tape



■ Fig. 6.4.
Red I-tape

! Tip

For the symmetry of the ventral muscle application, it is important that the tape be affixed without tension. The ventral application to the sensitive skin area of the neck is not well tolerated by all patients.

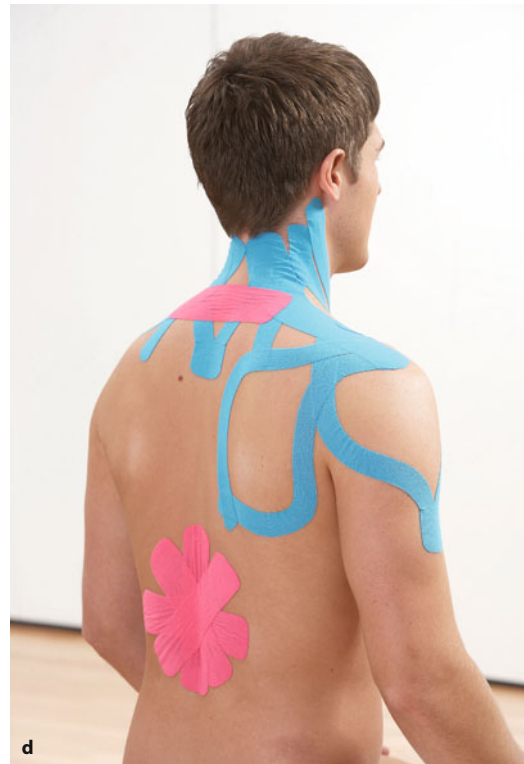
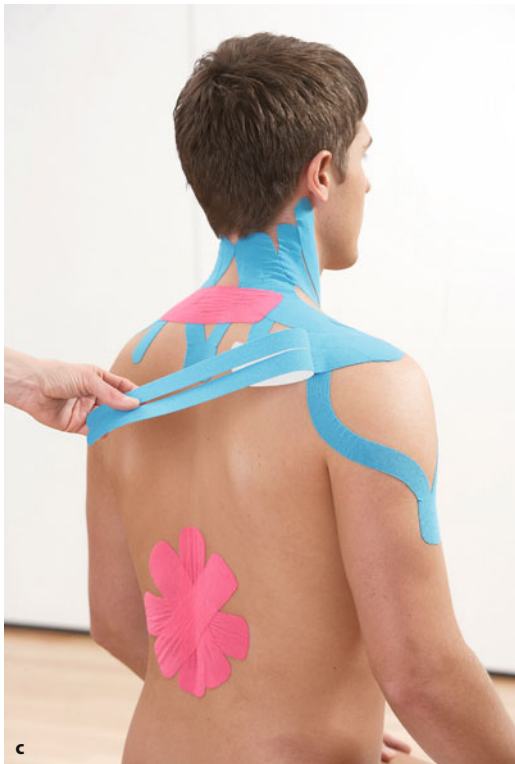
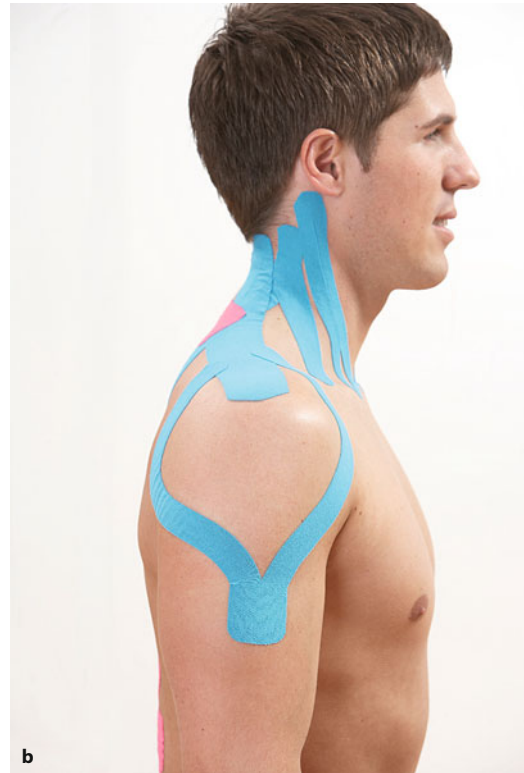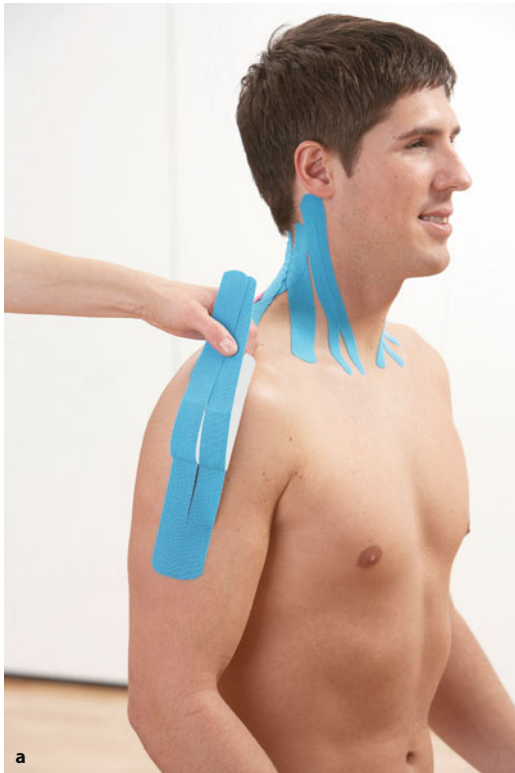Fig. 6.5 a-d. Migraine: **a** Tonus-reducing application to the ventral neck musculature and start of the application to the deltoid muscle, **b** completed tonus-reducing application to the neck musculature and the deltoid muscle, **c** completed tonus-reducing application to the

dorsal neck musculature with ligament applications C7 and T12, with start of application to the scapular margins, **d** completed muscle and ligament applications

6.1.2 Migraine

Definition

Migraine is a unilateral, pulsating headache with periodic, recurrent attacks. It is frequently accompanied by nausea, vomiting, and increased sensitivity to light.

The precise causes of migraine are not yet known.

In familial predisposition to migraine, a **genetic defect** has been postulated, but environmental influences and life-style also appear to play a role.

Tension in the neck musculature that frequently accompanies migraine is treated with K-Taping.

Aim

Using various muscle applications to the neck, shoulder, and arm musculature, relief of tension in these structures is achieved.

Application

The following muscles are treated using tonus-reducing muscle applications (■ Fig. 6.5a-b):

- semispinalis capitis
- levator scapulae
- anterior scalene
- sternocleidomastoideus
- superior trapezius
- deltoid
- supraspinatus
- pectoralis major/minor
- biceps brachii
- triceps brachii
- extensor carpi radialis longus/brevis
- flexor digitorum

The following muscles are treated with a tonus-increasing application (■ Fig. 6.5c-d):

- infraspinatus
- rhomboideus major

Two ligament applications are used to treat the connective tissue massage (CTM) Head zones:

- over C7
- spacetape on T12

The erect position of the trunk is supported with a fascia correction.

Memo

Application: Muscle technique, ligament technique, fascia correction technique

Cutting technique: I- and Y-tape



■ Fig. 6.6.
Blue Y-tape



■ Fig. 6.7.
Blue I-tape



■ Fig. 6.8.
Red I-tape

! Tip

Only positively tested muscles are taped.

The number of tapes is individually adapted to suit the patient.

All muscles are taped bilaterally to achieve symmetry.

For treatment success, treatment duration of at least 6 to 12 weeks is necessary.

New applications should be affixed once a week, with successive reduction in the muscle applications.

A bilateral application to the rhomboid major muscle using an X-technique is also possible:

The tape strips are measured from the spine to the medial margins of both scapulae with the trunk flexed. Fold the tape in the middle and cut from the open side. Leave a two fingerbreadth base in the center. The base is anchored to the spinous processes of C2 and C3 with the trunk erect and then the tape tails are affixed to the respective medial margins of the scapulae with the trunk flexed.

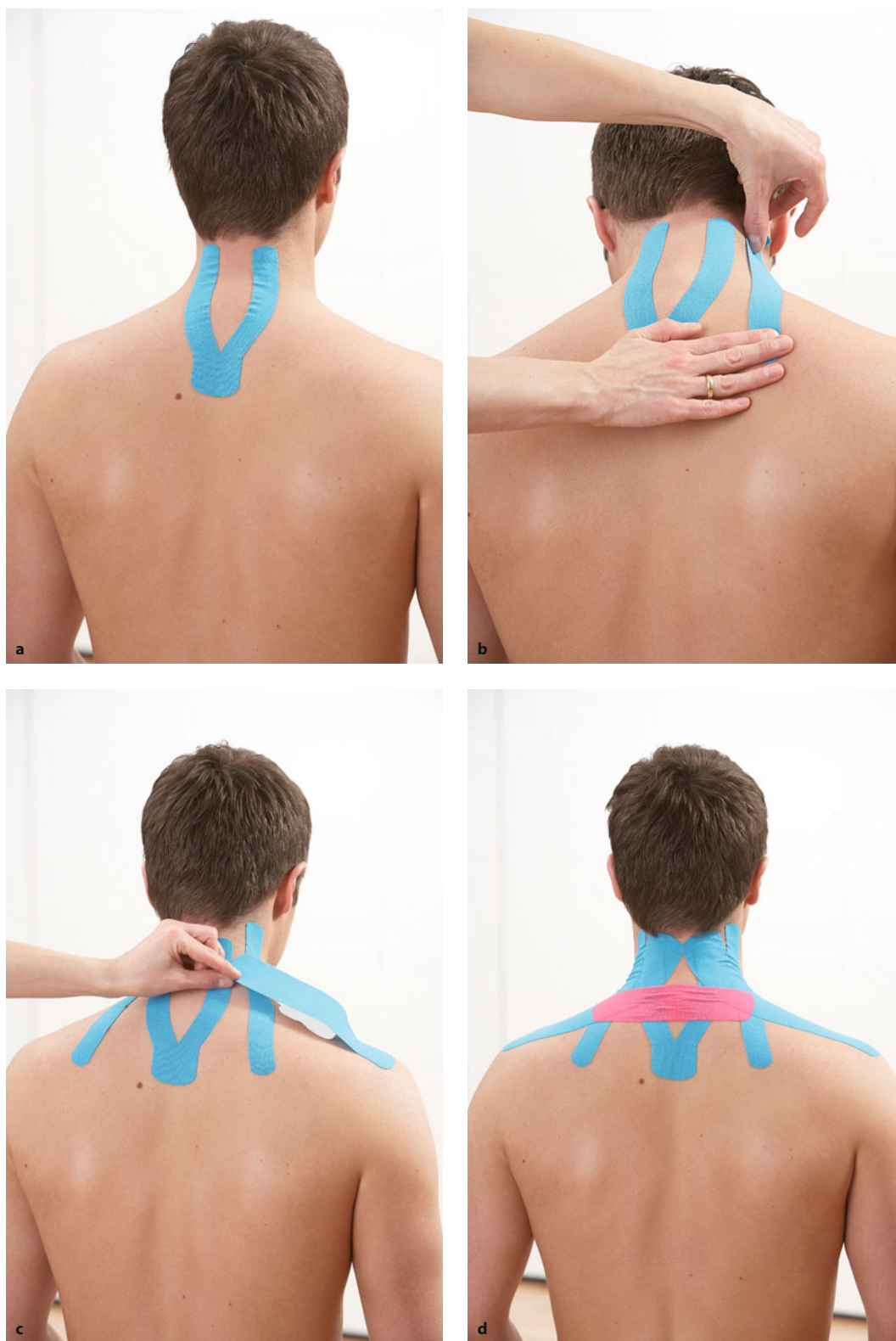


Fig. 6.9 a-d. Whiplash: **a** Tonus-reducing application to the semi-spinalis capitis, **b** tonus-reducing application to the levator scapulae,

c tonus-reducing application to the superior trapezius, **d** completed muscle and ligament applications

6.1.3 Whiplash

Definition

Whiplash is caused by sudden flexion and overextension of the cervical spine and the associated soft tissue injuries.

Causes are predominantly traffic accidents and sports injuries.

Aim

Various muscle applications to the neck musculature bring about a relief of tension.

Application

The following muscles are treated with tonus-reducing muscle applications (■ Fig. 6.9a-c):

- semispinalis capitis
- levator scapulae
- superior trapezius

A ligament application is used to treat the CTM Head zone (■ Fig. 6.9d):

- C7 spinous process

Memo

Application: Muscle technique, ligament technique

Cutting technique: I- and Y-tape



■ Fig. 6.10.
Blue Y-tape



■ Fig. 6.11.
Blue I-tape



■ Fig. 6.12.
Red I-tape

! Tip

In **acute whiplash trauma**, a **lymphatic application** is also appropriate, since the sudden flexion and overextension of the cervical spine also damages **lymphatic vessels**. The fan-shaped tapes are affixed so that they intersect over the cervical vertebrae. The tape is measured from the superior angle of the scapulus across the spine to the hairline, with flexion of the cervical spine. The tape is cut into four strips. The base is anchored to the superior angle of the scapula in the neutral position. With the cervical spine flexed, the individual tail tapes are affixed with 25% tension across the spine. The ends are affixed without tension. The crossing of the tape strips mobilizes the connective tissue and allows any **hematomas** to be more rapidly resorbed.

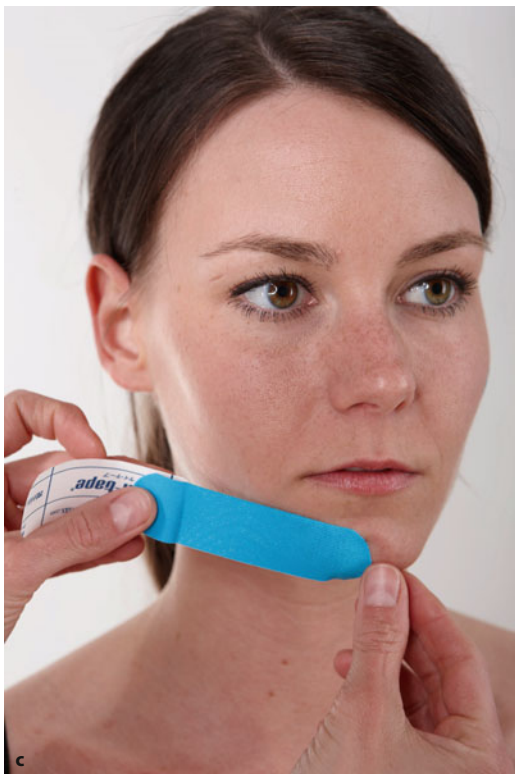



Fig. 6.13 a-d Temporomandibular joint (TMJ): **a** Tonus-reducing muscle application to the left masseter muscle, **b** ligament application

over the left TMJ, **c** base at center of chin. Fascia correction of mandible towards the right, **d** completed application

6.1.4 Temporomandibular joint

Definition

Disorders in the area of the masticatory system are subsumed under the collective heading of **craniomandibular dysfunction**.

This may involve pain in the **masticatory musculature**, slipped disc in the temporomandibular joint (TMJ), as well as inflammatory or degenerative changes to the TMJ.

Aim

Muscle and ligament applications and a fascia correction achieve relaxation of the temporomandibular musculature and an improvement in the mechanics of the joint. Depending upon the diagnostic findings, these applications may also be carried individually.

Application

The masseter muscle is treated with a tonus-reducing muscle application. The tape is measured from the mandibular angle to the zygomatic arch with the mouth fully open. The tape is halved lengthwise. With the mouth slightly open, the base is affixed to the mandibular angle and then anchored with maximum possible manual skin displacement. The tape is then affixed without tension up to the zygomatic arch with the mouth fully open (■ Fig. 6.13a).

The TMJ is treated with a ligament application. The tape width is cut to correspond to the size of the TMJ and the tape length is measured from the earlobe to the supratragic notch. With the mouth half open, the tape is affixed en bloc with maximum tension. The tape ends are affixed without tension (■ Fig. 6.13b).

By means of a functional correction using a fascia technique, the mandible is corrected towards the right. The tape is cut to half its width. The base is affixed to the center of the chin. The tape is affixed without tension and with only manual skin displacement towards the mandibular angle (■ Fig. 6.13c).

■ Fig. 6.13d shows the completed application for the TMJ.

Memo

Application: Muscle technique, ligament technique, functional corrective technique as fascia technique

Cutting technique: I-tape



■ Fig. 6.14.
Blue I-tape



■ Fig. 6.15.
Red I-tape

! Tip

The **fascia technique** in the area of the floor of the mouth, which is frequently tense, provides a further possibility for taping. The area under the chin is tested first to find the direction of skin displacement that brings relief. Using half of a 5 cm I-tape, the base is affixed in the opposing direction to the subsequent fascia application and affixed with a slight pull.

In addition, a **Cross-Tape** may be affixed to the TMJ to relieve tension.

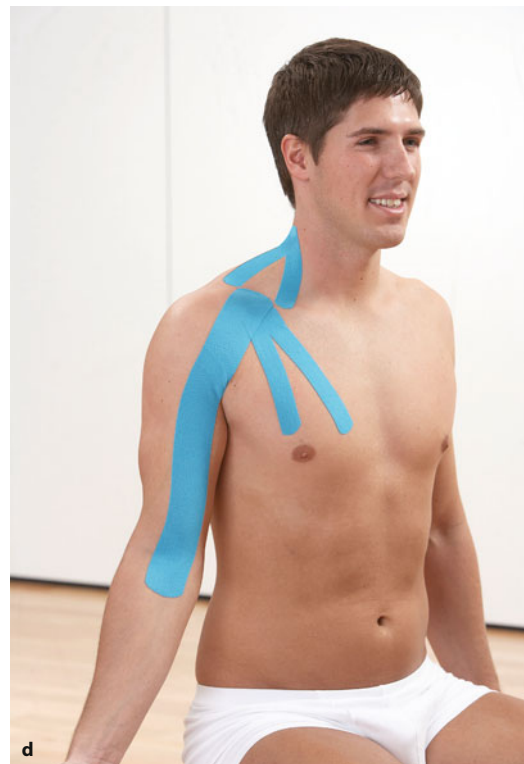
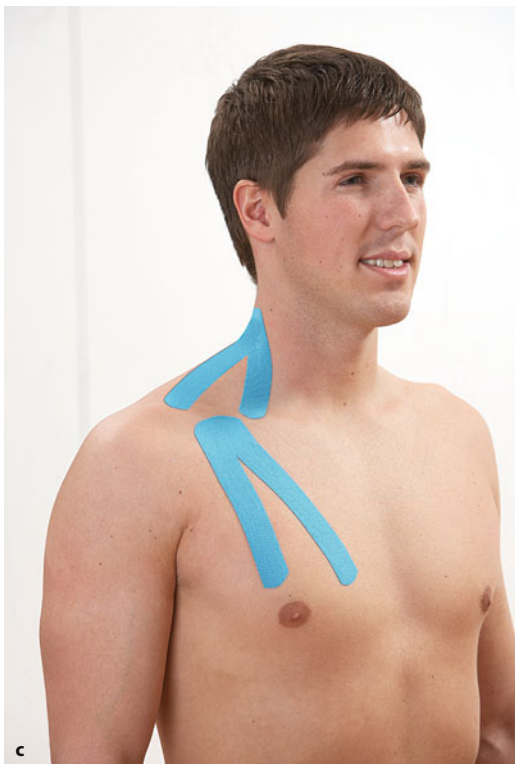
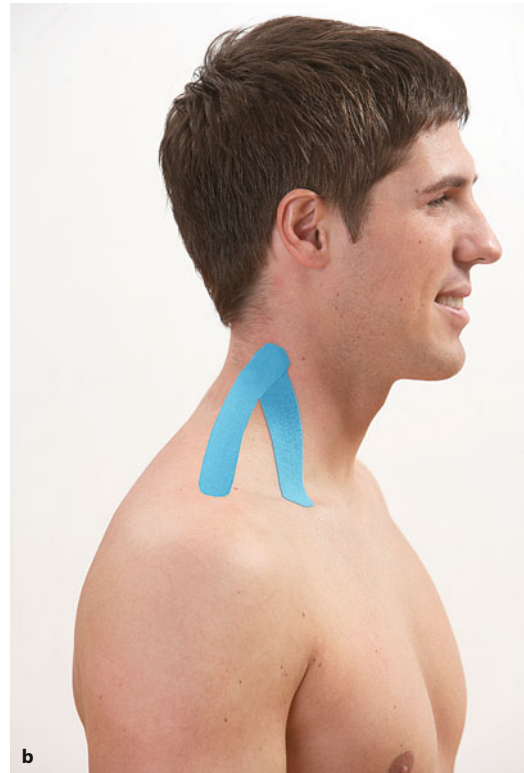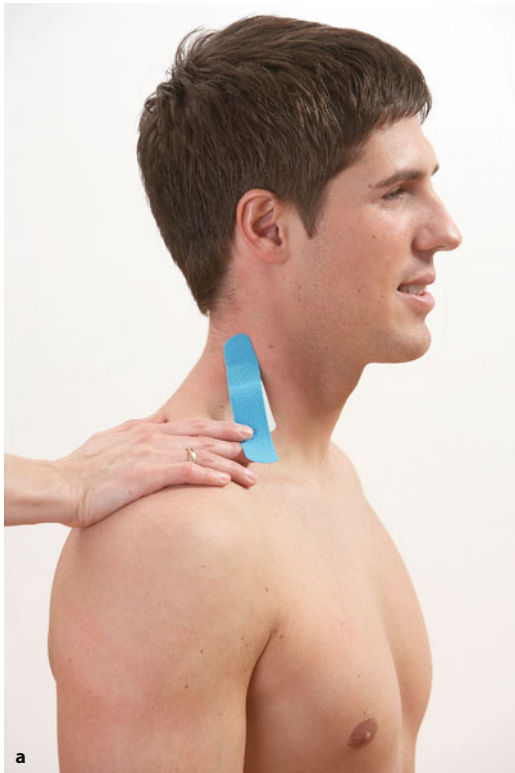Fig. 6.16 a-d. Thoracic outlet syndrome: **a** Tonus-reducing muscle application to the anterior scalene muscle. Base on transverse process C3-C4, **b** tonus-reducing application to the posterior scalene muscle. Base on transverse process C5-C7, **c** tonus-reducing application to the

pectoralis minor muscle. Basis on coracoid process, **d** tonus-reducing application to the biceps brachii muscle. Base beneath the inner elbow. Completed application

6.2 Trunk

- 6.2.1 Thoracic outlet syndrome (TOC)
- 6.2.2 Asthma
- 6.2.3 Scoliosis
- 6.2.4 Lumbar vertebral syndrome (LVS)
- 6.2.5 Micturition disorders
- 6.2.6 Menstrual disorders
- 6.2.7 Uterine prolapse
- 6.2.8 Scar tape

6.2.1 Thoracic outlet syndrome (TOS)

Definition

Thoracic outlet syndrome is a collective term for all disorders in which nerves (brachial plexus) or blood vessels of the upper thorax are damaged or impaired through pressure.

Aim

Muscle applications to the compressed musculature relieve pressure on the brachial plexus.

Application

The following muscles are treated with a tonus-reducing application (■ Fig. 6.16a-d):

- anterior scalene
- posterior scalene
- pectoralis minor
- biceps brachii

Memo

Application: Muscle technique

Cutting technique: I- and Y-tape



■ Fig. 6.17.
Blue I-tape



■ Fig. 6.18.
Blue Y-tape

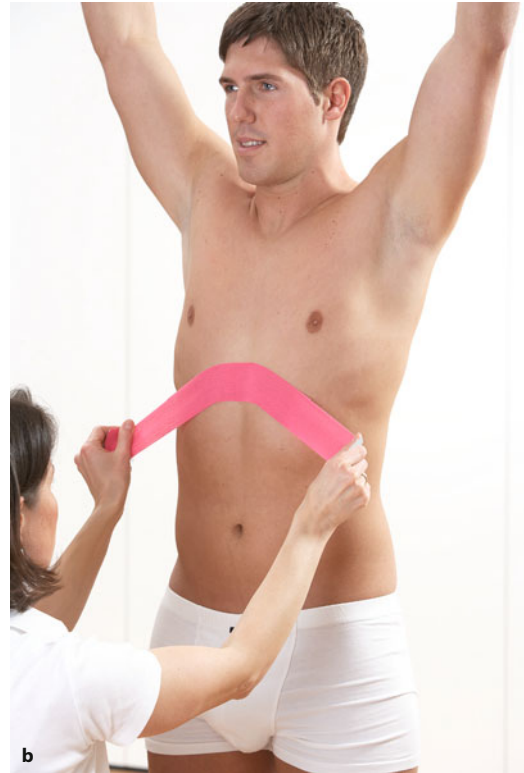
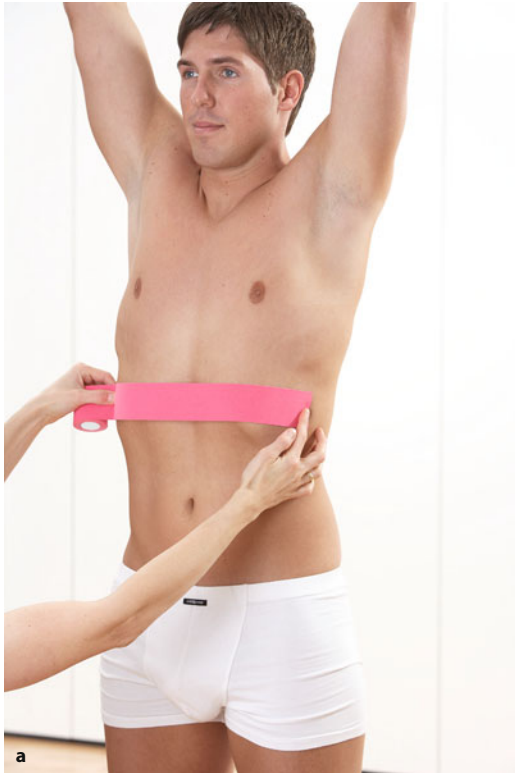

Fig. 6.19 a-d. Asthma: **a-b Application Part 1.** **a** Measure the tape from the center of the left and right lateral thorax, **b** base anchored to xiphoid process. Application is affixed simultaneously along the right

and left costal arch with maximum tension. **c-d Application Part 2.** **c** Base on T12. Application is affixed simultaneously along the right and left costal arch with maximum tension, **d** completed application

6.2.2 Asthma

Definition

Asthma is a chronic inflammatory disease of the airways. It is characterized by an over-reaction of the mucous membrane with swelling and formation of viscous mucus.

The etiology is still unknown.

Aim

A ligament application to the lower costal arch brings relief to the diaphragm.

Application

- **Part 1:** The tape is measured from the center of the right and left lateral thorax at the height of the diaphragm up to the ventral axillary fold. The trunk is in the resting position (■ Fig. 6.19a). The base of Tape 1 is affixed centrally to the xiphoid process in the resting position. During the application, the patient's arms are maximally flexed and he or she is requested to breathe in deeply. The tape is affixed simultaneously along the right and left costal arch with maximum tension. The tape ends are affixed without tension (■ Fig. 6.19b).
- **Part 2:** Tape 2 is measured from the cervical spine to the dorsal axillary fold. The base of Tape 2 is affixed centrally to the twelfth thoracic vertebra (T12). The patient is again in the position of maximum arm flexion and breathing in. Using the same application technique as described for Tape 1, the tape is affixed along the costal arch. The tape ends are affixed without tension (■ Fig. 6.19c).
- Fig. 6.19d shows the completed application.

Memo

Application: Ligament technique

Cutting technique: I-tape



■ Fig. 6.20. Red I-tape

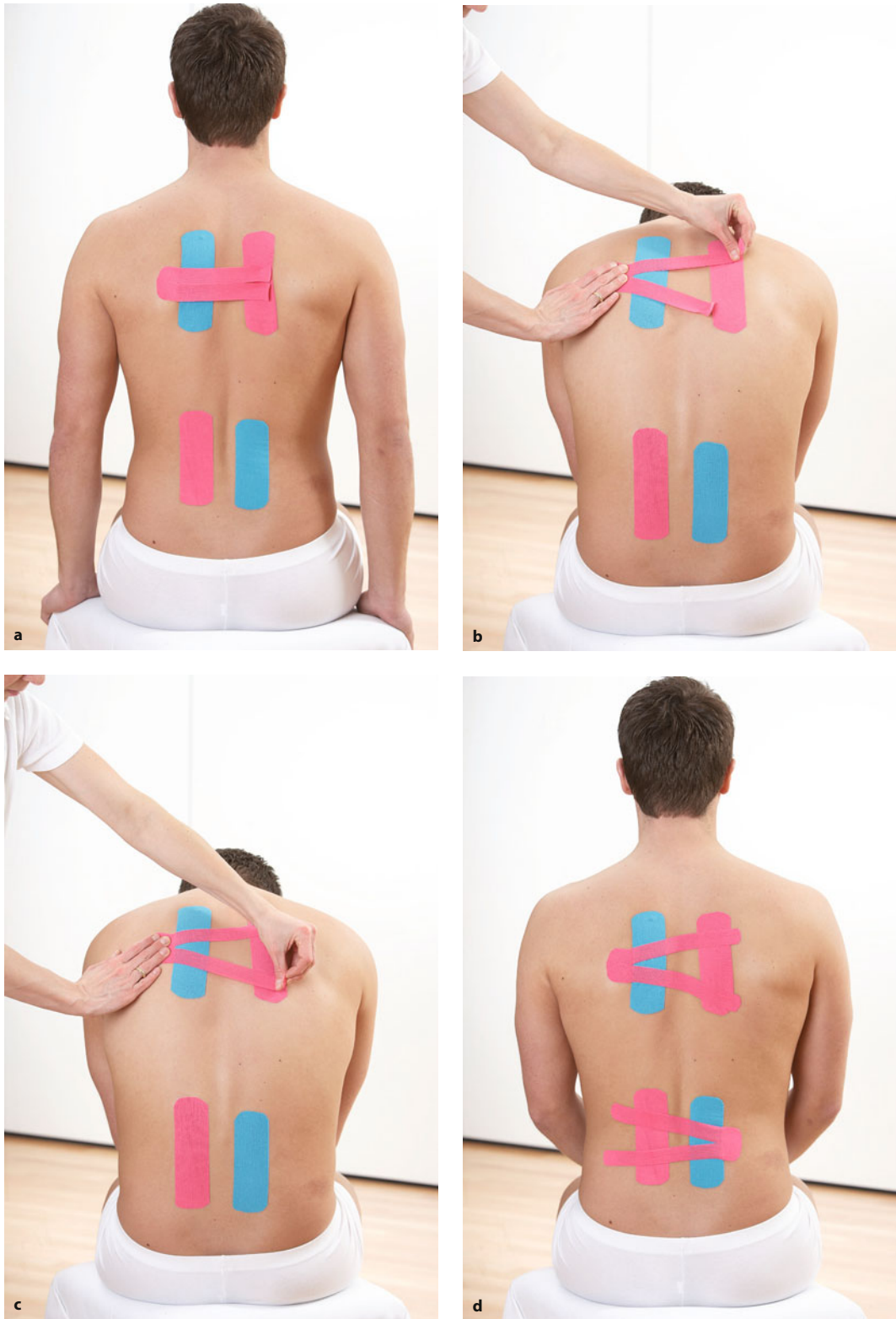


Fig. 6.21 a-d. Scoliosis: **a** Completed muscle application: tonus-reducing muscle application to the lumbar spine right and tonus-increasing muscle application to the cervical spine left, as well as tonus-increasing muscle applications to the cervical spine right and lumbar

spine left. First base position for the functional correction, **b** functional correction of the cervical spine; upper tape tail affixed over the bony structure **c** functional correction of the cervical spine; lower tape tail affixed over the bony structure, **d** completed application

6.2.3 Scoliosis

Definition

Scoliosis is a sideways curvature of the spine with concomitant rotation of the vertebrae, whereby the spine generally forms curves to enable the body to maintain equilibrium.

Scoliosis ranks among the **growth deformities**.

The cause is unknown in most cases (see functional correction in scoliosis, ► Chap. 5.1.2).

Scoliotic malposition (less than a 15° Cobb angle) without rotation should be treated using this application.

Progressive scoliosis greater than a 20° Cobb angle must be treated individually and, if necessary, with an additional spinal corset.

Correction

In this example, a convexity of the thoracic vertebrae to the right is corrected with muscle applications. A tonus-increasing muscle application is affixed to the convex side and a tonus-reducing application to the concave side. The thoracic spine is corrected to the left using an additional functional correction.

The convexity of the lumbar vertebrae to the left is toned with a muscle application to the left side and detoned with an application to the right side. The lumbar spine is corrected to the right using an additional functional correction.

Aim

By means of a combination of muscle applications and functional correction, an improvement in the equilibrium mechanics of the body is achieved.

Application

- **Part 1:** The **autochthonous back muscles** are treated on the concave side with a tonus-reducing muscle application

The autochthonous back muscles are treated on the convex side with a tonus-increasing muscle application.

The tape is measured along the length of the vertebral arch with the trunk flexed. The bases of the tonus reducing muscle applications lie caudally to the right of the lumbar spine and to the left of the cervical spine respectively. The patient is in the erect position when the bases are affixed, and is then requested to bend for-

wards. The base is anchored paravertebrally and the tape affixed over the muscles. The tape ends are affixed without tension.

The bases of the tonus-increasing muscle applications lie cranially to the left of the lumbar spine and to the right of the cervical spine respectively. The application is carried out as previously described (■ Fig. 6.21a).

- **Part 2:** For the functional correction of the lumbar spine, the base lies to the right next to the lumbar spine; for the cervical spine, the base lies to the left next to the cervical spine. The application is carried out as described in ► Chap. 5.1.2 (■ Fig. 6.21b-c). ■ Fig. 6.21d shows the completed application for the treatment of scoliosis.

Memo

Application: Muscle technique, functional corrective technique

Cutting technique: I- and Y-tape



■ Fig. 6.22.
Red Y-tape



■ Fig. 6.23.
Blue I-tape



■ Fig. 6.24.
Red I-tape

! Tip

The use of the **fascia technique** instead of the functional correction is also possible. Accordingly, the base lies on the other side and is moved across without being manually anchored. Depending on the diagnostic findings, the therapist must decide which application is more effective for the patient. Generally, the skin stimulation and therefore sensory stimulus is stronger with a functional correction.

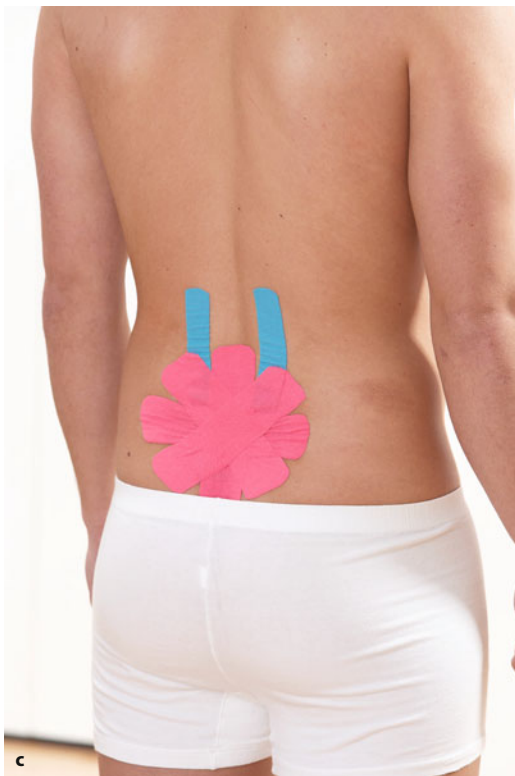
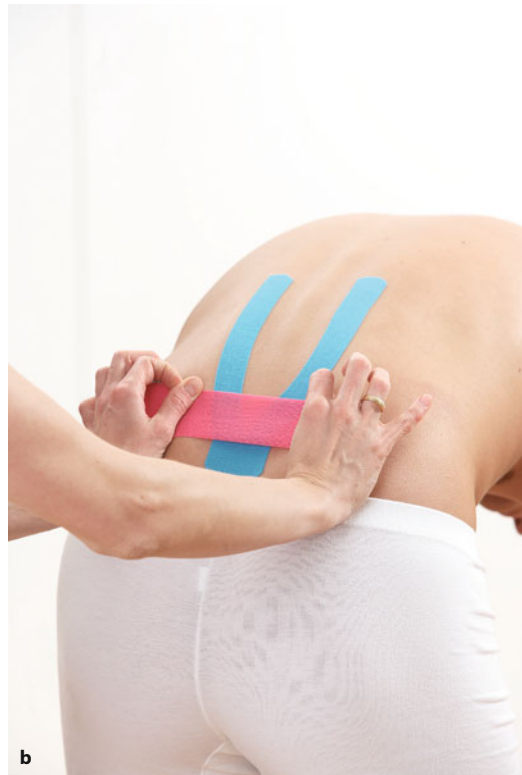
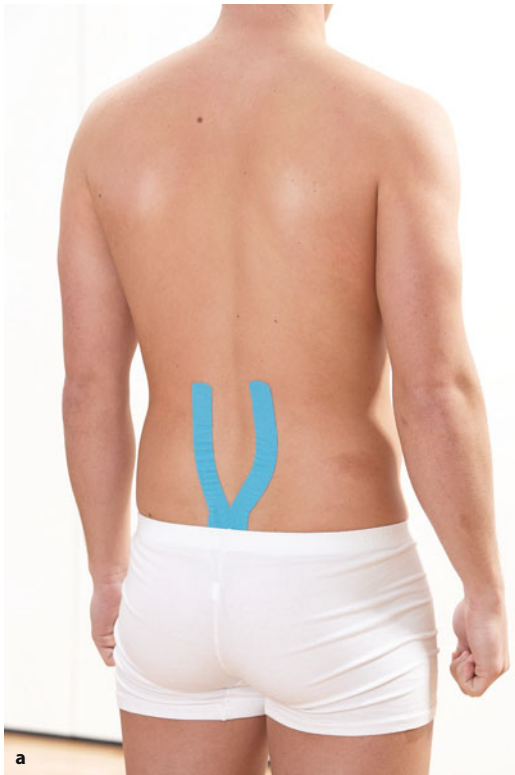Fig. 6.25 a-c. LVS: **Application Part 1.** **a** Completed tonus-reducing muscle application. **b-c Application Part 2.** **b** Using the ligament technique, the first tape strip of the spacetape is affixed transversely en bloc over the spine on the pain point, **c** completed application

6.2.4 Lumbar vertebral syndrome (LVS)

Definition

LVS is a collective term for pain originating in the lumbar spine.

Causes

Degenerative changes (e.g. herniated disk, spondylarthrititis), malformations, inflammatory diseases, generalized skeletal diseases (e.g. trauma, tumors, and defects that are not caused by injuries).

Aim

Relief of pain is achieved by means of a muscle application to the autochthonous back muscles and a spacetape applied to the pain point.

Application

- **Part 1:** The tape is measured with the trunk flexed. The base of the muscle application is affixed to the sacrum with the patient in the erect position. The individual tape tails are affixed paravertebrally to the lumbar spine with the trunk flexed. The tape ends are affixed without tension (■ Fig. 6.13a).
- **Part 2:** A 15 cm length of tape is always used for the spacetape. Each of the tape strips is applied en bloc with maximum tension and the trunk flexed. The first tape strip is affixed transversely across the spine on the pain point and the second tape strip is affixed longitudinally along the spine on the pain point. The application technique is repeated for the two diagonal tape strips. All the tape ends are affixed without tension (■ Fig. 6.13b-c).

Memo

Application: Muscle technique, ligament technique

Cutting technique: I- and Y-tape



■ Fig. 6.26.
Blue Y-tape



■ Fig. 6.27.
Red I-tape

! Tip

Each segment of the spine can be taped individually, e.g. with a tonus-reducing lumbar spine application and, at the same time, a tonus-increasing application to the thoracic spine. It is also possible, however, to use a complete muscle application to the autochthonous back muscles from L5 to C1.

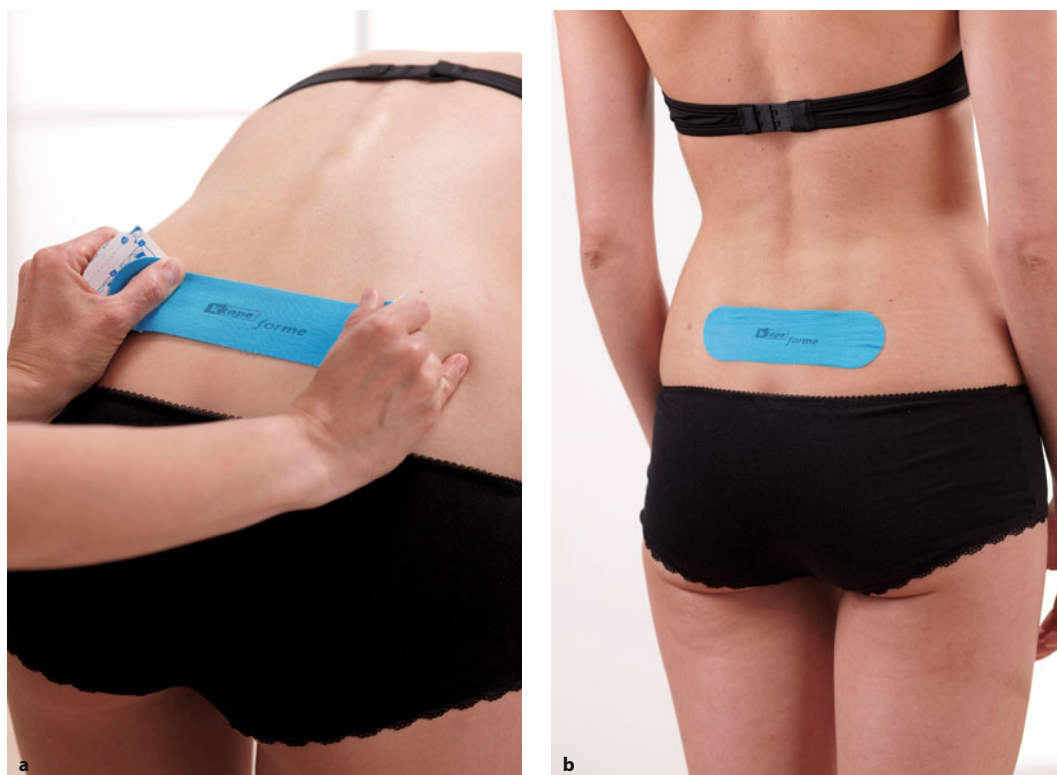

Fig. 6.28 a-b. Micturition disorders: **a** The patient stands with the trunk flexed. The tape is affixed en bloc over S1 with maximum tension, **b** completed ligament application

6.2.5 Micturition disorders

Definition

A disorder of micturition is the loss or non-acquisition of the ability to retain urine and eliminate it in a suitable place at a self-determined time.

Causes

The causes may vary considerably, e.g. the result of infections of the lower urinary tract or narrowing of the urethra due to prostate enlargement, weakness of the pelvic floor muscles and ligaments, traumatic damage to the external urethral sphincter during surgery or through accidents, neurological disease, and paraplegia.

Aim

An improvement in bladder function can be achieved by means of a ligament application over **CTM-genital zone** and over **viscerotome S1**, the segment to which the genital organs belong.

Application

In general, approximately 15 cm of tape are required for a ligament application over the spine. The patient stands with the trunk flexed. The tape strip is affixed en bloc over S1 with maximum tension. The tape ends are affixed without tension (■ Fig. 6.28a-b).

Memo

Application: Ligament technique

Cutting technique: I-tape



■ Fig. 6.29. Blue I-tape

! Tip

A high degree of success is achieved with this tape application in patients with multiple sclerosis, as well as those with paraplegia.

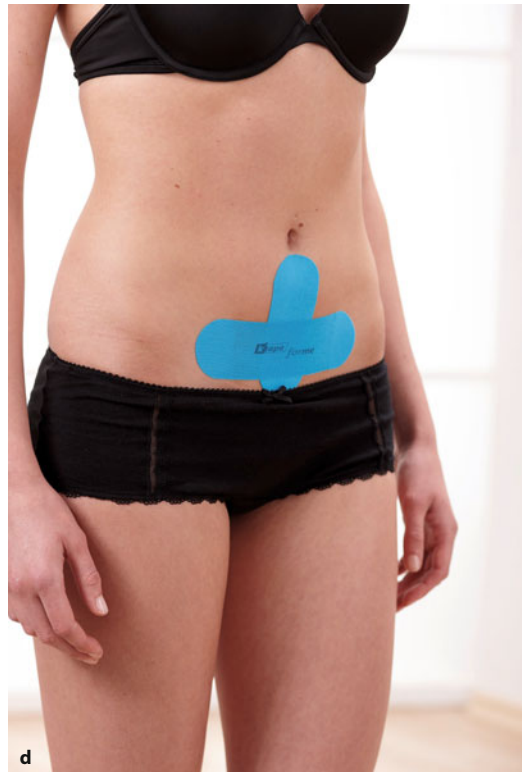
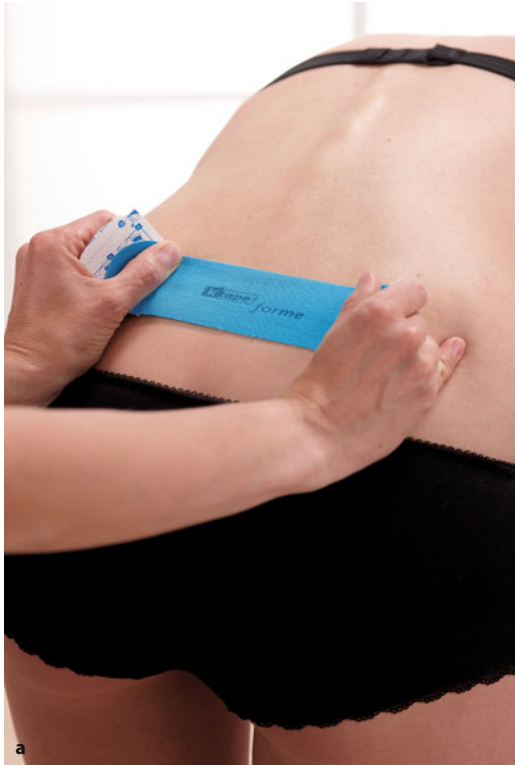
Fig. 6.30 a-d. Menstrual disorders: **Application Part 1.** **a** The patient stands with the trunk flexed. The tape strip is affixed en bloc over S1 with maximum tension, **b-d Application Part 2.** **b** The patient is standing with the trunk extended. The vertical tape strip is affixed

en bloc above the symphysis with maximum tension, **c** the horizontal I tape strip is likewise affixed en bloc above the symphysis with maximum tension, **d** completed ventral application

6.2.6 Menstrual disorders

Definition

Menstrual disorders include cramp-like, drawing pains in the lower abdomen prior to or during menstruation. If the pain is severe, it is referred to as **dysmenorrhea**.

The causes may be hormonal changes, psychic factors, as well as organic diseases.

Aim

Relaxation in the lower abdomen is achieved using ligament applications over the CTM-genital zone and over the viscerotome S1 of the genital organs, as well as a ventral application over the uterus.

Application

- **Part 1:** In general, approximately 15 cm of tape are required for the dorsal ligament application over the spine. The patient stands with the trunk flexed. The tape strip is affixed en bloc over S1 with maximum tension. The tape ends are affixed without tension (■ Fig. 6.30a).
 - **Part 2:** For the ventral ligament application over the symphysis, 10 cm tape vertically and 15 cm horizontally are generally required. The patient is standing with the trunk extended. The vertical tape strip is affixed en bloc above the symphysis with maximum tension (■ Fig. 6.30b). The horizontal tape strip is likewise affixed en bloc above the symphysis with maximum tension (■ Fig. 6.30c). All tape ends are affixed without tension.
- Fig. 6.30d shows the completed application of the tape.

Memo

Application: Ligament technique

Cutting technique: I-tape



■ Fig. 6.31. Blue I-tape

! Tip

The application may bring about improved or increased blood flow. In **premenstrual syndrome (PMS)**, the taping should be carried out prior to the onset of symptoms.



Fig. 6.32 a-c. Uterine prolapse: **a** horizontal tape strip, affix base above the pubic symphysis (hair boundary), **b** completed vertical fascia correction, **c** completed horizontal fascia correction

6.2.7 Uterine prolapse

Definition

Uterine prolapse occurs due to a weakness of the **pelvic floor muscles** so that they can no longer hold the uterus, and often the urinary bladder, in position.

There are various degrees of **uterine prolapse** up to complete prolapse, where the entire uterus is outside the vagina and the cervix protrudes from the body.

Aim

Lower abdominal relief is achieved by means of a dorsal ligament technique over the CTM-genital zone, over the viscerotome S1 of the genital organs, and by means of a fascia correction to the peritoneum in a cranial direction.

Application

- **Part 1:** The dorsal ligament technique over the spine generally requires 15 cm of tape. The patient stands with the trunk flexed. The tape strip is affixed en bloc over S1 with maximum tension. The tape ends are affixed without tension (■ Fig. 6.30a).
- **Part 2:** For the ventral fascia correction of the peritoneum, 15 cm tape horizontally and 10 cm vertically are generally required. The patient is supine with the trunk extended. The base of the vertical tape is affixed to the pubic symphysis (hair boundary). With a fascia correction the tape strip is pulled upwards towards the umbili-

cus with 75% tension (■ Fig. 6.32a-b). The horizontal tape strip is affixed with a central base over the pubic symphysis. The right and left tape tails are simultaneously pulled in a cranial direction with maximum tension and affixed to form a semicircular arch. All tape ends are affixed without tension (■ Fig. 6.32c).

Memo

Application: Ligament technique, fascia correction

Cutting technique: I-tape



■ Fig. 6.33. Blue I-tape



Tip

To support the therapy, concurrent pelvic floor muscle training is important.

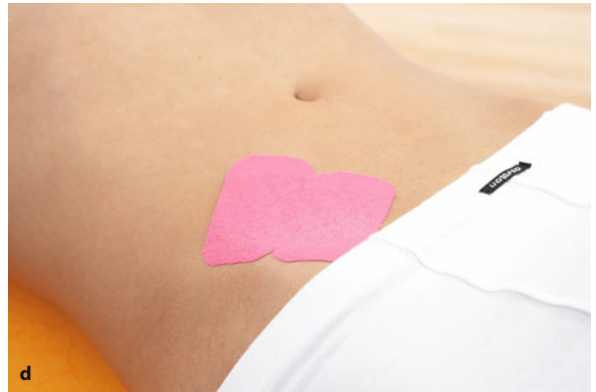
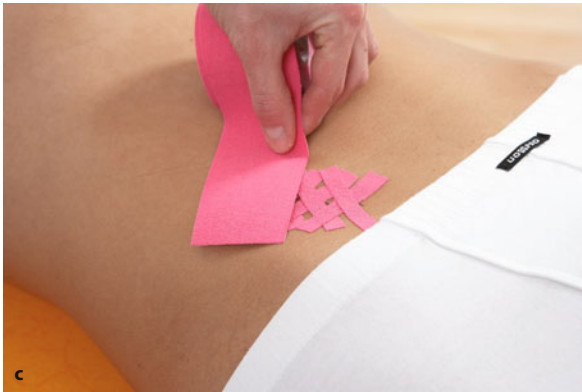
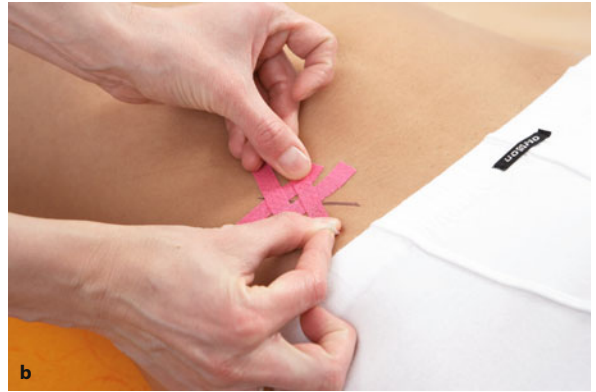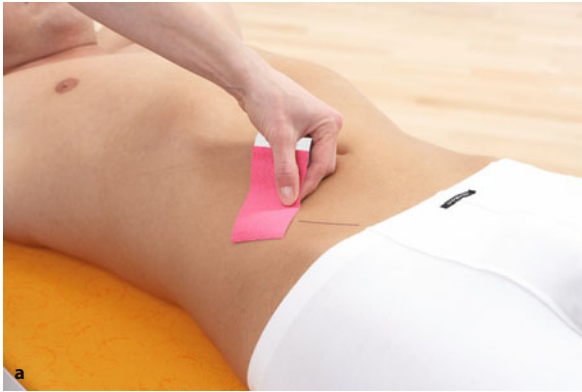Fig. 6.34 a-d. Scar tape: **a-b Application Part 1.** **a** The tape strips are measured so that there is a fingerbreadth to the right and to the left of the scar, **b** quartered tape strips are affixed en bloc with maxi-

mum tension, crisscrossed at 45° to the scar. **c-d Application Part 2.** **c** The tape length for the covering tape corresponds to the width of the scar tape that has been affixed, **d** completed application

6.2.8 Scar tape

Definition

Severe burns, surgical interventions, and accidents give rise to **scar formation** and sometime to undesirable cicatrization.

There is excessive formation of fibrous connective tissue during the healing process. A distinction is made between **hypertrophic** and **keloid scars**, both of which are raised and red and may be accompanied by itching; only keloid scars exceed the original wound edges and may continue to expand, sometimes over many years.

Aim

The ligament technique prevents the formation of altered **scar tissue** and brings about a suppression of scarring.

Application

- **Part 1:** The tape is measured so that there is a finger width to the right and to the left of the scar. The tape is quartered across its width. The narrow tape strips are each affixed en bloc with maximum tension, criss-crossed at 45° to the scar. This application is used over the entire length of the scar with a slight gap between the strips (■ Fig. 6.34a-b).
- **Part 2:** The tape length for the covering strip corresponds to the width of the scar tape that has been affixed. Tape strips must be affixed side by side across the scar with maximum tension until the scar is completely covered (■ Fig. 6.34c-d).

Memo

Application: Ligament technique

Cutting technique: I-tape



■ Fig. 6.35. Red I-tape

! Tip

Prior to treatment with K-Tape, the stitches must have been removed and the scar should be fully healed.

If the **mobilization stimulus** to the scar needs to be gentler, the covering tape over the scar tape may be applied without tension.

Instead of the application described above, it is also possible to apply a Cross-Tape to the scar.

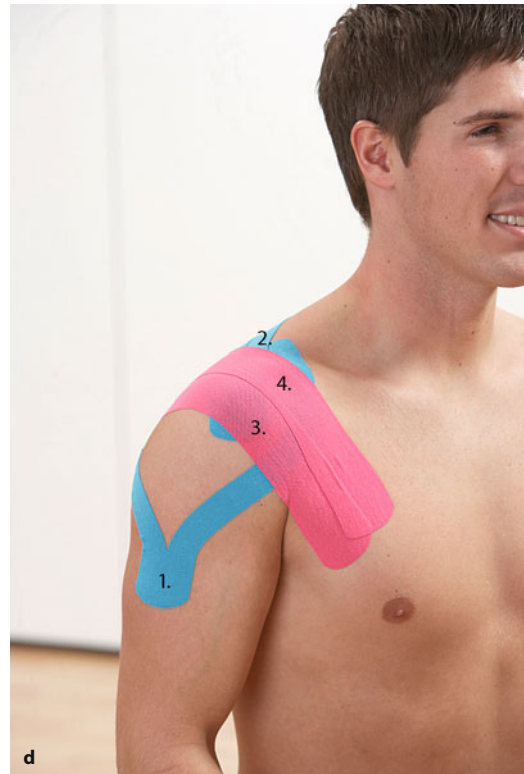
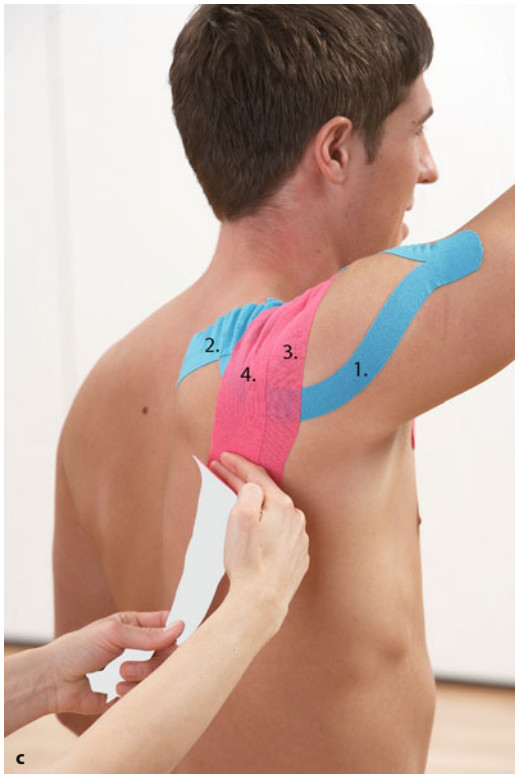
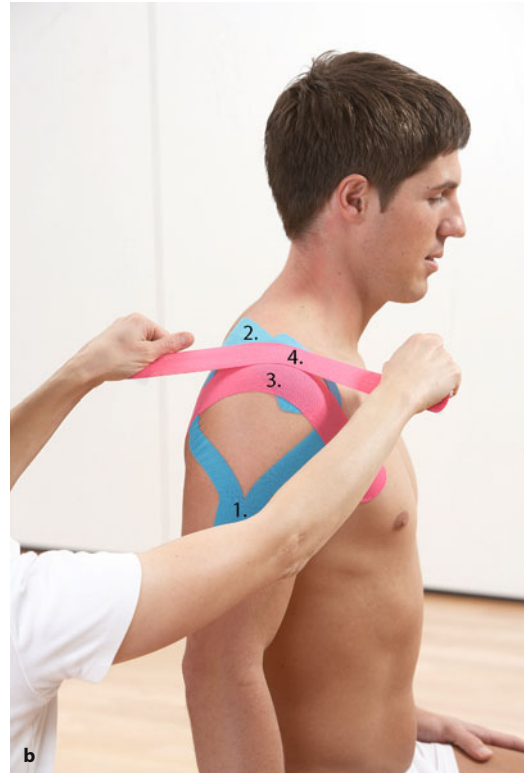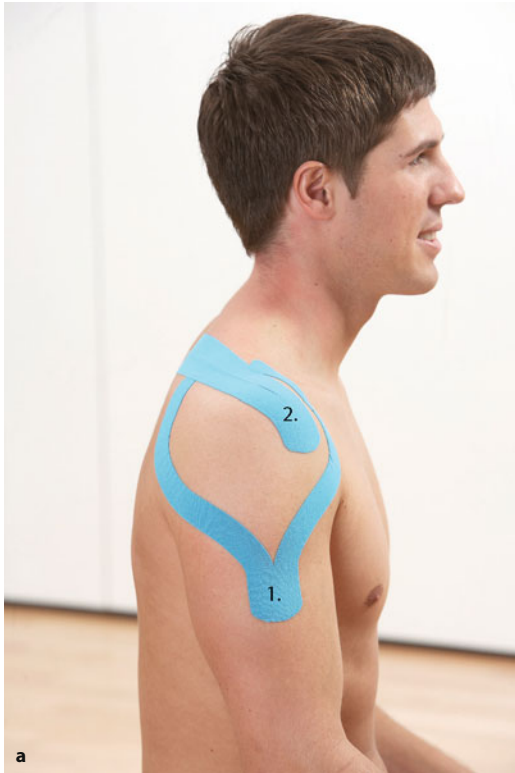Fig. 6.36 a-d. Impingement syndrome: **a Application Part 1.** **a** Completed tonus-reducing muscle applications to the supraspinatus and deltoid muscles. **b Application Part 2a.** **b** Completed fascia

correction with the first tape strip and the initial application of the second tape strip. **c Application Part 2b.** **c** Application of dorsal tension-free tape ends, **d** completed application

6.3 Upper extremities

- 6.3.1 Impingement syndrome
- 6.3.2 Biceps tendonitis
- 6.3.3 Epycondylitis
- 6.3.4 Carpal tunnel syndrome
- 6.3.5 Wrist stabilization
- 6.3.6 Finger contusion

6.3.1 Impingement syndrome

Definition

Impingement syndrome describes a narrowing of the sub-acromial space due to erosion of the shoulder joint or unfavorable variations in the shape of the acromion (subacromial spurs).

Aim

Muscle and fascia correction leads to improvement in muscle coordination as well as improvement in **centering the head of the humerus**.

Application

- **Part 1:** Tonus-reducing applications are affixed to the deltoid and supraspinatus muscles. The patient sits. The base for the deltoid muscles lies on the origin of the deltoid tuberosity. The arm is extended for the ventral tape application and flexed for the dorsal tape application. The base is manually anchored with skin displacement and the tape tails are affixed round the muscle belly to the acromion.
The base for the tape application to the supraspinatus muscle lies on the origin of the muscle on the greater tuberosity. The arm is adducted and rotated inwards. The base is manually anchored with skin displacement and the tape affixed up to the supraspinatus fossa (■ Fig. 6.36a).
- **Part 2a:** The head of the humerus is corrected in a dorsal direction by means of a fascia application. The tape is applied with both hands and maximum tension so that 1/3 lies on the acromion and 2/3 caudally to the

acromion, with only the center of the tape initially affixed. The ventral base is affixed first. Then, with a manual correction to the head of the humerus and an additional fascia correction with the tape, the dorsal base is anchored. The ventral tape end is affixed without tension and the arm extended; the dorsal tape end is affixed with the arm flexed (■ Fig. 6.36b).

- **Part 2b:** Tape 2 is affixed with maximum tension to the acromioclavicular (AC) joint, with only the center of the tape initially affixed. As for Tape 1 Part 2a, the ventral base is affixed first. Then, with manual correction to the trunk to the erect position and an additional fascia correction with the tape, the dorsal base is anchored. The ventral tape end is affixed without tension and the arm extended; the dorsal tape end is affixed with the arm flexed (■ Fig. 6.36c).

■ Fig. 6.36d shows the completed application for impingement syndrome.

Memo

Application: Muscle technique, functional corrective technique using the fascia technique

Cutting technique: I- and Y-tape



■ Fig. 6.37.
Blue Y-tape



■ Fig. 6.38.
Blue I-tape



■ Fig. 6.39.
Red I-tape

! Tip

If there is pain when the shoulder is flexed or when the biceps ligament is palpated, an additional muscle application to the biceps brachii muscle may be necessary (► Chap. 6.3.2).

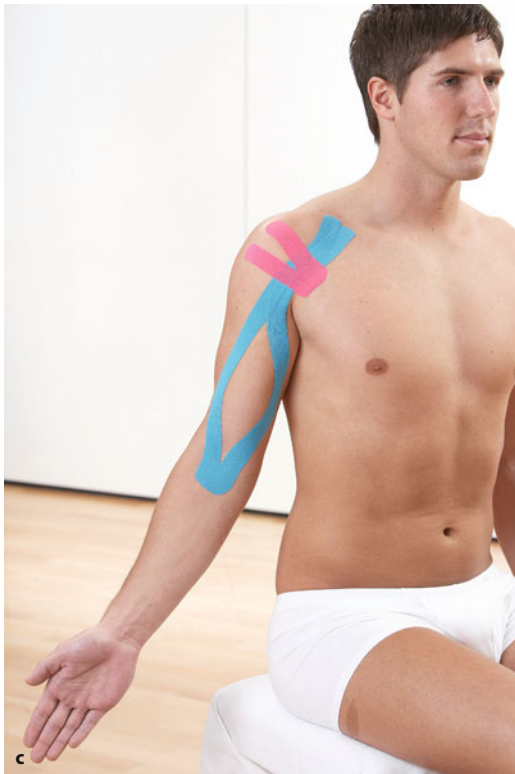
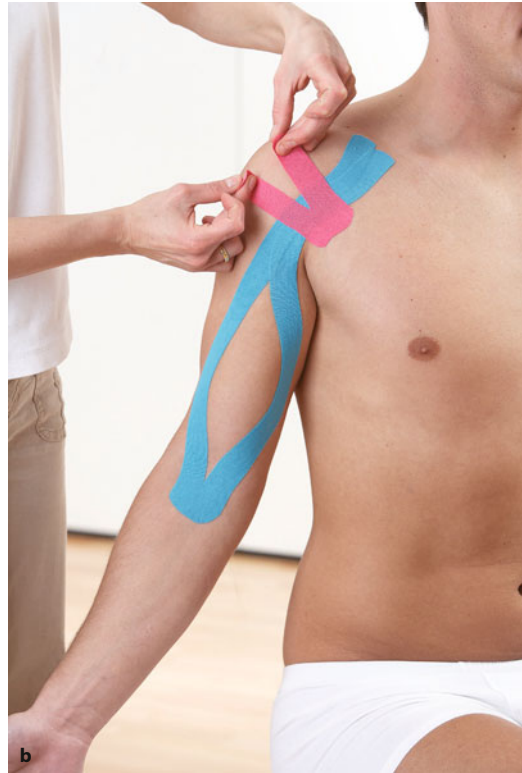
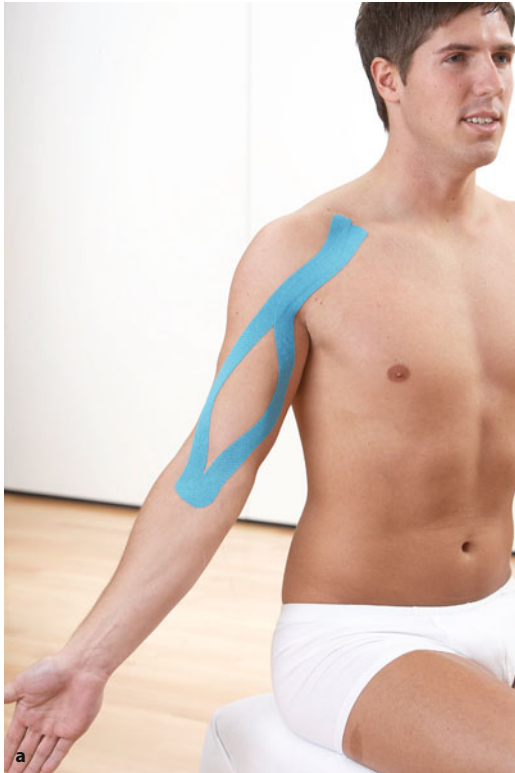Fig. 6.40 a-c. Biceps tendonitis: **a Application Part 1.** **a** Completed tonus-reducing muscle application to the biceps brachii muscle. **b Application Part 2.** **b** Fascia application across the pain point. The base lies in front of the pain point, **c** completed application

6.3.2 Biceps tendonitis

Definition

Biceps tendonitis is caused by strain of the biceps tendon.

In the following example, a tonus-reducing muscle application to the biceps brachii is affixed only to the short head because the adducting component in the short head increases the malposition of the shoulder in protraction. The **muscle imbalance** »dorsal too weak« and »ventral too contracted« is intensified and leads to increased muscle strain.

Aim

A tonus-reducing muscle application combined with a fascia correction brings relief to the **primary pain point**.

Application

- **Part 1:** The patient sits in the resting position. The base of the tape is affixed below the inner side of the elbow. The base is anchored with skin displacement and the two tail tapes encompass the muscle belly then run parallel along the anterior margin of the deltoid muscle and end at the coracoid process. The tape ends are affixed without tension (■ Fig. 6.40a).
- **Part 2:** The base of the fascia correction lies in front of the pain point. The arm is extended. The fascia is pulled transversely up to the course of the muscle fibers and, in this example, always in a dorsal direction to avoid impaction of the biceps tendon. The tape ends are affixed without tension (■ Fig. 6.40b).
■ Fig. 6.40c shows the completed application of the two tapes.

Memo

Application: Muscle technique, fascia technique

Cutting technique: Y-tape



■ Fig. 6.41.
Blue Y-tape



■ Fig. 6.42.
Red Y-tape

! Tip

For the treatment of the short head of the muscle, an I-technique is also possible. The base lies on the inner elbow. The tape is affixed over the biceps brachii muscle belly and continues along the anterior margin of the deltoid muscle up to the coracoid process.

If the biceps brachii and the long and short head are to be treated simultaneously, a Y-technique is used. The application is affixed as described in Part 1, but the ends of the Y-tape tails run to the coracoid process and supraglenoid tubercle respectively.

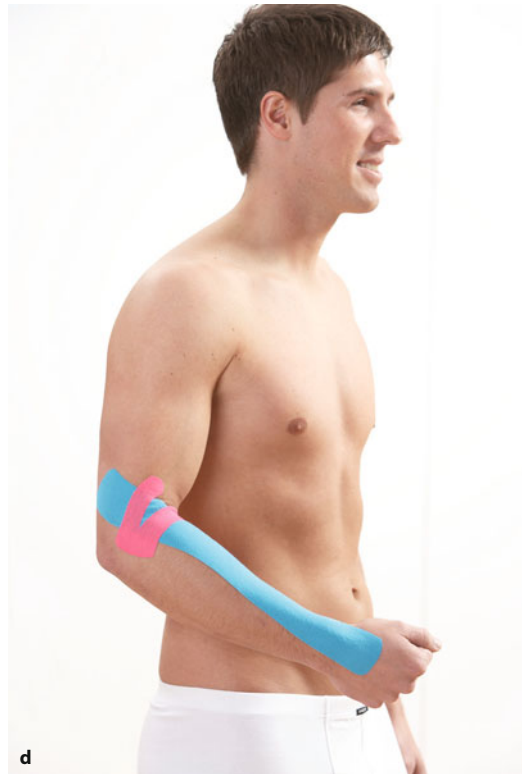
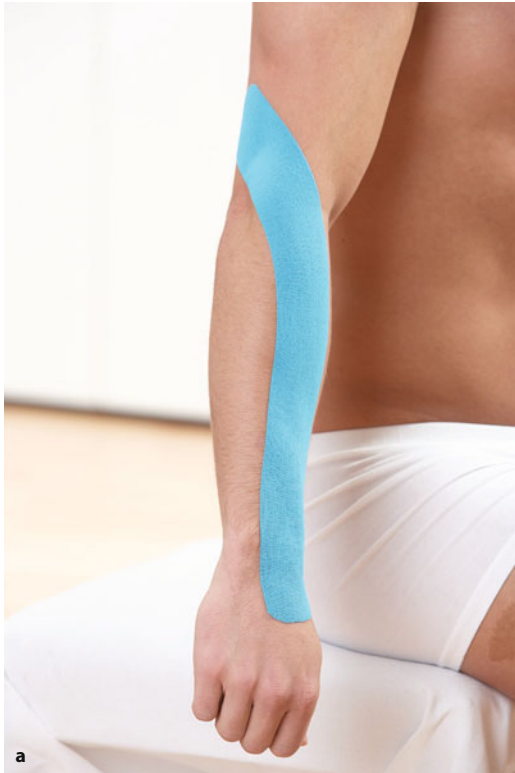
Fig. 6.43 a-d. Epicondylitis: **a Application Part 1.** **a** Completed muscle application to forearm extensor muscles. **b-d Application Part 2.** **b** The first tape strip is affixed en bloc with maximum tension across the pain point, **c** the second tape strip is affixed at 90° using the same

method. Completed ligament application (spacetape), **d** additional application possibilities: fascia pull in free direction. The base for the fascia correction lies in front of the pain point

6.3.3 Epicondylitis

Definition

In **epicondylitis** there is overstraining of the forearm muscles giving rise to tearing at the tendon insertion of the medial or lateral condyle. The strain is caused by extreme or repetitive movements, e.g. using a keyboard/mouse, faulty posture at work or in leisure activities, as well as faulty technique in racquet sports and other ball-hitting sports.

There are two forms of epicondylitis: **radiohumeral epicondylitis** (tennis elbow) and **humero-ulnar epicondylitis** (golfer's elbow).

Aim

A combination of a tonus-reducing muscle application to the extensor carpi radialis longus and brevis muscles and a ligament technique brings relief to the muscles and the pain point.

Application

- **Part 1:** The forearm extensors are measured with palm flexion, pronation, and elbow extension. The base lies on the back of the hand in the region of the second and third finger ray. Place the tape over the extensor carpi radialis longus and brevis. The tape ends are affixed without tension (■ Fig. 6.43a).
- **Part 2:** The arm is positioned with slight elbow flexion. Affix the first tape strip en bloc with maximum tension across the pain point. The second tape strip is affixed at 90° using the same method. Depending on the degree of pain, it is possible to apply a third and a fourth tape. The tape ends are affixed without tension (■ Fig. 6.43b-c).

Additional application possibilities for Part 2: The arm is positioned with slight elbow flexion. Manually check for the best fascia displaceability. The fascia is corrected in the free direction. The base of the fascia correction lies in front of the pain point. The fascia is pulled towards the free direction. The tape ends are affixed without tension (■ Fig. 6.43d).

Memo

Application: Muscle technique, ligament technique (spacetape), fascia correction

Cutting technique: I- and Y-tape



■ Fig. 6.44.
Blue I-tape



■ Fig. 6.45.
Red Y-tape



■ Fig. 6.46.
Red I-tape

! Tip

Due to the maximum tape tension and the application of several tape strips one on top of the other, the spacetape has a deeper effect on the connective tissue as a fascia technique and is therefore suitable for chronic epicondylitis.



Fig. 6.47 a-d. Carpal tunnel syndrome: **a-b Application Part 1.** **a** The muscle application to the forearm flexors is measured, **b** the base lies on the wrist. The base is anchored with skin displacement and the

tape affixed with the muscles elongated. **c-d Application Part 2.** **c** Hand in resting position. The tape strip is affixed en bloc with maximum tension over the flexor retinaculum, **d** completed application

6.3.4 Carpal tunnel syndrome

Definition

Carpal tunnel syndrome (CTS) or median nerve compression syndrome describes a compression of the median nerve in the region of the wrist. Mechanical overtraining of the forearm flexors, infection, or systemic diseases, e.g. diabetes mellitus, acromegaly, hypothyroidism, and the concomitant **tissue swelling** causes congestion under the flexor retinaculum and as a result, **compression syndrome** of the median nerve.

Aim

A combined muscle and ligament application relieves the muscles and the median nerve, which passes under the flexor retinaculum.

Application

- **Part 1:** The tape is measured with dorsal and elbow extension. The tape length reaches from the wrist up to the medial epicondyle of the humerus. The base lies on the wrist. Anchor the base with skin displacement and affix the tape over the course of the muscle (■ Fig. 6.47a-b).
- **Part 2:** The tape strip is measured so that it covers the wrist width plus a fingerbreadth right and left. The hand is in the resting position. The tape strip is applied en bloc with maximum tension over the flexor retinaculum. Ensure that the tape ends remain open dorsally. To avoid compression of the ulna and radius, maximum tension is applied only over the retinaculum. The tape ends are affixed without tension (■ Fig. 6.47c-d).

Memo

Application: Muscle technique, ligament technique

Cutting technique: I-tape



■ Fig. 6.48.
Red I-tape



■ Fig. 6.49.
Blue I-tape

! Tip

The pronator teres muscle is an additional source of muscle congestion for the median nerve and should also be detoned if problems arise here.

Because of the segmental innervation (myotome) C7/T1 of the forearm, a spacetape applied here is effective.



Fig. 6.50 a-d. Wrist stabilization: **a** The tape strip is measured for the wrist width plus a fingerbreadth right and left, **b** Affix the tape en bloc with maximum tension over the extensor retinaculum, **c** Affix

the second tape to the flexor retinaculum using the same method, **d** completed application

6.3.5 Wrist stabilization

Definition

Overstrain causes lack of stability in the wrist.

Aim

The wrist is stabilized by means of ventral and dorsal ligament applications to the retinacula.

Application

The tape strip is measured so that it covers the wrist width plus a fingerbreadth right and left. The tape is affixed en bloc with maximum tension over the extensor retinaculum (■ Fig. 6.50a-b). The second tape is affixed to the flexor retinaculum using the same method. Ensure that the tape ends remain open dorsally. To avoid compression of the ulna and radius, maximum tension is applied only over the retinaculum. All tape ends are affixed without tension.

■ Fig. 6.50d shows the completed application for wrist stabilization.

Memo

Application: Ligament technique

Cutting technique: I-tape



■ Fig. 6.51.
Red I-tape



■ Fig. 6.52.
Blue I-tape

! Tip

Ensure that **no circular application** is affixed; otherwise there is **compression** of the radius and ulna. When applying maximum tape tension, there should be no preexisting swelling in the wrist; otherwise the tape obstructs **lymphatic drainage**.

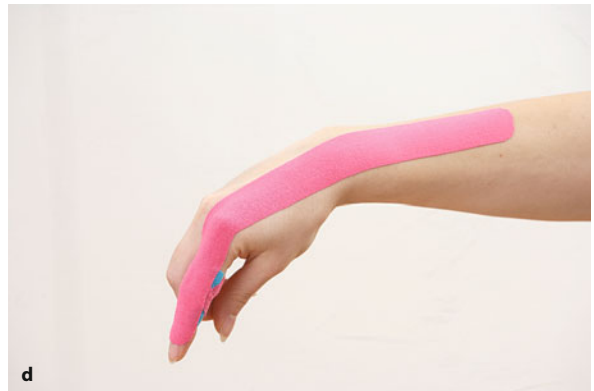
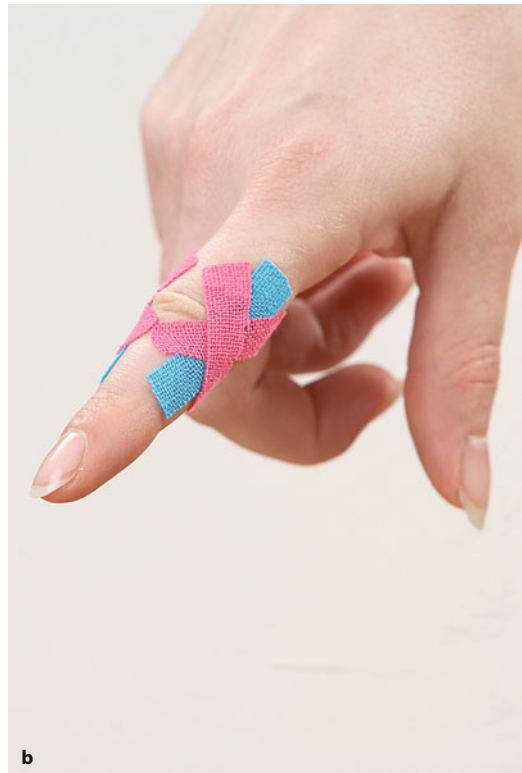
Fig. 6.53 a-d. Finger contusion: **a-b Application Part 1.** **a** Completed ligament application across the collateral ligament and joint capsule, **b** completed ligament applications on both sides. **c-d Appli-**

cation Part 2. **c** Anchor base on the origin and affix the tape over the muscle up to the insertion, **d** completed application

6.3.6 Finger contusion

Cause

In **finger contusion**, direct or blunt external impact to a joint gives rise to edema and hematoma with possible capsule and/or ligament hyperextension.

Aim

Stabilization of the joint is achieved by a ligament application over the capsule and ligament structure and a muscle application.

This example illustrates finger contusion of the index finger and a tonus-increasing muscle application to the extensor indicis muscle.

Application

- **Part 1:** The joint is in the resting position. The tape measurement corresponds to the joint width plus one fingerbreadth. The quartered tape strip is affixed en bloc with maximum tension over the collateral ligament of the joint. The second and third quartered tape strips are affixed to the lateral joint capsule using the same method, offset by 45°. All tape ends are affixed without tension. The tape is applied to both sides of the finger (■ Fig. 6.53a-b).
- **Part 2:** The tape strip for the muscle application to the extensor indicis is measured from the distal third of the forearm up to the end phalanx of the index finger with the muscle extended. The base lies on the origin of the muscle, and with the base anchored, the tape is affixed over the entire length of the muscle to its insertion. The tape ends are affixed without tension (■ Fig. 6.53c-d).

Memo

Application: Ligament application, muscle application

Cutting technique: I-tape



■ Fig. 6.54.
Red I-tape



■ Fig. 6.55.
Blue I-Tape



Tip

For sporting activities, the finger should be anchored to the adjacent finger using normal, non-elastic tape.

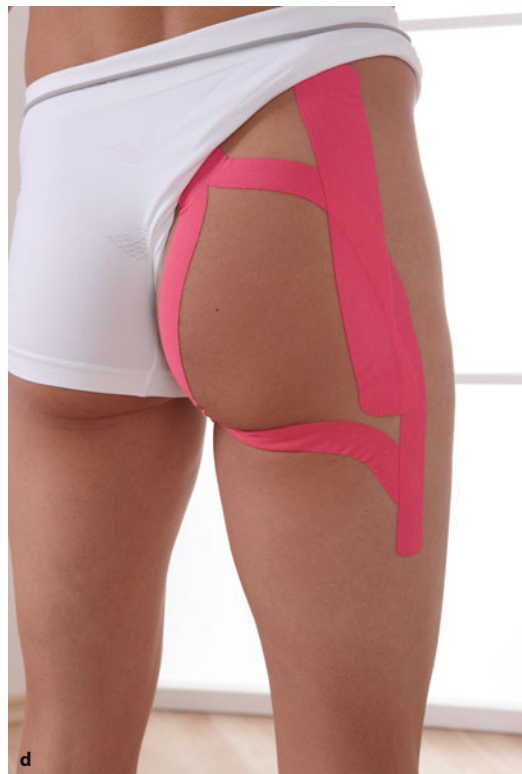
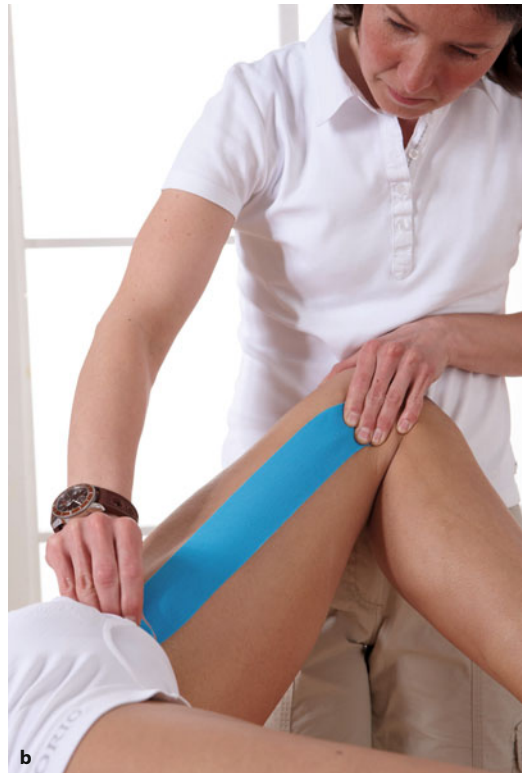
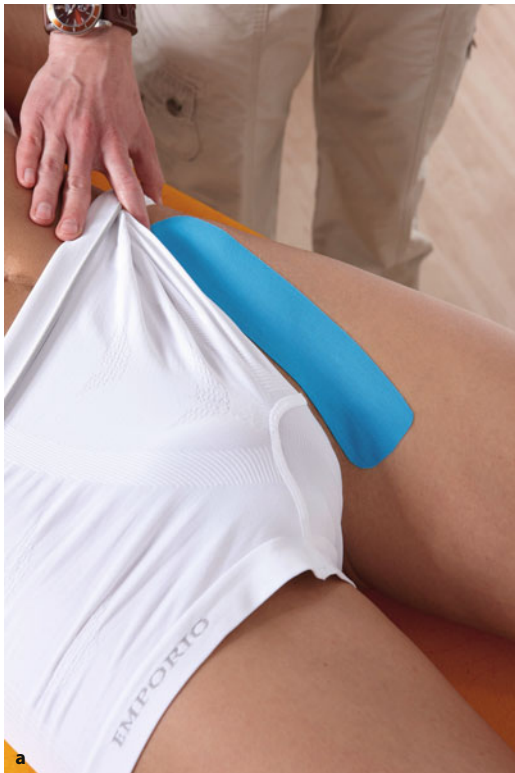Fig. 6.56 a-d. Hip problems: **a-b Application Part 1.** **a** Completed application to the iliac muscle, **b** muscle application to the adductor longus. **c-d Application Part 2.** **c** Completed muscle applications to

the gluteus maximus and to the gluteus medius / minimus, **d** completed application

6.4 Lower extremities

- 6.4.1 Hip problems
- 6.4.2 Torn muscle fibers
- 6.4.3 Osteoarthritis of the knee
- 6.4.4 Achillodynia
- 6.4.5 Ankle joint distortion
- 6.4.6 Splayed foot, fallen arch, flat foot

6.4.1 Hip problems

Definition

Overstrain, degenerative changes, or joint traumata give rise to chronic, painful changes in the joint, which lead to increasingly functional disablement. Erosion initially affects only the cartilage, but there are also subsequent changes to the bone.

The consequences are changes in postural stability and muscular imbalance.

Aim

Various muscle applications bring about an improvement in the **muscle coordination** in the hip joint.

Application

- **Part 1:** Tonus-decreasing muscle application to the iliacus and adductor longus muscles.

The patient is relaxed in the supine position. The base for the iliacus muscle lies on the insertion of the lesser trochanter. The leg is placed in the extended position with inner rotation. With manually anchored base, the tape is affixed up to the anterior superior iliac spine (■ Fig. 6.56a).

The base for the adductor longus muscle lies on the medial condyle of the femur. The leg is placed in abduction. With manually anchored base, the tape is affixed up to the superior pubic ramus (■ Fig. 6.56b).

- **Part 2:** Tonus-increasing muscle application to the gluteus maximus and gluteus medius/minimus muscles.

The patient is in the side position. The base for the gluteus maximus lies on the origin, at the center of the sacrum. The leg is positioned in flexion and adduction. With manually anchored base, the first tape tail is affixed around the lower part of the gluteus. The second tape tail is affixed diagonally across the gluteus up to the greater trochanter (■ Fig. 6.56c).

The base for the gluteus medius / minimus lies on the iliac crest. The leg is positioned in flexion. With manually anchored base, the tape is affixed in a direct line up to the greater trochanter. All tape ends are affixed without tension (■ Fig. 6.56d).

Memo

Application: Muscle application

Cutting technique: I- and Y- tape



■ Fig. 6.57.
Blue I-tape



■ Fig. 6.58.
Red Y-tape



■ Fig. 6.59.
Red I-tape

! Tip

For improved adhesion of the tape to the gluteus maximus muscle, an application using two I-tape strips is also possible. In addition, a covering tape over the tape ends at the greater trochanter is effective.

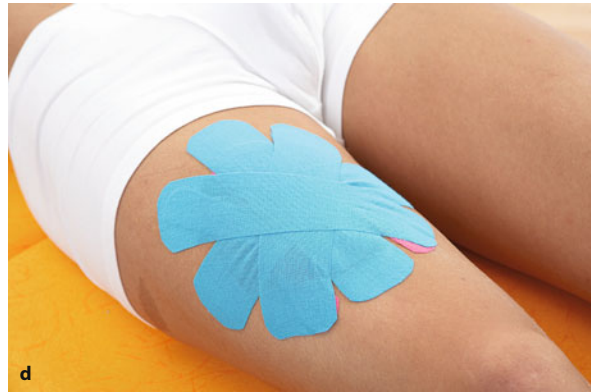
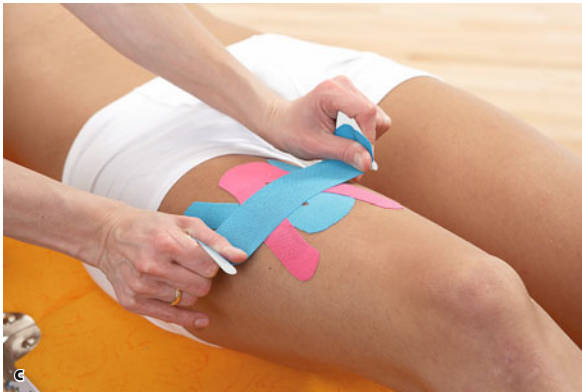
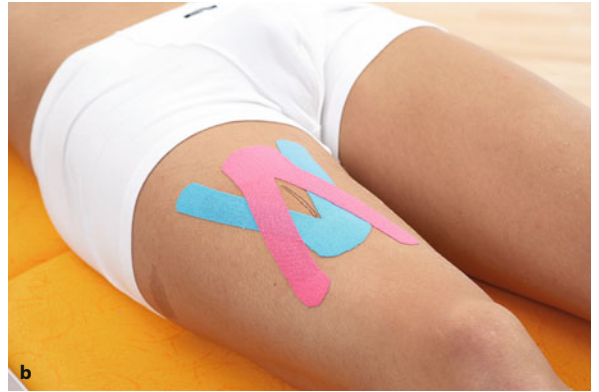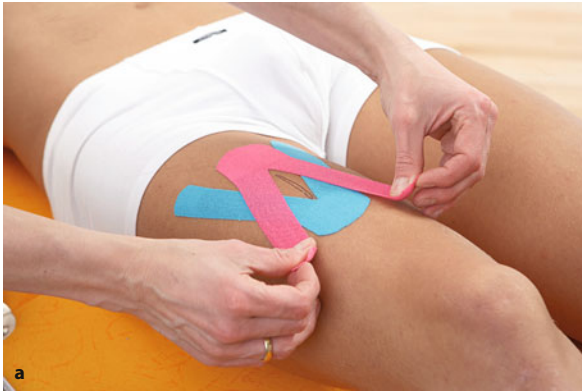Fig. 6.60a-d. Muscle fiber tear: **a-b Application Part 1.** **a** The base lies in front of the muscle fiber tear, cranially or caudally. Tail strips are applied rhythmically along the course of the muscle fiber. The muscle fiber tear lies in the center of the tape tails, **b** completed fascia correc-

tion. **c-d Application Part 2.** **c** Affix the first tape strip across the muscle fiber tear and the second along the muscle at 90° to the first. The last two tapes are each affixed at 45°, **d** Completed application

6.4.2 Torn muscle fibers

Definition

A **muscle fiber tear** is a separation of muscle structures caused by sudden, maximum strain, e.g. a combination of rapid acceleration and deceleration. The muscle cannot absorb or support these sudden **mechanical tractive forces**.

A visible and palpable hollow in the muscle can be identified only immediately after the injury and is subsequently not palpable due to concomitant swelling.

Cold ambient conditions, insufficient warm-up, and muscle hardening contribute to this muscle injury.

In the following example, the muscle fiber tear is in the quadriceps femoris muscle.

Aim

A combination of fascia correction and spacetape brings relief to the torn fibers.

Initial treatment within the first 48 hours consists of a combination of a fascia technique and compression of the injured structure. This results in relief and improved drainage of the edema in the damaged structure. Spacetape is used only after the first 48 hours, otherwise it may lead to increased edema. After this time, spacetape boosts the metabolism and promotes healing of the torn fibers.

Application

■ **Part 1:** The patient's knee is slightly flexed. The tape is the length of the injured structure plus two fingerbreadths. The base lies in front of the torn muscle fiber, i.e. cranially or caudally. The tail tapes are affixed rhythmically along the course of the muscle fibers. The muscle tear lies in the center of the tape tails (■ Fig. 6.60a-b).

■ **Part 2:** The patient's knee is slightly flexed. In general, 15 cm of tape are used for the spacetape. The first tape strip is affixed across the muscle fiber tear and the second is affixed along the muscle at 90° to the first. The last two tapes are each affixed at 45°. All tape strips are affixed en bloc with maximum tension. The tape ends are applied without tension. (■ Fig. 6.60c-d).

Memo

Application: Fascia correction, spacetape

Cutting technique: I- and Y- tape



■ **Fig. 6.61.**
Red Y-tape



■ **Fig. 6.62.**
Blue Y-tape



■ **Fig. 6.63.**
Blue I-tape

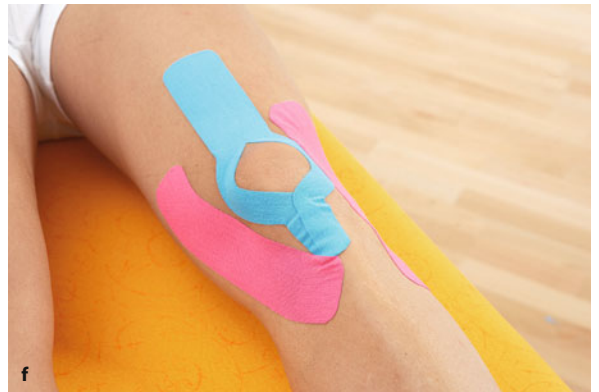
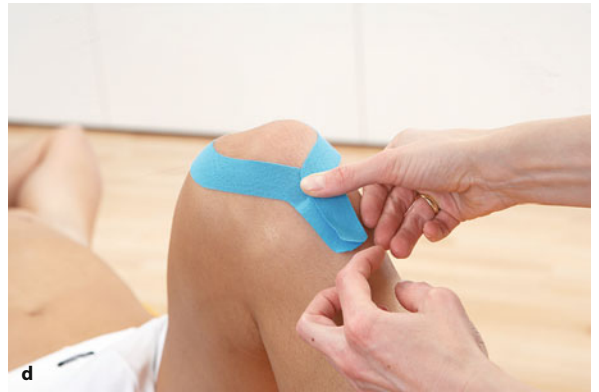
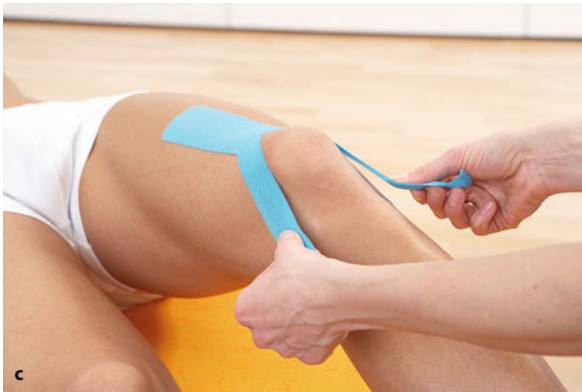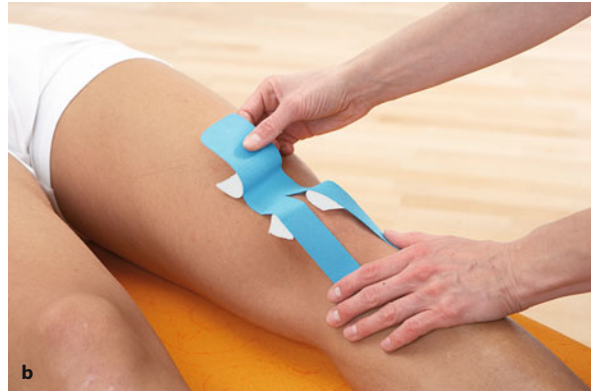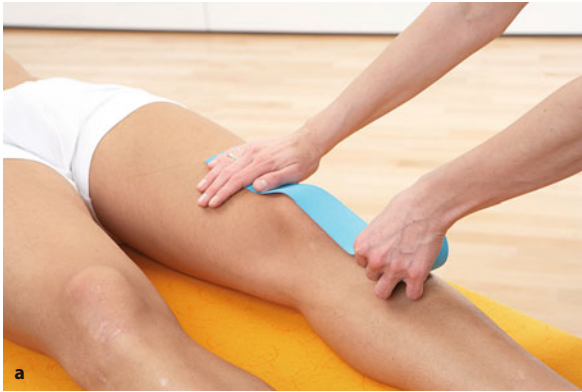Fig. 6.64 a-f. Osteoarthritis of the knee joint: **a-e Application Part 1.** **a** The functional correction using a fascia application is measured from a handbreadth above the patella to the tibial tuberosity, **b** At first, affix only a narrow strip of the base, i.e. approximately a fingerbreadth, over the upper patellar margin. Only then affix the re-

mainder of the base, **c** using both hands, the two tail tapes are affixed round the patella up to its apex, while the patient brings his/her knee into maximum flexion, **d** the tape ends lie one over the other on the tibial tuberosity, **e** completed fascia **f Application Part 2.** **f** Completed application

6.4.3 Osteoarthritis of the knee joint

Definition

Osteoarthritis is a progressive, age-dependent erosion of the joint cartilage caused by an imbalance in the load capacity of the joint and the actual load.

Primary osteoarthritis develops without a recognizable cause.

Secondary osteoarthritis is the result of e.g. malposition, accidents with lasting joint damage, or infections.

In advanced stages, changes occur in the region of the bones near the joint, the synovial membrane, joint capsule, and the muscles spanning the joint, so that the clinical picture of osteoarthritis is no longer confined to cartilage erosion.

Aim

A combination of functional correction with a fascia application and a ligament technique brings about **stabilization of the knee** and **retropatellar pressure reduction**.

Application

— **Part 1:** The tape length for the functional correction using a fascia application is measured from a handbreadth above the patella to the tibial tuberosity (■ Fig. 6.64a). The tape is cut in such a way that the base is a handbreadth long. The backing paper is pulled back at the end of the base up to the Y-tape tail. At first, only a narrow strip of the base, approximately a fingerbreadth, is affixed over the upper margin of the patella. Only then is the remainder of the base affixed (■ Fig. 6.64b). Using both hands, the two tail tapes are affixed around the patella up to its apex, while the patient pulls up his/her knee to its maximum bending capacity (■ Fig. 6.64c). The tape ends lie one over the other on the tibial tuberosity. Both tape ends are affixed without tension (■ Fig. 6.64d-e).

— **Part 2:** The tape for the ligament application is measured between the insertions of the collateral ligaments: for the medial collateral ligament from the medial condyle of the femur to the pes anserinus and for the lateral collateral ligament from the lateral condyle of the femur to the head of the fibula. The tape is affixed in the neutral position. The tapes are each affixed en bloc with maximum tension. The tape ends are affixed without tension with maximum knee flexion. (► Chap. 4.1.1).

Memo

Application: Functional corrective technique using a fascia application

Cutting technique: I- and Y-tape



■ Fig. 6.65.
Blue Y-tape



■ Fig. 6.66.
Red I-tape

! Tip

The tape application is equally appropriate for osteoarthritis of the knee joint and retropatellar osteoarthritis.

For improved adhesion of the tape, a covering tape strip may be affixed over the tape ends.

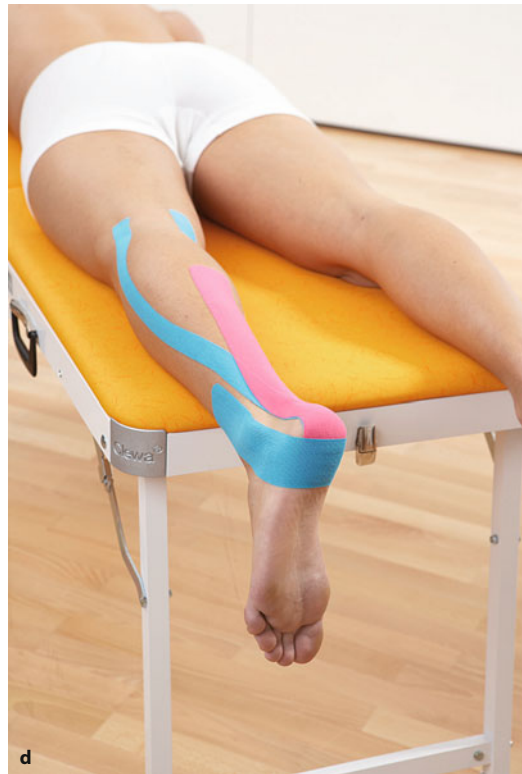
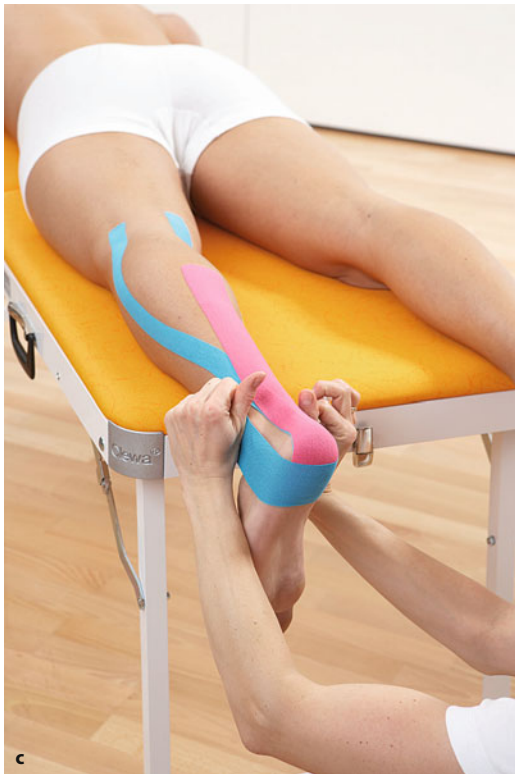
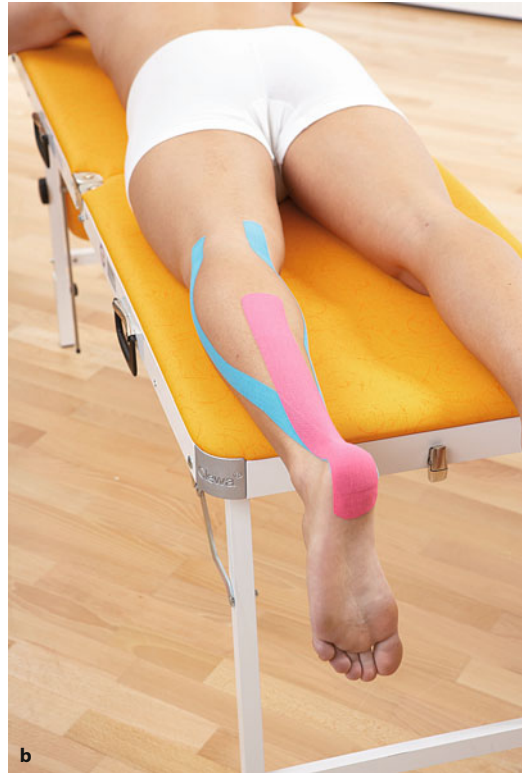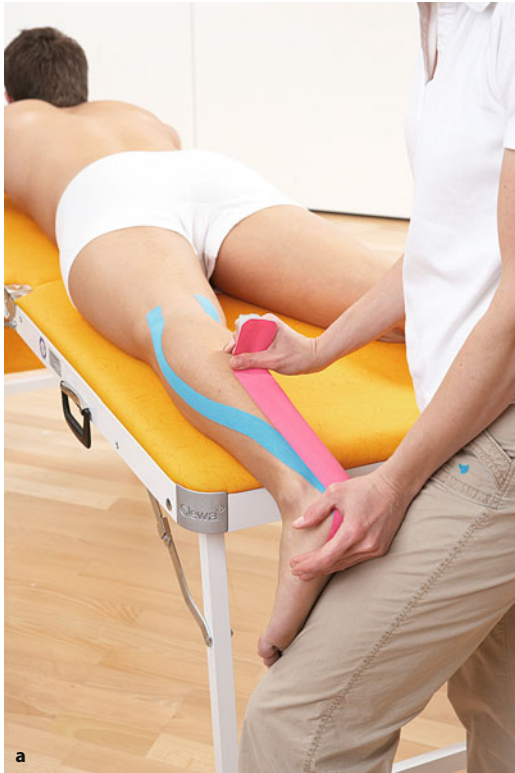Fig. 6.67 a-d. Achillodynia: **a Application Part 1.** **a** Completed muscle application and start of the ligament application to the Achilles tendon. **b Application Part 2.** **b** Completed muscle and ligament

application. **c-d Application Part 3.** **c** Start of the ligament application for the ankle joint, **d** completed application

6.4.4 Achillodynia

Definition

Achillodynia arises from repetitive strain or an unaccustomed brief activity, generally local, leading to chronic overstraining of the Achilles tendon. Achillodynia may also be the result of **osteoarthritis of the ankle joint** or a **foot deformity**.

Aim

A muscle application to the gastrocnemius muscle and a ligament application to the Achilles tendon bring relief to the musculature and tendons, as well stabilizing the ankle joint.

Application

- **Part 1:** The tonus-reducing muscle application is measured from under the heel to the condyle of the femur. The base lies partially over the calcaneus and is affixed up to the insertion of the Achilles tendon. With manually anchored base, the individual tape tails are affixed round the belly of the gastrocnemius muscle. The tape strips end on the condyle of the femur (■ Fig. 6.67a).
- **Part 2:** The tape for the ligament technique is measured from under the heel up to the musculotendinous junction of the gastrocnemius muscle. The base lies over the first application on the calcaneus and is affixed up to the insertion of the Achilles tendon. With manually anchored base, the tape is affixed with maximum tension up to the musculotendinous junction. The tape ends are affixed without tension (■ Fig. 6.67b).
- **Part 3:** The tape measurement for the ankle joint extends over the two malleoli. The tape is affixed en bloc with maximum tension under the calcaneus and over the malleoli. The tape ends are affixed without tension (■ Fig. 6.67c). ■ Fig. 6.67d shows the completed application for achillodynia.

Memo

Application: Muscle technique, ligament technique

Cutting technique: I- and Y-tape



■ Fig. 6.68.
Blue Y-tape



■ Fig. 6.69.
Red I-tape



■ Fig. 6.70.
Blue I-tape

! Tip

The ligament application round the malleolar bifurcation can also be used for corrective tension to the calcaneus. In this case, the base is first affixed centrally under the calcaneus. The lateral tape tail corrects the calcaneus with maximum tension in a craniolateral direction. The medial tape tail is affixed with only 50% tension.

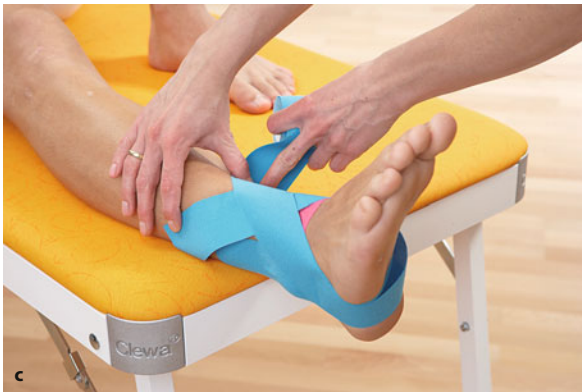
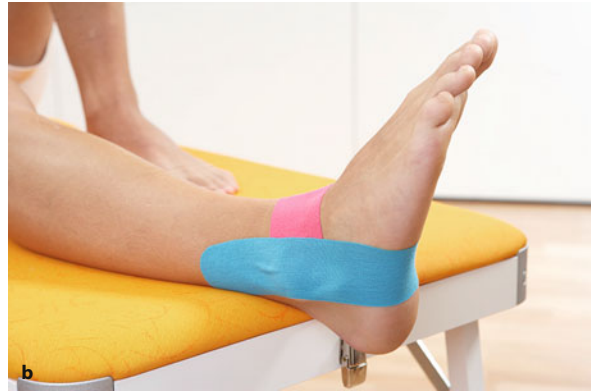
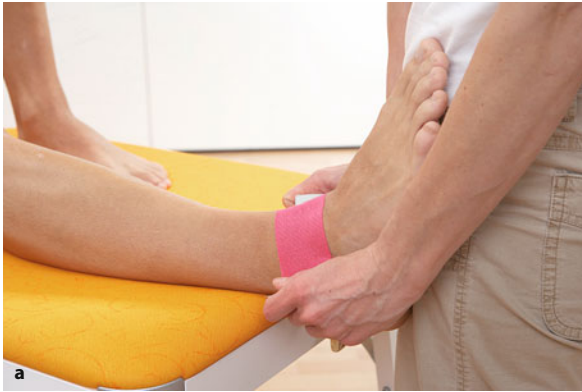Fig. 6.71 a-d. Ankle joint distortion: **a Application Part 1.** **a** The foot is in the neutral position. The tape is affixed en bloc with 50% tension over the ventral capsule. **b Application Part 2.** **b** Completed application to the ventral capsule round the malleolar bifurcation.

c-d Application Part 3. **c** Measure the tape for the ligament application in a half figure of eight loop round the ankle joint from the upper lateral malleolus to the medial malleolus, **d** completed ligament application

6.4.5 Ankle joint distortion

Definition

Ankle joint distortion arises from rolling or twisting the ankle joint with attendant injury to the ligaments or joint capsule; the collagen fibers of these structures are then severely overstretched. Swelling and internal bleeding frequently occurs at the site of injury

Aim

Stabilization of the upper ankle joint is achieved by means of ligament applications.

Application

- **Part 1:** The tape for the ligament application to the ventral capsule is measured ventrally from the lateral malleolus to the medial malleolus. The foot is in the neutral position. The tape is affixed en bloc over the ventral capsule with 50% tension. The tape ends are affixed without tension (■ Fig. 6.71a).
- **Part 2:** The tape for the ligament application round the malleolar bifurcation is measured over the sole of the foot from one malleolus to the other. The foot is in the neutral position. The tape is affixed en bloc with maximum tension under the calcaneus up to the malleoli. For increased restriction of supinatory movement, a corrective pull in a lateral direction can be carried out (► Chap. 4.1.1). This anchoring strengthens the lateral capsule. The tape ends are affixed without tension (■ Fig. 6.71b).
- **Part 3:** The tapes for the half figure eight ligament applications round the ankle joint are measured from the upper lateral malleolus with a half figure eight loop to the other malleolus. The foot is in the neutral position. The base of the first strip lies a handbreadth above the lateral malleolus. Without anchoring the base, the tape is affixed using a fascia technique with 70% pull

round the ankle joint in a half figure eight loop. The second tape is affixed slightly lower using the same technique. The fascia technique allows the possibility of correcting the lateral margin of the foot in an upward direction using maximum tension. The tape ends are affixed without tension (■ Fig. 6.71c-d).

Memo

Application: Ligament technique

Cutting technique: I-tape



■ Fig. 6.72.
Blue I-tape



■ Fig. 6.73.
Red I-tape

! Tip

If there is residual swelling in the ankle joint, the tape over the ventral capsule should be affixed with only 10% tension or without tension. Because the lymphatic drainage may be impeded, this tape must be completely omitted if necessary.

If there is severe swelling in the ankle joint, a lymphatic application alone or under the tape is appropriate.

The two half figure eight tapes are generally applied for additional stability during sporting activities.

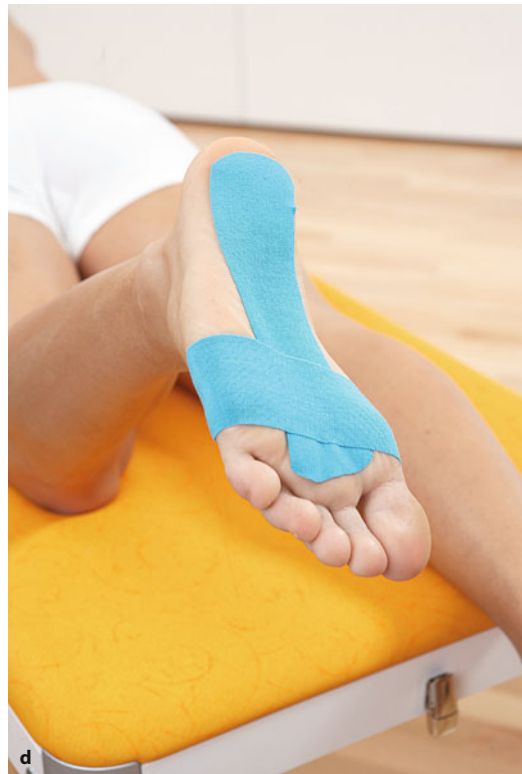
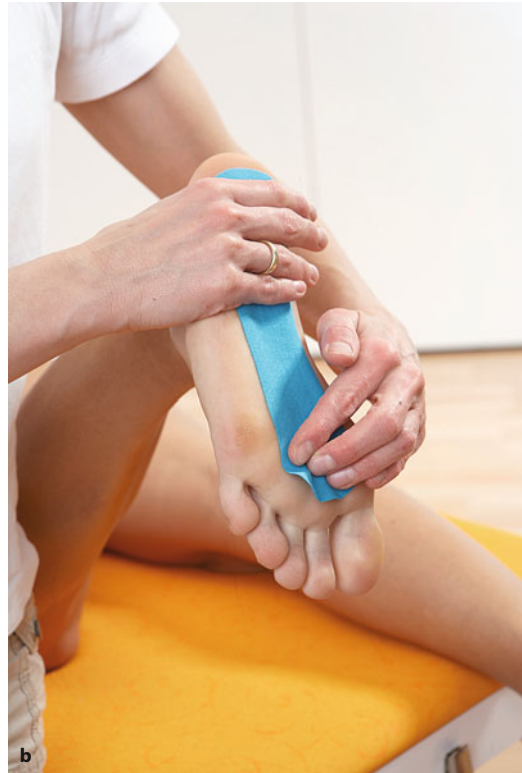
Fig. 6.74 a-d. Splayfoot, fallen arch, and flatfoot: **a-b Application Part 1.** **a** Base lies on the calcaneus and with manually anchored base and 50% tension, affix tape up to the MTP joints, **b** for affixing the tension-free tape end, the toes are brought into extension. **c-d Application**

Part 2. **c** The foot is in the resting position and the tape is affixed en bloc with maximum tension up to the outer margins of the foot, **d** completed application

6.4.6 Splayfoot, fallen arch, and flatfoot

Definition

Weakness of the foot musculature and ligaments gives rise to a change in the longitudinal and transverse arches. This is referred to as a **fallen arch** when the longitudinal arch is flattened and **flatfoot** when the sole of the foot comes into complete contact with the ground.

In **splayfoot**, the metatarsal bones move apart and the transverse arch collapses.

Aim

Ligament applications stimulate the plantar ligament and support the transverse arch.

Application

- **Part 1:** The tape for the ligament application to the plantar ligament is measured from the calcaneus to the metatarsophalangeal (MTP) joints. The foot is positioned in plantar flexion. The base lies on the calcaneus, is anchored manually and affixed up to the MTP joint with 50% tension (■ Fig. 6.74a). The toes are extended and then the tape end is affixed without tension (■ Fig. 6.74b).
- **Part 2:** The tape for the ligament application to the transverse arch is measured from the lateral to the medial foot margins plus a fingerbreadth beyond the MTP joints each side. The foot is in the resting position; the tape is affixed en bloc with maximum tension up to the outer margins of the foot. It is important to avoid compression of the MTP joints. The tape ends are affixed without tension (■ Fig. 6.74c-d).

Memo

Application: Ligament technique

Cutting technique: I-tape



■ Fig. 6.75. Blue I-tape

! Tip

The first tape application under the plantar ligament is affixed with only 50% tension because the tape strip detaches more readily with maximum tension. This tape application combines well with an application for hallux valgus.

7 Lymphatic Applications

7.1 Upper extremities – 161

- 7.1.1 Drainage of medial upper arm – 161
- 7.1.2 Drainage of lateral upper arm – 163
- 7.1.3 Drainage of forearm/entire arm – 165
- 7.1.4 Drainage of upper arm – medial and lateral – 167
- 7.1.5 Drainage of hand – 169
- 7.1.6 Protein fibrosis (Stemmer sign) in the hand – 171
- 7.1.7 Drainage using the arm spiral tape – 173

7.2 Lower extremities – 175

- 7.2.1 Drainage of the thigh – 175
- 7.2.2 Drainage of the lower leg/entire leg – 177
- 7.2.3 Drainage of the entire leg – 179
- 7.2.4 Drainage of the foot – 181
- 7.2.5 Stemmer sign in the foot – 183
- 7.2.6 Drainage using the leg spiral tape – 185

7.3 Trunk – 187

- 7.3.1 Drainage of upper trunk quadrant – 187
- 7.3.2 Drainage of lower trunk quadrant I – 189
- 7.3.3 Drainage of lower trunk quadrant II – 191
- 7.3.4 Drainage of abdomen – 193

7.4 Additional lymphatic applications – 195

- 7.4.1 Drainage of the face – 195
- 7.4.2 Drainage of the shoulder joint – 197
- 7.4.3 Drainage of the knee joint – 199
- 7.4.4 Fibrosis/hematoma – 201

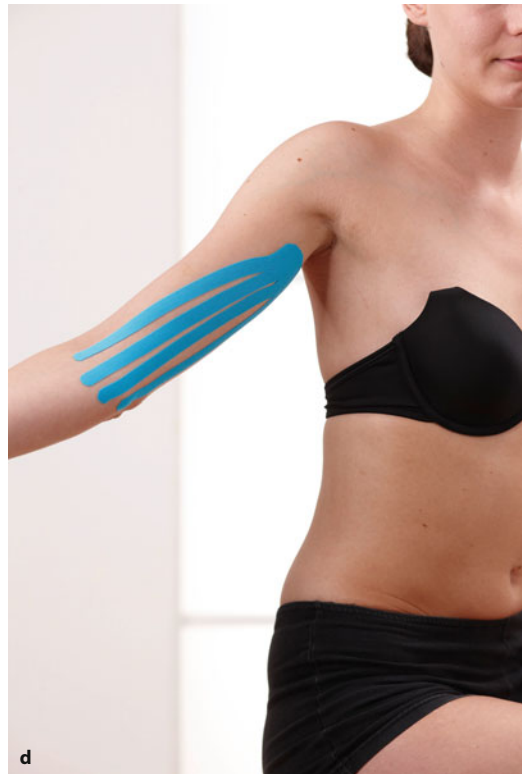
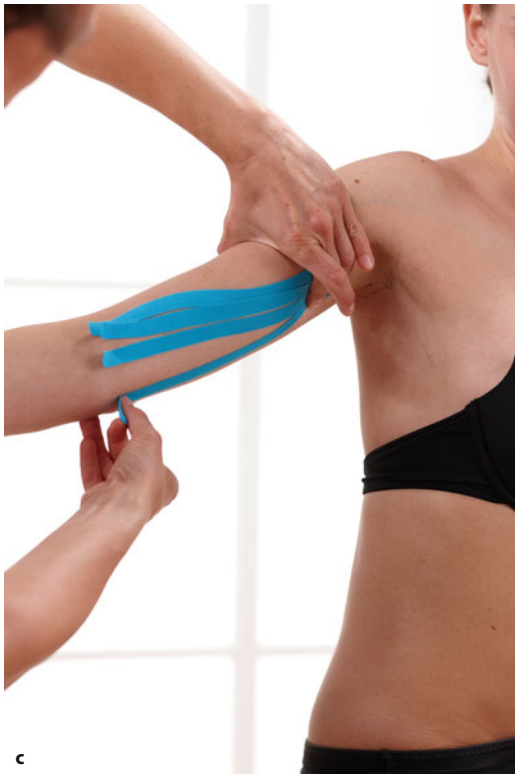
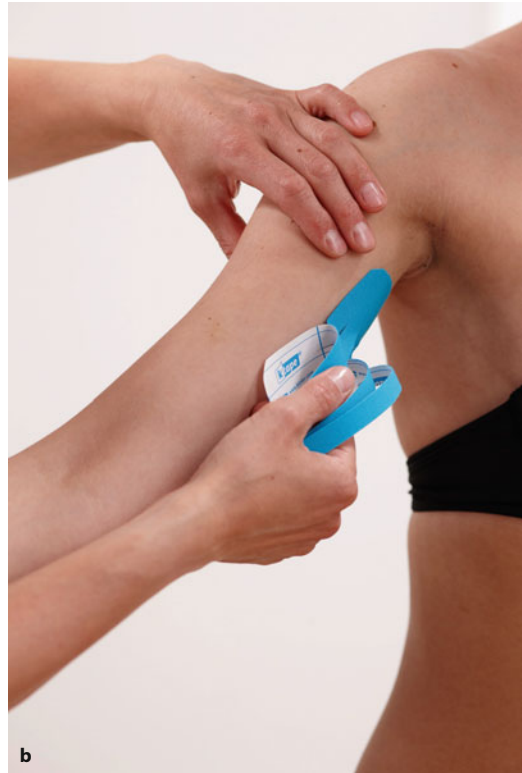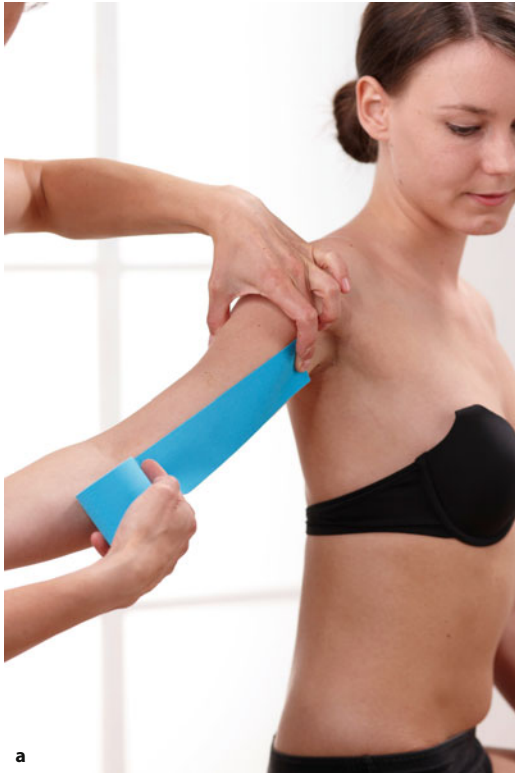Fig. 7.1 a-d. Drainage of the medial upper arm: **a** Measure the tape strip from axilla to inner elbow, **b** affix base slightly removed from axilla. Completely remove backing and lightly affix ends only,

c loosen individual tape tails in succession and with base anchored, affix them uniformly with 25% tension to the medial upper, **d** completed application

7.1 Upper extremities

- 7.1.1 Drainage of medial upper arm
- 7.1.2 Drainage of lateral upper arm
- 7.1.3 Drainage of forearm/entire arm
- 7.1.4 Drainage of upper arm - medial and lateral
- 7.1.5 Drainage of the hand
- 7.1.6 Protein fibrosis (Stemmer sign) in the hand
- 7.1.7 Drainage using the arm spiral tape

7.1.1 Drainage of medial upper arm

Type

This example illustrates drainage of the medial upper arm with an intact lymph node chain.

Base

Because of hair growth and axillary transpiration, the base lies slightly removed from the axilla.

Application

The tape strip is measured from the axilla to the inner elbow (■ Fig. 7.1a). The base is affixed slightly removed from the axilla. Completely remove the backing paper and lightly affix the ends only (■ Fig. 7.1b). The arm is placed in abduction and extension. The individual tape tails are detached in succession and with the bases anchored, they are uniformly affixed to the medial upper arm with 25% tension. The tape ends are affixed without tension (■ Fig. 7.1c). When the application has been completed, the tape strips are carefully rubbed. ■ Fig. 7.1d shows the completed application for drainage of the medial upper arm.

Memo

Application: Lymphatic technique

Cutting technique: Fan tape



■ Fig. 7.2. Blue fan tape

! Tip

For uniform distribution of the individual tail tapes over the medial upper arm, it is advantageous to affix the outermost strip first.

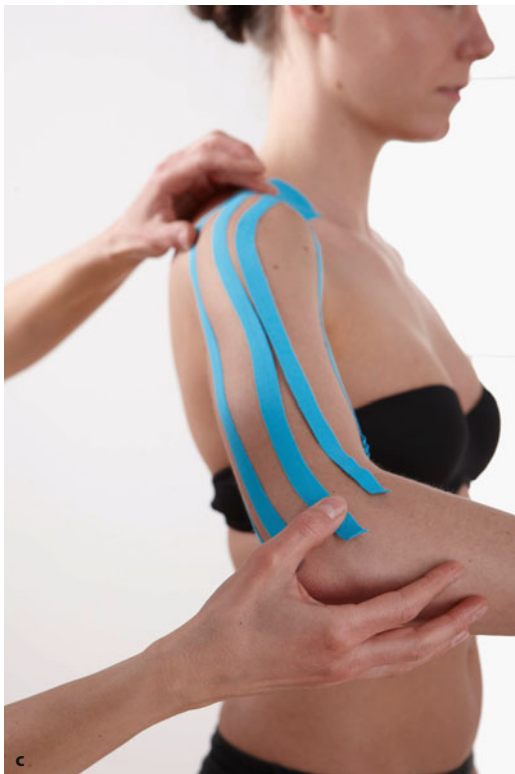
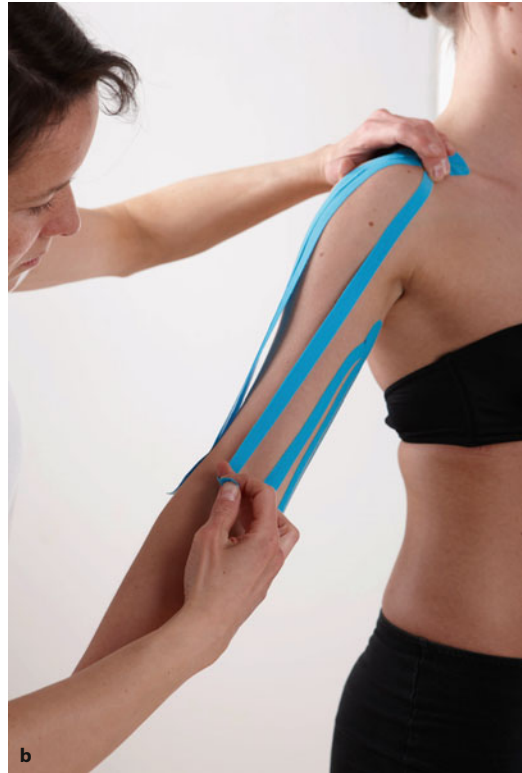

Fig. 7.3 a-c. Drainage of lateral upper arm: Measure the tape strip from the supraclavicular fossa to the elbow, **a** The base lies in the supraclavicular fossa. Remove the backing paper completely over the triceps and lightly affix only the ends, **b** detach the individual tape strips one after the other and with the base anchored, affix them uniformly with 25% tension to the outside of the upper arm, **c** completed application

7.1.2 Drainage of lateral upper arm

Type

This example illustrates **drainage of the lateral upper arm** with intact lymph nodes.

Base

The base lies in the **supraclavicular fossa** (terminus).

Application

The tape is measured from the supraclavicular fossa to the elbow with the arm in adduction and flexion (■ Fig. 7.3a). The base lies in supraclavicular fossa. Remove the tape backing completely over the triceps and lightly affix only the ends (■ Fig. 7.3b). Position the arm in adduction and flexion for the two tail tapes at the back and in abduction and extension for the two tail tapes at the front. The individual tail tapes are detached one after the other and with the base anchored, affixed uniformly with 25% tension to the outside of the upper arm (■ Fig. 7.3c). The tape ends are affixed without tension. The tape strips are carefully rubbed when the application has been completed. ■ Fig. 7.3d shows the completed application for drainage of the lateral upper arm.

Memo

Application: Lymphatic technique

Cutting technique: Fan tape



■ Fig. 7.4. Blue Fan tape

! Tip

For uniform distribution of the individual tail tapes over the outside of the upper arm, the outermost strip should be affixed first.

In most cases, the treatment for drainage of the upper arm combines medial and lateral applications, i.e. the two applications are used together for drainage of the upper arm.

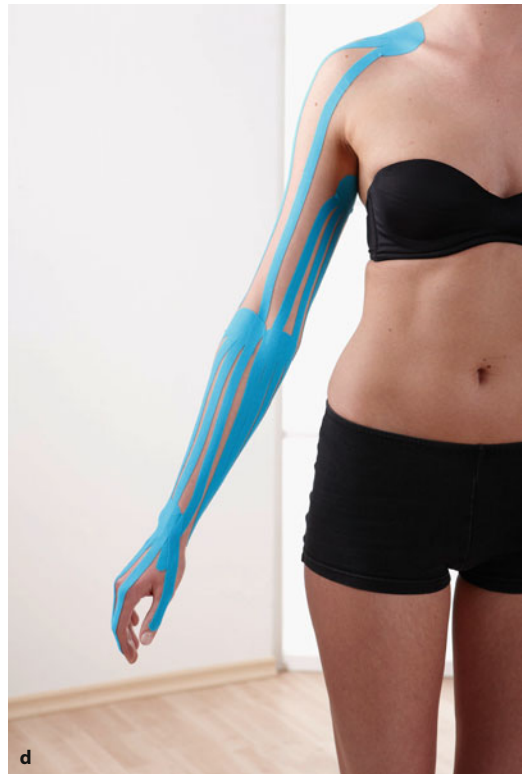
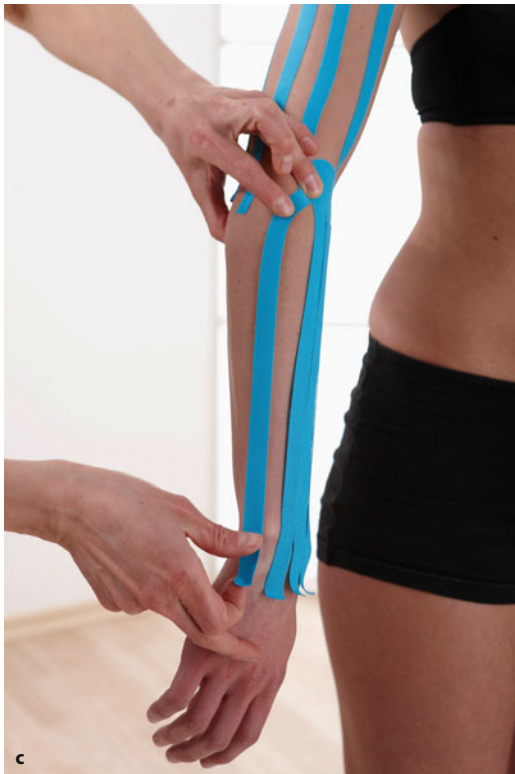
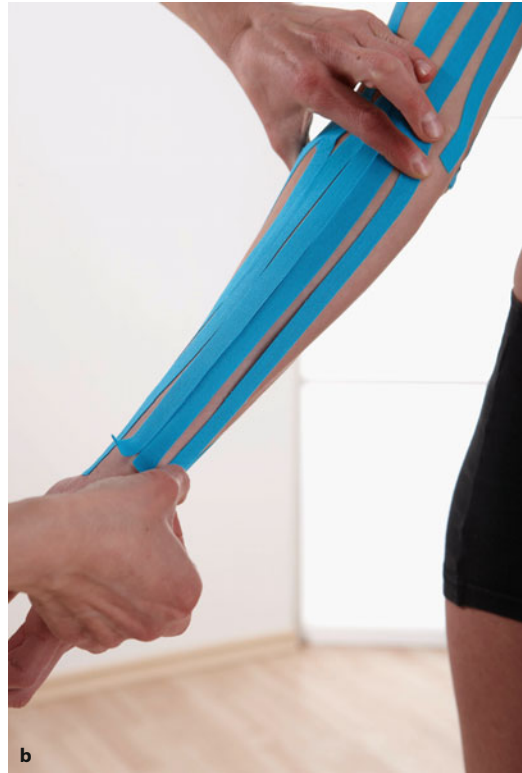Fig. 7.5 a-d. Drainage of entire arm: **a** Measure the tape strip from inner elbow to wrist, **b** bases lie on inner elbow. Completely remove backing paper and lightly affix only the ends. Position hand in dorsal extension for the palmar side and in palmar flexion for the ventral

side, **c** detach the individual tape strips one after the other and with anchored base, affix them uniformly to the forearm with 25% tension, **d** completed application with hand taping

7.1.3 Drainage of forearm/entire arm

Type

This example illustrates **drainage of the forearm/entire arm** with intact lymph nodes.

For the treatment of the entire arm, the applications illustrated for the lateral and medial upper arm are combined (► Chap. 7.1.1 and 7.1.2).

Base

The bases of the two fan tapes lie on the lymph nodes of the elbow.

Application

The tape strip is measured from the inner elbow to the wrist (■ Fig. 7.5a). The bases lie on the inner elbow. Remove the backing paper completely over the forearm and lightly affix only the ends. Position the hand in dorsal extension for the palmar side and in palmar flexion for the ventral side (■ Fig. 7.5b). The individual tape strips are detached one after the other and with anchored base, uniformly affixed to the forearm with 25% tension. The tape ends are affixed without tension (■ Fig. 7.5c). After the application has been completed, the tape strips are rubbed. ■ Fig. 7.5d shows the completed application for drainage of the entire arm.

Memo

Application: Lymphatic technique

Cutting technique: Fan tape



■ Fig. 7.6. Blue fan tape

! Tip

For uniform distribution of the individual tail tapes over the forearm, the outermost strip should be affixed first.

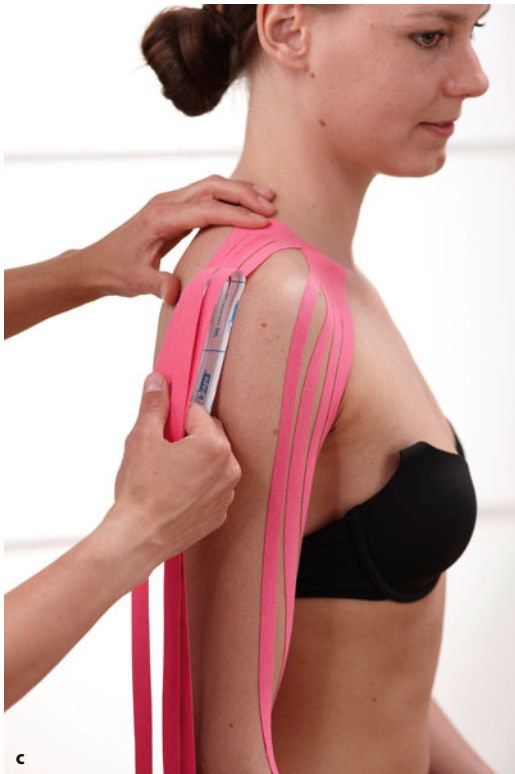
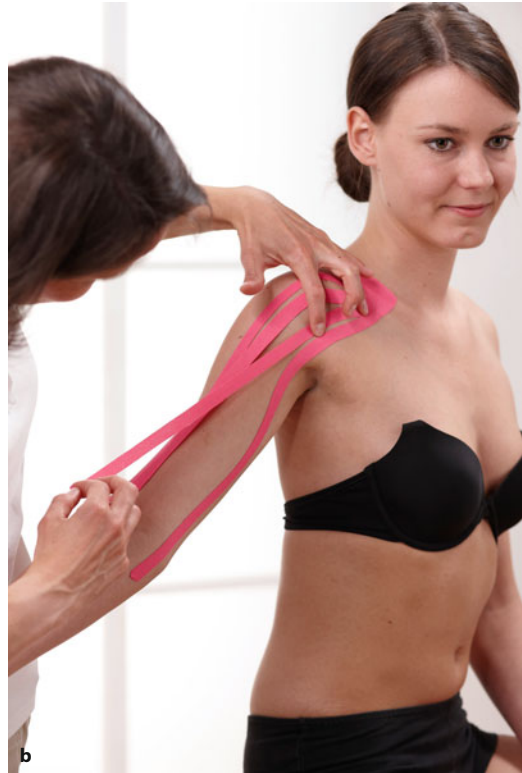
Fig. 7.7 a-d. Drainage of medial and lateral upper arm: **a** Bases lie in the supraclavicular fossa; the first fan tape lies medially on the upper arm, **b** when affixing the individual tape strips, the arm is placed in

different respective positions. Detach individual tapes one after the other and with anchored base, affix to the inner side of upper arm with 25% tension, **c** dorsal tape application, **d** completed application

7.1.4 Drainage of upper arm – medial and lateral

Type

This example illustrates the **drainage of the medial and lateral upper arm** with a defective lymph node chain. The axillary lymph nodes have been partially or completely removed.

Base

The bases of two **fan tapes** lie in the supraclavicular fossa (terminus).

Application

The first fan tape is measured from the supraclavicular fossa to the inner elbow with the arm positioned in extension; the second fan tape is measured from the supraclavicular fossa to the inner elbow with the arm in adduction and flexion. The bases lie in the supraclavicular fossa (■ Fig. 7.7a). The first fan tape lies medially on the upper arm and the second lies laterally. The backing paper is removed completely and only the end lightly affixed. For affixing the individual tape tails, the arm is placed in various positions. For the ventral tape tails, the arm is extended (■ Fig. 7.7b), for the dorsal tape tails, it is flexed, and for the medial tape tails, it is in the neutral position (■ Fig. 7.7c). The individual tape tails are detached one after the other

and with anchored base, uniformly affixed to the entire upper arm with 25% tension. The tape ends are affixed without tension. After the application has been completed, the tape strips are rubbed. ■ Fig. 7.7d shows the completed tape application to the medial and lateral upper arm.

Memo

Application: Lymphatic technique

Cutting technique: Fan tape



■ Fig. 7.8. Red fan tape

! Tip

For uniform distribution of the individual tail tapes over the inner side of the upper arm, the outermost strip should be affixed first.



Fig. 7.9 a-d. Drainage of the hand: **a** Measure the fan tape from the wrist to the distal phalanges with hand and fingers flexed. The base lies on the wrist. Completely remove backing and lightly affix only the ends, **b** affix the individual tape strips with fingers flexed.

Detach the individual tape strips one after the other and with anchored base; affix to fingers II-IV with 25% tension, **c** cut tape strip for the thumb and affix using the same method, **d** Completed application

7.1.5 Drainage of hand

Type

In this example for **drainage of the hand**, the lymph node chain is defective: the axillary lymph nodes have been partially or completely removed.

Base

The base lies on the wrist.

Application

The fan tape is measured from the wrist to the distal phalanges with the hand and fingers flexed. The base lies on the wrist. Remove the backing paper completely and lightly affix only the ends (■ Fig. 7.9a). For affixing the individual tape strips, the hand and fingers are flexed. The individual tape tails are detached one after the other and with anchored base, affixed with 25% tension to fingers II to IV (■ Fig. 7.9b-c). A separate tape strip is cut for the thumb and affixed using the same method. The tape ends are affixed without tension (■ Fig. 7.9d). The tape is rubbed after the application has been completed

Memo

Application: Lymphatic technique

Cutting technique: Fan tape



■ Fig. 7.10. Blue fan tape

! Tip

For treating the entire arm, the applications illustrated for the lateral and medial upper arm, the entire forearm, and the hand are combined.

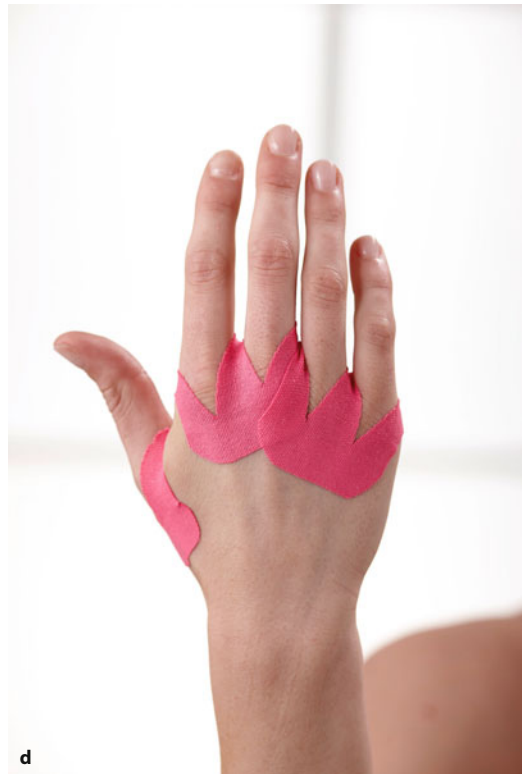
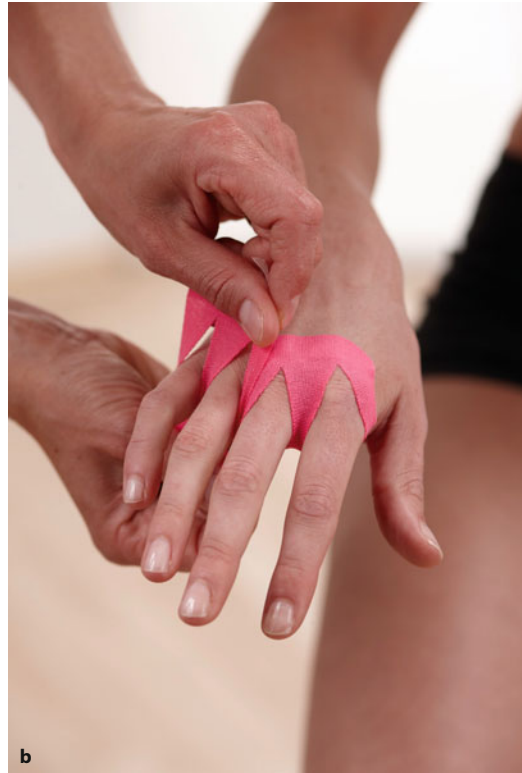
Fig. 7.11 a-d. Stemmer sign hand: **a** Affix tape application en bloc with maximum tension over two fingers, **b** affix two tape strips for

fingers II to IV, **c** cut and affix tape strip to thumb using the same method; **d** completed application dorsal view

7.1.6 Protein fibrosis (Stemmer sign) in the hand

Type

This example illustrates a tape application for a hand with **protein fibrosis**; the lymph node chain is defective, with partial or complete removal of the axillary lymph nodes.

The typical protein fibrosis in lymphedema develops over a period of months or years through the accumulation of protein-rich fluid in the **subcutaneous interstitial connective tissue**. In protein fibrosis of the hand, there is thickening of the skin of the fingers. In the toes, this condition is referred to as the **Stemmer sign**.

Application

A ligament technique is used for the treatment of protein fibrosis. The tape length is generally 10 cm. The tape is folded in the middle and two triangles are cut out from the closed side. The tape is affixed en bloc with maximum tension over two fingers (■ Fig. 7.11a). For the complete hand, two separate tape strips are affixed to fingers II to IV and a third tape strip is cut for the thumb and is affixed using the same method (■ Fig. 7.11b-d). The tape ends are affixed without tension.

Memo

Application: Ligament technique

Cutting technique: Triangular tape



■ Fig. 7.12. Red I-tape

! Tip

For treating protein fibrosis in the hand, the entire arm is treated.

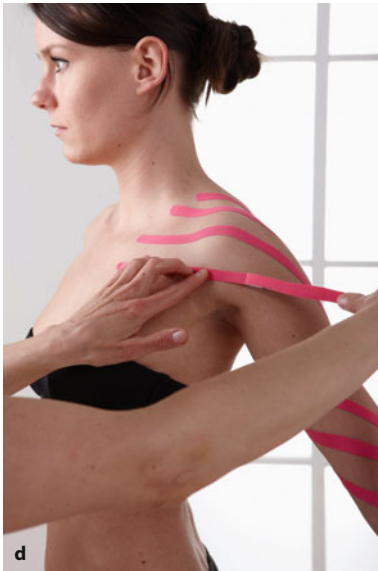
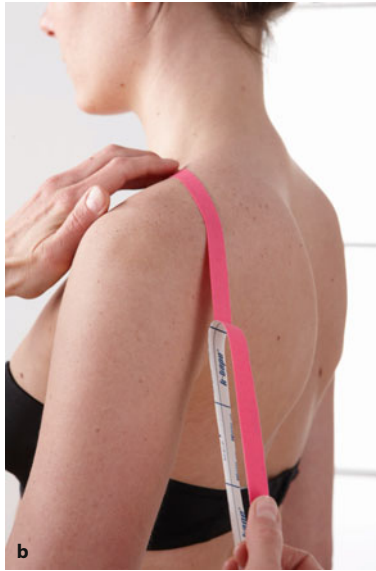
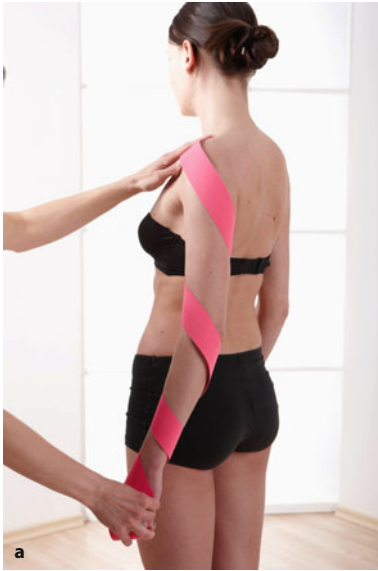

Fig. 7.13 a-e. Drainage using the arm spiral: **a** Measure the tape strips from the supraclavicular fossa in a spiral round the arm to the wrist, generally 4-5 spirals. The first two bases lie in the supraclavicular fossa and the last two on the upper thorax, **b** Affix the tape with anchored base and skin displacement in a spiral at an angle of 45° round the arm without tension, **c** first tape strip begins in a dorsal direction and the other tape strips run parallel to the first with a space between, **d** first tape strip begins in a dorsal direction and the other tape strips run parallel to the first with a space between, **e** completed application

7.1.7 Drainage using the arm spiral tape

Type

This example illustrates **drainage using the arm spiral**; the lymph node chain is defective, with partial or complete removal of the axillary lymph nodes.

Base

With the spiral, there is no common base. Each individual tape has its own origin and the tape application is affixed without tension. With this application, lymphatic drainage should be channeled over a larger area into the healthy quadrant. The spiral supports the **scoop grip** in manual lymphatic drainage.

Application

The tape strips are measured from the supraclavicular fossa around the arm in a spiral to the wrist. As a rule, 4-5 spirals are required for a complete tape application. The tape is quartered along its length. The first two tape bases lie in the supraclavicular fossa and the last two ventrally on the upper thorax (■ Fig. 7.13a). The bases are affixed in the resting position. With anchored base and skin displacement, the tape strips are affixed without tension in a spiral form at an angle of 45° around the arm (■ Fig. 7.13b). The first tape strip begins in a dorsal direction and the other tape strips run parallel to the first with a space between. The tape ends may continue onto the fingers (■ Fig. 7.13c).

■ Fig. 7.13d-e shows the completed application of the arm spiral from a ventral and dorsal perspective respectively.

Memo

Application: Spiral lymphatic technique

Cutting technique: I-tape



■ Fig. 7.14. Red I-tape

! Tip

Tape strips three and four should begin in the healthy quadrant if there is no additional application to drain the upper trunk quadrant.

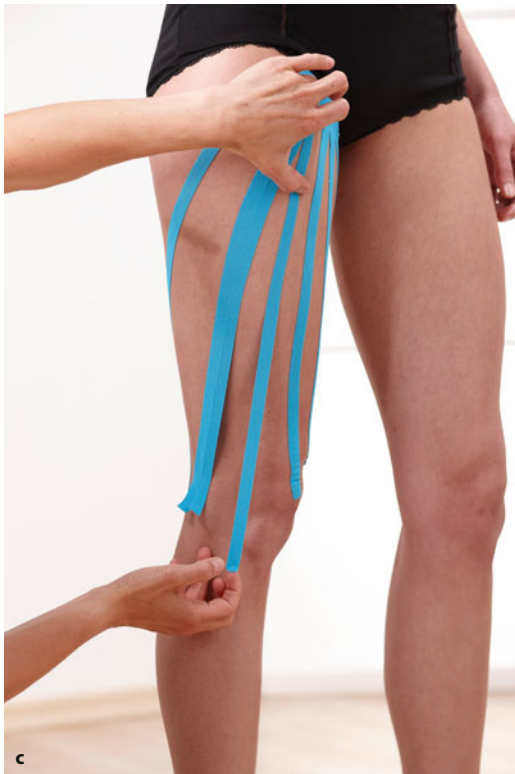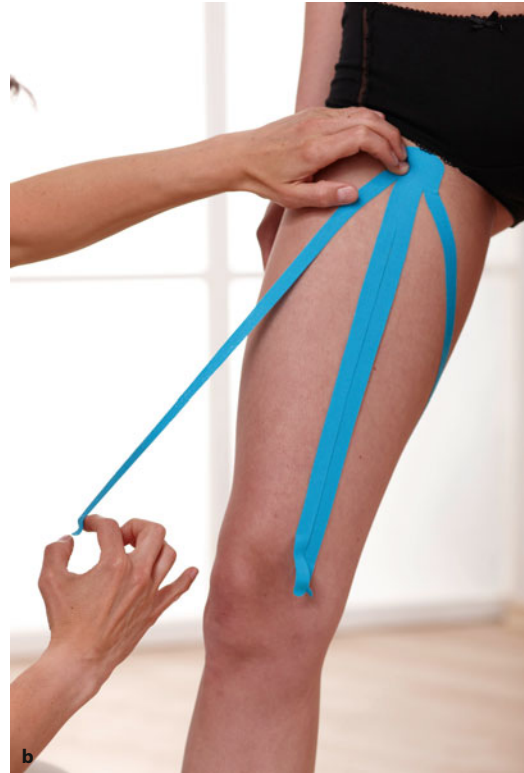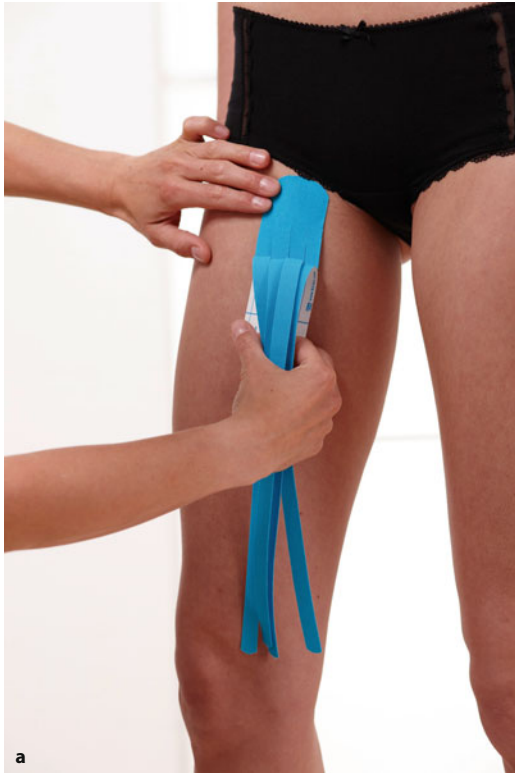


Fig. 7.15 a-d. Drainage of the thigh: **a** Affix the base to the groin. Completely remove backing paper and lightly affix only the ends,

b tape strip spread on the medial side of the thigh, **c** second tape strip covers the lateral side of the thigh, **d** completed application

7.2 Lower extremities

- 7.2.1 Drainage of the thigh
- 7.2.1 Drainage of the lower leg/entire leg
- 7.2.3 Drainage of the entire leg
- 7.2.4 Drainage of the foot
- 7.2.5 Stemmer sign in the foot
- 7.2.6 Drainage using the leg spiral tape

7.2.1 Drainage of the thigh

Type

This example illustrates **drainage of the thigh** with an intact lymph node chain.

Base

The two bases lie in the groin.

Application

The tape is measured from the groin to the knee with the leg positioned in abduction and extension. Affix the bases to the lymph nodes in the groin (■ Fig. 7.15a). Completely remove the backing paper and lightly affix only the ends. Position the leg in abduction and extension. The first tape strip covers the medial side of the thigh and the second the lat-

eral part because there is a lymphatic watershed (► Chap. 2.4) on the back of the thigh. Tape should not be applied over this watershed because it is a physiological barrier for lymphatic drainage. The individual tape strips are detached one after the other and with anchored base and skin displacement, they are uniformly affixed to the thigh with 25% tension (■ Fig. 7.15b, c). The tape ends are affixed without tension. The tape strips are rubbed after the application has been completed. ■ Fig. 7.15d shows the completed tape application.

Memo

Application: Lymphatic technique

Cutting technique: Fan tape



■ Fig. 7.16. Blue fan tape

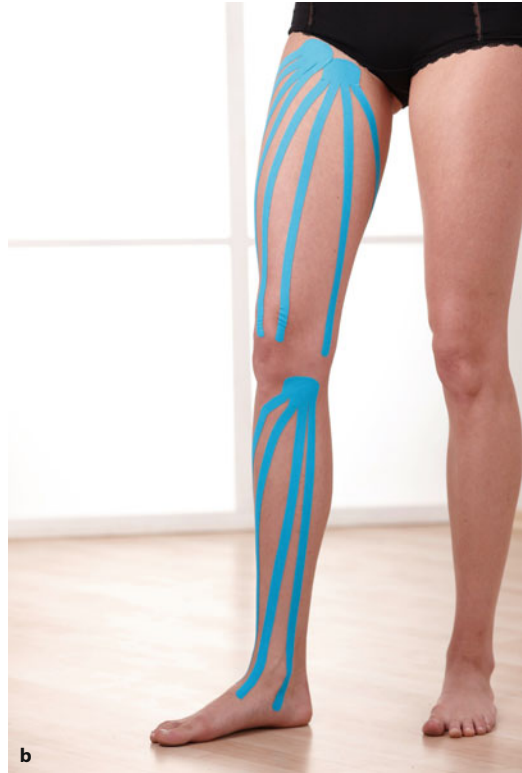

Fig. 7.17 a-c. Drainage of the lower leg: **a** The first base lies on the bottleneck and the individual tape tails are affixed over the ventral side of the lower leg with plantar flexion, **b** completed ventral lower leg application, **c** completed application dorsal view

7.2.2 Drainage of the lower leg/entire leg

Type

This example illustrated the **drainage of the lower leg** and the entire leg with an intact lymph node chain.

Base

The first base lies on the **physiological bottleneck** of the superficial lymphatic vessels of the ventromedial bundle on the medial side of the knee, and the second base in the popliteal fossa.

Application

The tape strip is measured from the popliteal fossa to the ankle joint. The first base lies medially on the knee joint at the bottleneck of the ventromedial bundle; the individual tape tails are affixed to the ventral surface of the lower leg with plantar flexion (■ Fig. 7.17a-b). The second base lies in the popliteal fossa and the individual tape tails are affixed over the entire calf with dorsal extension of the foot. Both tape strips are affixed with anchored base, skin displacement, and 25% tension. The tape ends are affixed without tension (■ Fig. 7.17c). The tape strips are rubbed after the application has been completed.

Memo

Application: Lymphatic technique

Cutting technique: Fan tape



■ Fig. 7.18. Blue fan tape

! Tip

For the treatment of the entire leg, the applications illustrated for drainage of the thigh and lower leg are combined (► Chap. 7.2.1 and 7.2.2).

For exclusive drainage of the ankle joint or foot with an intact lymph node chain, the application to the lower leg is sufficient.



Fig. 7.19 a-d. Drainage of the entire leg: **a** Base lies in the upper trunk quadrant, completed ventral thigh application, **b** completed

lateral thigh application, **c** completed application ventral view, **d** completed application dorsal view

7.2.3 Drainage of the entire leg

Type

This example illustrates the **drainage of the entire leg**; the lymph node chain is defective, with partial or complete removal of the inguinal lymph nodes.

Base

The bases on two fan tapes lie in the healthy **upper trunk quadrant**.

Application

The tape is measured from the healthy trunk quadrant, slightly above the level of the umbilicus, to the knee joint. The bases lie offset in the healthy upper trunk quadrant. The first tape tail is affixed over the medial side of the thigh with trunk extension, lateral inclination to the opposite side, and hip extension (■ Fig. 7.19a). The second tape tail is affixed over the lateral side of the thigh with the same trunk and leg positioning. Both tape strips are affixed with anchored base, skin displacement, and 25% tension.

The tape ends are affixed without tension. The tape strips are rubbed after the application has been completed.

■ Fig. 7.19b-d shows the completed application for drainage of the entire leg from ventral and dorsal aspects.

Memo

Application: Lymphatic technique

Cutting technique: Fan tape



■ Fig. 7.20. Red fan tape

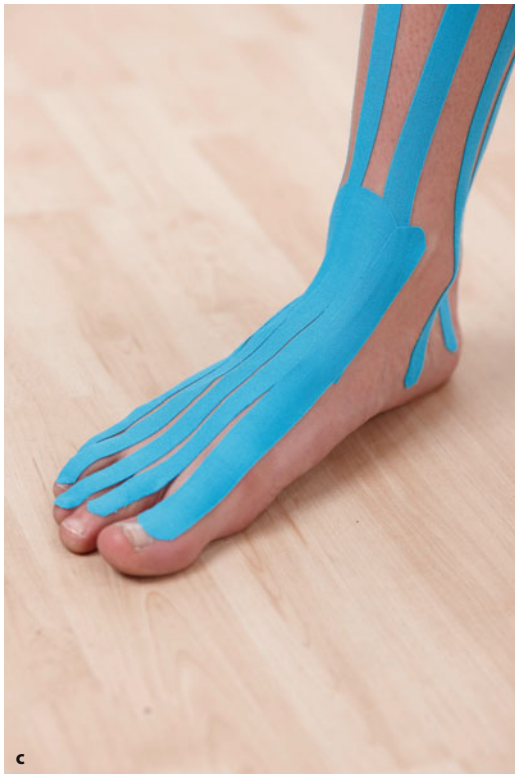
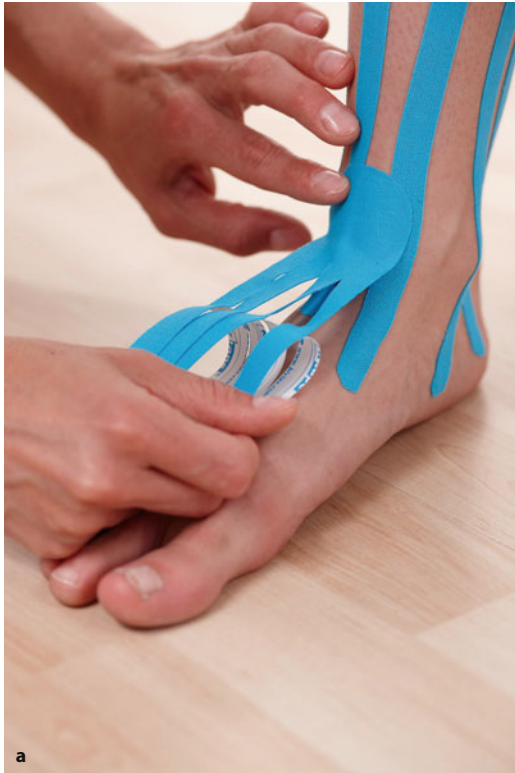
Fig. 7.21 a-d. Drainage of the foot: **a** Base lies ventrally on ankle. Application of individual tape strips, ankle in plantar flexion and toes in flexion, **b** detach individual tape tails one after the other and with

anchored base and skin displacement, affix to toes II to IV with 25% tension, **c** affix tape strip to big toe using the same method, **d** completed application

7.2.4 Drainage of the foot

Type

This example illustrates **drainage of the foot**; the lymph node chain is defective, with partial or complete removal of the inguinal lymph nodes.

Base

The base lies ventrally on the ankle joint.

Application

The tape is measured from the ankle joint to the distal phalanges of the toes with the foot in plantar flexion and the toes positioned in flexion. The base lies ventrally on the ankle joint. Remove the backing paper completely and lightly affix only the ends. For affixing the individual tape tails, the ankle is positioned in plantar flexion and the toes in flexion (■ Fig. 7.21a). The individual tape tails are detached one after the other and with anchored base and skin displacement, affixed to toes II to IV with 25% tension (■ Fig. 7.21b). A separate tape strip is cut for the big toe and is applied using the same method (■ Fig. 7.21c). The tape ends are affixed without tension. The tape strips are rubbed after the application has been completed (■ Fig. 7.21d).

Memo

Application: Lymphatic technique

Cutting technique: Fan tape



■ Fig. 7.22. Blue fan tape

! Tip

For the treatment of the entire leg and foot, the applications illustrated for drainage of the thigh and lower leg are combined (► Chap. 7.2.1 and 7.2.2).

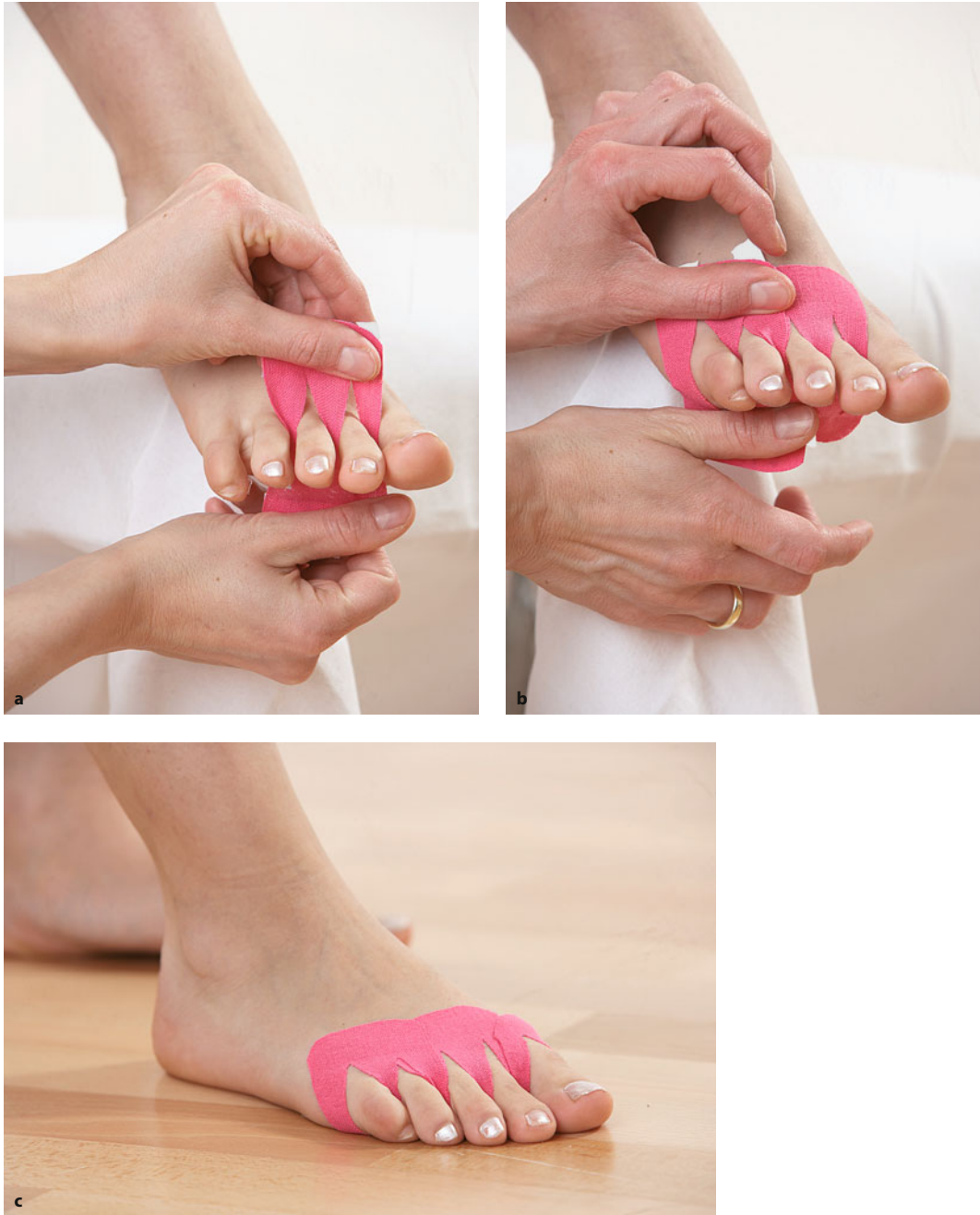

Fig. 7.23 a-c. Stemmer sign foot: **a** Affix the tape application en bloc with maximum tension over two toes, **b** cut and affix application for toes III – IV using the same method, **c** completed application with a separate tape strip for the big toe

7.2.5 Stemmer sign in the foot

Type

This example illustrates a tape application for a foot with a positive Stemmer sign; the lymph node chain is defective, with partial or complete removal of the inguinal lymph nodes.

Lymphatic protein fibrosis gives rise to thickening of the skin of the toes.

A positive Stemmer sign is present when the skin on the dorsum of the second toe is pinched with two fingers and cannot be lifted into a fold.

Application

A ligament technique is used for the treatment of the **Stemmer sign**. The tape length is generally 10 cm. The tape is folded across once and two triangles cut out of the folded side. The tape is applied en bloc with maximum tension over two toes (■ Fig. 7.23a). For the complete foot, two tape strips for toes II to IV are affixed and a separate tape strip is cut and affixed for the big toe using the same method (■ Fig. 7.23b-c). The tape ends are affixed without tension.

Memo

Application: Ligament technique

Cutting technique: I-tape



■ Fig. 7.24. Red I-tape

! Tip

For the treatment of the Stemmer sign, the entire leg is treated.



Fig. 7.25 a-c. Drainage using the leg spiral: **a** Bases lie above the level of the umbilicus in the healthy trunk quadrant. Bases are affixed in the resting position. The tape strips are affixed with anchored base and skin displacement in a spiral form at 45° around the leg without tension, **b** completed application lateral view, **c** completed application dorsal view

7.2.6 Drainage using the leg spiral tape

Type

This example illustrates **drainage using the leg spiral**; the lymph node chain is defective, with partial or complete removal of the inguinal lymph nodes.

Base

There is no common base for the leg spiral application. The tape application is affixed without tension. Each individual tape strip has its own origin. With this application, lymphatic drainage should be channeled over a larger area into the healthy quadrant. The spiral supports the scoop grip in manual lymphatic drainage.

Application

The tape is measured from the healthy trunk quadrant above the umbilicus in a spiral form to the foot. As a rule, 4-5 spirals are required. The tape is quartered along its length. All bases lie above the level of the umbilicus in the healthy trunk quadrant. The bases are affixed in the resting position. With anchored base and skin displacement, the tape strips are affixed in a spiral form at 45° around the leg without tension. The first tape strip begins medially at the side of the trunk and the other tape strips run in a dorsal direction parallel to the first with a space between

(Fig. 7.25a). The tape ends may continue onto the toes.

Fig. 7.25 b-c shows the completed application of the leg spiral from the dorsolateral and ventrolateral aspects.

Memo

Application: Lymphatic technique

Cutting technique: I-tape



Fig. 7.26. Red I-tape

! Tip

All tape strips may begin at the axilla of the healthy quadrant if there is no additional application to drain the upper trunk quadrant.



Fig. 7.27 a-d. Drainage of upper trunk quadrant: **a** The tape strip is measured from axilla to axilla, **b** base lies in front of the axilla in the

healthy quadrant, **c** affix the tape strips uniformly and horizontally across the chest with 25% tension, **d** completed application

7.3 Trunk

- 7.3.1 Drainage of the upper trunk quadrant
- 7.3.2 Drainage of lower trunk quadrant I
- 7.3.3 Drainage of lower trunk quadrant II
- 7.3.4 Drainage of abdomen

7.3.1 Drainage of upper trunk quadrant

Type

In this example, a tape application is used for **drainage of the upper trunk quadrant**; the lymph node chain is defective, with partial or complete removal of the right axillary lymph nodes.

Base

The base lies in front of the axilla in the healthy quadrant.

Application

The tape is measured from the right axilla to the left axilla (■ Fig. 7.27a). The tape is quartered along its length (■ Fig. 7.27b). The tape strips are uniformly distributed horizontally over the chest. For affixing the individual tape strips, the upper part of the body is extended. The application is affixed with anchored base, skin displacement, and 25% tension and the tape ends are affixed without tension (■ Fig. 7.27c). The tape strips are rubbed after the application has been completed. Die ■ Fig. 7.27d shows the completed application for drainage of the upper trunk quadrant.

Memo

Application: Lymphatic technique

Cutting technique: I-tape



■ Fig. 7.28. Red I-tape

! Tip

Depending upon whether the therapist undertakes dorsal treatment during manual lymphatic drainage, **dorsal trunk drainage of the upper trunk quadrant is an additional possibility.**

In lymphedema of the arm, this tape application can also be used in combination with a compression arm sleeve.



Fig. 7.29 a,b. Drainage of lower trunk quadrant I: **a** Measure the tape strip from axilla to base of leg application. The base of the fan tape lies close to the axilla, for elongation, position the arm in abduction and the trunk in lateral inclination. Completely remove the back-

ing paper and lightly affix only the ends, detach individual tape tails one after the other and with anchored base and skin displacement, affix with 25% tension, **b** completed application

7.3.2 Drainage of lower trunk quadrant I

Type

This example illustrates a tape application for **drainage of the lower trunk quadrant**; the lymph node chain is defective, with partial or complete removal of the right inguinal lymph nodes. It shows a combination with drainage of the entire leg.

Base

The base of the fan tape lies in the right axilla.

Application

The tape strip is measured from the axilla to the base of the leg application (■ Fig. 7.29a). The base of the fan tape lies close to the axilla. For elongation, the arm is positioned in abduction and the trunk in lateral inclination. Remove the backing paper completely and lightly affix only the ends. The individual tail tapes are detached one after the other and with anchored base and skin displacement, affixed with 25% tension. The tape ends are affixed without tension. The

tape strips are rubbed after the application has been completed. ■ Fig. 7.29b shows the completed application for drainage of lower trunk quadrant I in combination with drainage of the entire leg and the lower trunk quadrant II.

Memo

Application: Lymphatic technique

Cutting technique: Fan tape



■ Fig. 7.30. Red fan tape



Fig. 7.31a-c. Drainage of the lower trunk quadrant II: **a** Measure the tape strip from left to right iliac spine, base of the fan tape lies on the anterior superior iliac spine. For elongation, the trunk is extended. Affix individual tape tails below the umbilicus parallel across the abdomen with anchored base, skin displacement, and 25% tension, **b** completed drainage of lower trunk quadrant and right leg, **c** completed application

7.3.3 Drainage of lower trunk quadrant II

Type

This example illustrates an application for **drainage of the lower trunk quadrant II**; the lymph node chain is defective, with partial or complete removal of the right inguinal lymph nodes.

Base

The base of the fan tape lies above the left groin on the anterior superior iliac spine (ASIS).

Application

The tape strip is measured from the right to the left anterior superior iliac spine (■ Fig. 7.31a). The base of the fan tape lies on the anterior superior iliac spine of the healthy side, so that the flow of lymph is channeled to the healthy lower trunk quadrant. For elongation, the trunk is extended. Completely remove the backing paper and lightly affix only the ends. The individual tape tails are affixed below the umbilicus parallel across the abdomen with anchored base, skin displacement, and 25% tension (■ Fig. 7.31b, c). The tape ends are affixed without tension. The tape strips are rubbed after the application has been completed. ■ Fig. 7.31c shows the completed application for drainage of lower trunk quadrant II and I.

Memo

Application: Lymphatic technique

Cutting technique: Fan tape



■ Fig. 7.32. Red fan tape

! Tip

A combination of the two applications for drainage of the lower trunk quadrants I and II may be used to avoid overloading one of the individual trunk quadrants.

In lymphedema of the leg, this tape application can also be used in combination with a compression stocking.

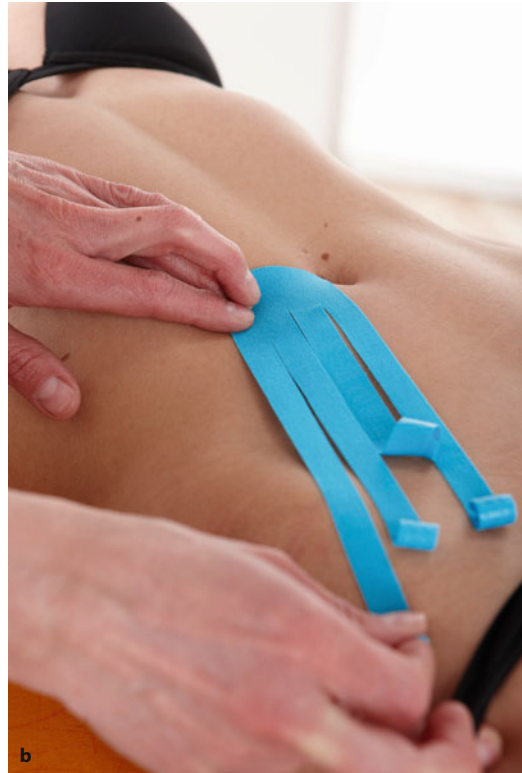
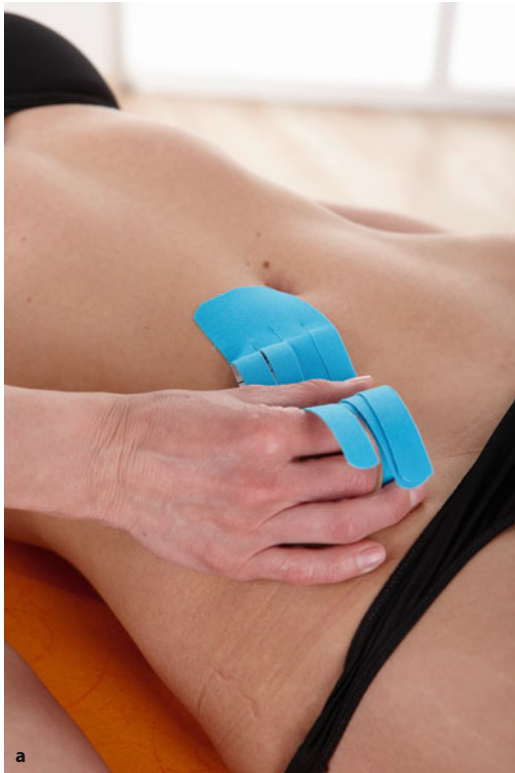
Fig. 7.33 a-d. Drainage of the abdomen: **a** Affix bases in the resting position. For affixing the tape, the upper body is extended and the abdomen pushed out, **b** detach individual tail tapes one after the other and with anchored base, skin displacement, and 25% tension,

affix uniformly to the entire lower abdomen in the direction of the groin, **c** completed application of the right side, **d** completed application of the abdomen

7.3.4 Drainage of abdomen

Type

This example illustrates an application for **drainage of the abdomen** with a right or left defective lymph node chain with partially or completely removed lymph nodes.

Base

The bases of the two fan tapes lie in the region of the **cisterna chyli**.

Application

The two tape strips are measured from the umbilicus to the respective groin. Affix the bases in the resting position (■ Fig. 7.33a). For affixing the tape, the upper body is extended and the abdomen pushed out (by breathing deeply into the abdomen). Completely remove the backing paper and lightly affix only the ends. The individual tape tails are detached one after the other and uniformly affixed with anchored base, skin displacement, and 25% tension to the entire lower abdomen in the direction of the groin (■ Fig. 7.33b). The tape ends are affixed without tension. The tape strips are rubbed after the application has been completed. ■ Fig. 7.33d shows the completed application for drainage of the abdomen.

Memo

Application: Lymphatic technique

Cutting technique: Fan tape



■ Fig. 7.34. Blue fan tape

! Tip

In lymphedema of the leg, this tape application may also be used in combination with a compression stocking.

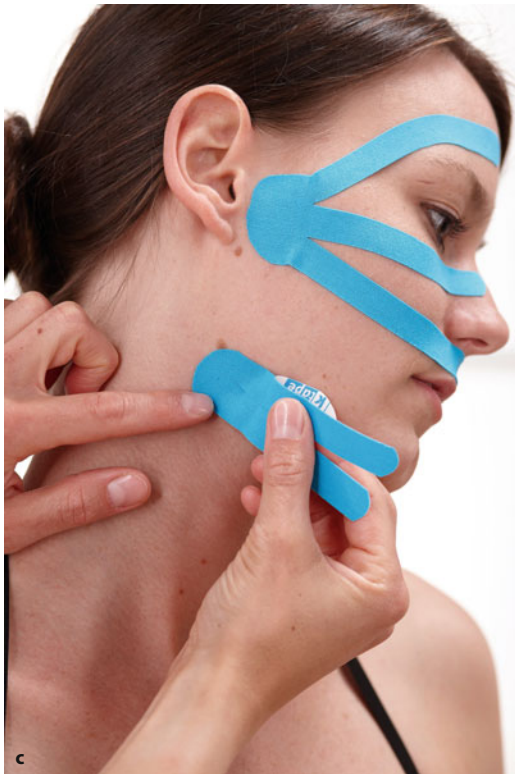

Fig. 7.35 a-d. Drainage of the face: **a-b Application Part 1.**
a Remove one tape tail from the first tape strip and affix the base to the preauricular lymph nodes, **b** distribute individual tail tapes along the forehead, cheek bone and upper jaw, **c-d Application Part 2.**

c Halve the second tape strip and affix the base to the subauricular lymph nodes. Distribute the individual tape tails along the lower jaw and floor of the mouth, **d** completed application

7.4 Additional lymphatic applications

- 7.4.1 Drainage of the face
- 7.4.2 Drainage of the shoulder joint
- 7.4.3 Drainage of the knee joint
- 7.4.4 Fibrosis/hematoma

7.4.1 Drainage of the face

Type

This example illustrates drainage of the face with a defective lymph node chain with partially or completely removed subauricular lymph nodes.

Base

The first base of the fan tape lies on the **preauricular lymph nodes** and the second base lies on the **subauricular lymph nodes**.

Application

The first tape is measured from the preauricular lymph nodes to the nasal bone. The second tape is measured from the subauricular lymph nodes to the center of the chin. Both tape strips are quartered.

- **Part 1:** One tape tail is removed from the first tape strip and the base affixed to the preauricular lymph nodes (■ Fig. 7.35a). The individual tape tails are distributed along the forehead, cheekbone and upper jaw. (■ Fig. 7.35b).
- **Part 2:** The second tape strip is halved and the base affixed to the subauricular lymph nodes. The individual

tape tails are distributed along the lower jaw and the floor of the mouth (■ Fig. 7.35c). When applying the tape, the base is anchored with strong skin displacement in the direction of the ear. The individual tapes are affixed without tension. The tape is applied on both sides to ensure a feeling of symmetry in the patient. The tape strips are rubbed after the application has been completed. ■ Fig. 7.35d shows the completed application for drainage of the face.

Memo

Application: Lymphatic technique

Cutting technique: Fan tape



■ Fig. 7.36. Blue fan tape

! Tip

In order to guarantee a uniform application to both sides of the face, it is important to ensure that there is absolutely no tension in the tape when carrying out the application.

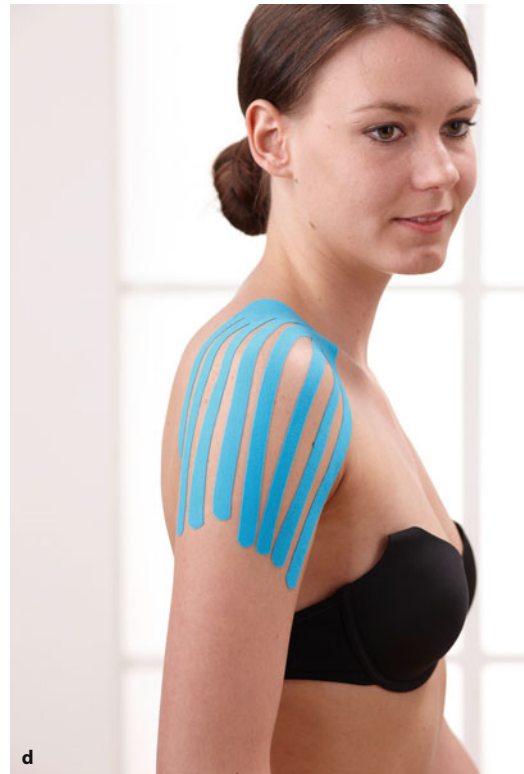
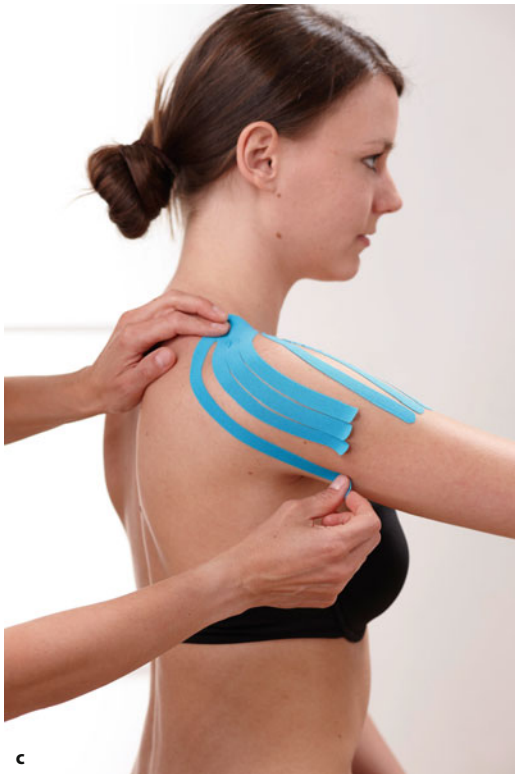
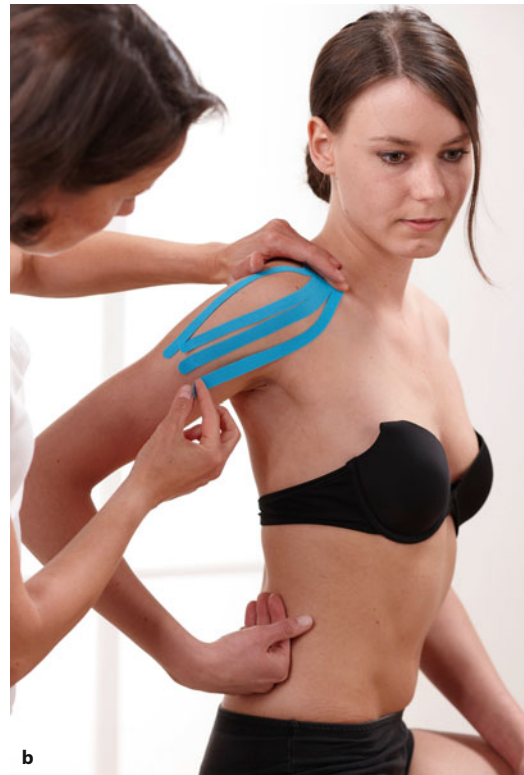Fig. 7.37 a-d. Drainage of the shoulder joint: **a** The first fan tape covers the anterior part of the deltoid muscle, **b** in affixing the individual tape strips, place the arm in various stretch positions. Detach individual tape tails one after the other and with anchored base and skin

displacement, affix over the entire upper arm with 25% tension, **c** the second fan tape covers the posterior part of the deltoid muscle, **d** completed application

7.4.2 Drainage of the shoulder joint

Type

This example illustrates an application for **drainage of the shoulder joint** with an intact lymph node chain. This application serves to relieve and attenuate pain in the shoulder joint.

Base

The bases of both fan tapes lie in the **supraclavicular fossa** (terminus).

Application

Both fan tapes are measured from the supraclavicular fossa to the deltoid tuberosity. The first fan tape covers the anterior part of the deltoid muscle and the second fan tape covers the posterior part (■ Fig. 7.37a-c). Completely remove the backing paper and lightly affix only the ends. In affixing the tape, the arm is placed in various positions according to the part of the muscle to be taped. The individual tape tails are detached one after the other and with anchored base and skin displacement uniformly affixed

over the entire upper arm with 25% tension. The tape ends are affixed without tension. The tape strips are rubbed after the application has been completed. ■ Fig. 7.37d shows the completed application for drainage of the shoulder joint.

Memo

Application: Lymphatic technique

Cutting technique: Fan tape



■ Fig. 7.38. Blue fan tape

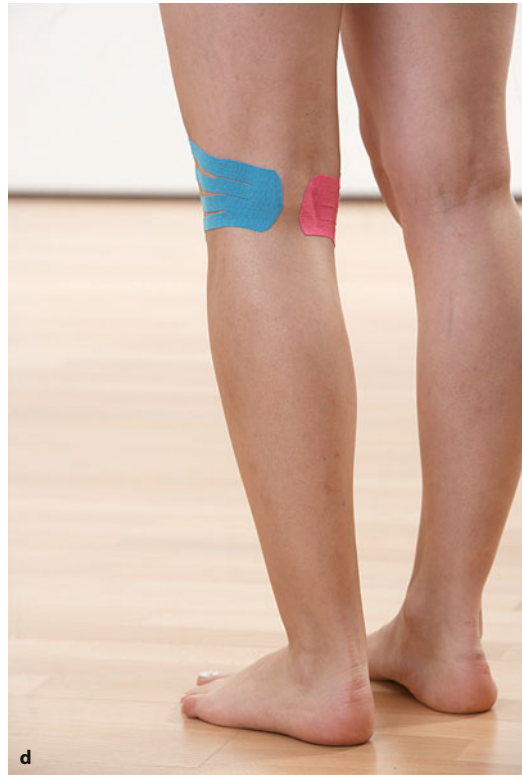
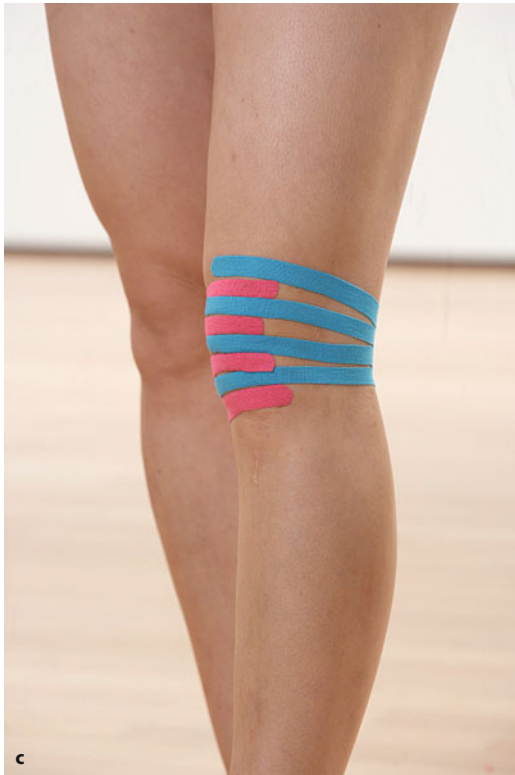
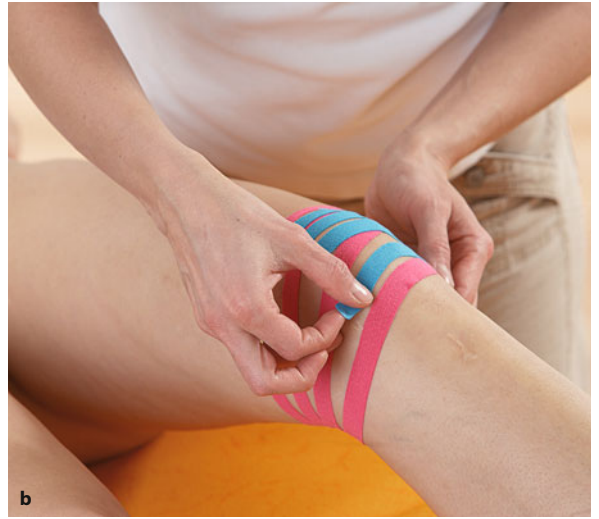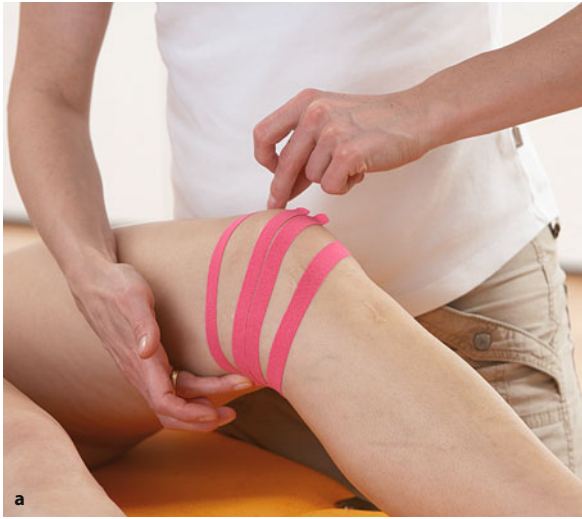Fig. 7.39 a-d. Drainage of knee joint **a** Bases lie in the popliteal fossa. First fan tape runs medially fanned out to the patella, **b** second fan tape runs laterally fanned out to the patella. The two fans dovetail into each other. For affixing the individual tape tails, the knee is

slightly flexed. Detach the individual tape tails one after the other and with anchored base and skin displacement, affix with 25% tension, **c** completed application ventral view, **d** completed application dorsal view

7.4.3 Drainage of the knee joint

Type

This example illustrates **drainage of the knee joint** with an intact lymph node chain. This application serves to relieve and attenuate the pain in the knee.

Base

The bases of two fan tapes lie in the popliteal fossa.

Application

The two fan tapes are measured from the popliteal fossa to the center of the patella. The bases lie in the popliteal fossa (■ Fig. 7.39a). The first fan tape is fanned out in a medial direction to the patella and the second fan tape is correspondingly fanned out in a lateral direction to the patella. The tail tapes from each side dovetail with each other. For affixing the individual tail tapes, the knee is slightly flexed. The individual tail tapes are detached one after the other and with anchored base and skin displacement affixed with 25% tension (■ Fig. 7.39b). The tape ends are affixed without tension. The tape strips are rubbed after the application has been completed. ■ Fig. 7.39c-d shows the completed application from ventral and dorsal aspects.

Memo

Application: Lymphatic technique

Cutting technique: Fan tape



■ Fig. 7.40.
Red fan tape



■ Fig. 7.41.
Blue fan tape

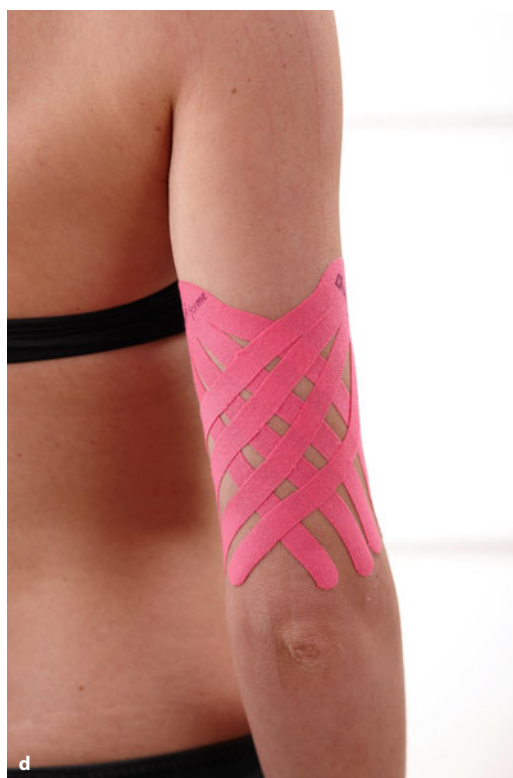
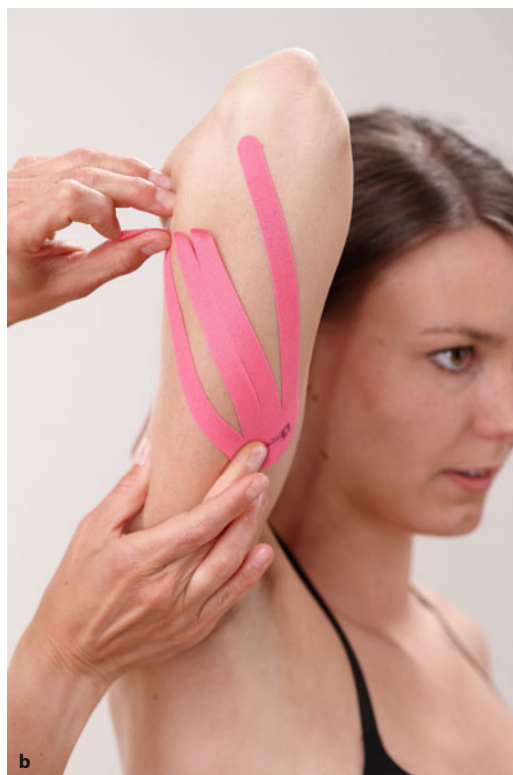
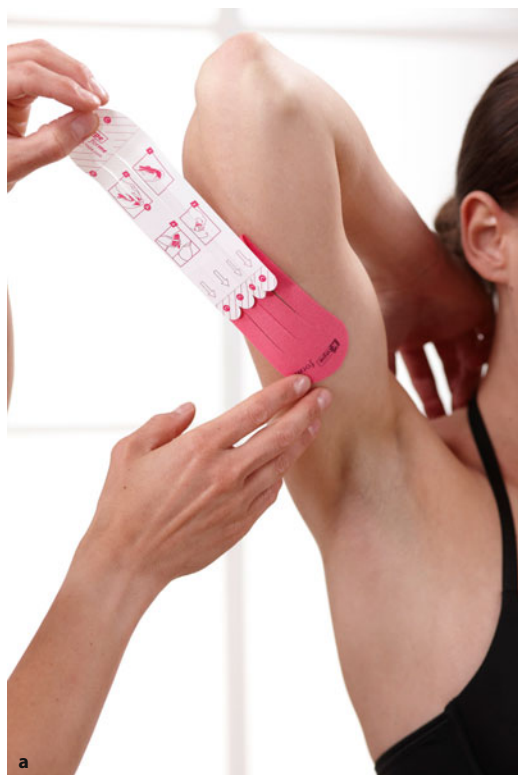Fig. 7.42 a-d. Fibrosis/Hematoma: **a** Bases lie at 90° to each other proximal to the fibrosis, **b** completely remove backing paper and lightly affix only the ends. When affixing the individual tape strips, the arm is in the Pre-stretching position. Detach individual tail tapes one

after the other and with anchored base and skin displacement, affix uniformly with maximum tension over the entire fibrotic area, **c** second tape application, **d** completed application

7.4.4 Fibrosis/hematoma

Type

In this example, there is **fibrosis** in the upper arm.

Base

The bases of two fan tapes lie proximally on the upper arm.

Application

The fan tape is measured across the entire area of the fibrosis plus two additional fingerbreadths. The bases lie proximal to the fibrosis and they are positioned at 90° to each other (■ Fig. 7.42a). The backing tape is completely removed and only the ends lightly affixed. For affixing the individual tape strips, the arm is in the Pre-stretching position. The individual tape tails are detached one after the other and with anchored base and skin displacement, are uniformly affixed with maximum tension over the entire fibrotic area (■ Fig. 7.42b). The tape ends are affixed without tension. The tape strips are rubbed after the application has been completed. ■ Fig. 7.42d shows the completed tape application for treating fibrosis/hematoma.

Memo

Application: Ligament technique

Cutting technique: Fan tape



■ Fig. 7.43. Red fan tape

! Tip

This application can be used for both **fibrosis** and **hematoma**.

References

- Appell H-J, Voss-Stang Ch (2008) Funktionelle Anatomie, Grundlagen sportlicher Leistung und Bewegung. 4. vollst. überarb. Aufl. Springer Berlin Heidelberg
- Bringezu G, Schreiner O (2006) Lehrbuch der Entstauungstherapie (Bd. 1). Springer Berlin Heidelberg
- Frisch H (2009) Programmierte Untersuchung des Bewegungsapparats. 9. überarb. u. erw. Aufl. Springer Berlin Heidelberg
- Tillmann B (2005) Atlas der Anatomie des Menschen. Springer Berlin Heidelberg

Subject Index

A

achilles tendon 83
 achillodynia 153
 acrylic adhesive 10
 acrylic coating 5
 adductor longus 63
 anatomical watershed 28
 ankle joint distortion 155
 anterior shoulder instability 105
 anterior talofibular ligament 85
 application for the lumbar region 61
 arm musculature 113
 asthma 121
 atrophy 7
 autochthonous back muscle 123, 125
 Autonomic nociception 8

B

biceps brachii 41
 biceps femoris 67
 biceps tendonitis 137

C

calcaneal tendon 83
 calcaneofibular ligament 85
 carpal tunnel syndrome 141
 channeling function of the tape 31
 cisterna chyli 193
 collateral ligaments of the knee 79
 color blue 11
 color red 11
 competitive sport 6
 Contraindications 11
 corrective fascia application 105
 corrective functional 9
 craniomandibular dysfunction 117
 CTM-genital zone 127, 129, 131
 CTM zone 23
 cutaneous receptors 2

D

deep sensibility (proprioception) 16
 defective lymph node chain 28, 193, 195
 deltoid 39
 dorsal horn 8
 drainage of abdomen 193
 drainage of entire arm 165
 drainage of forearm 165
 drainage of hand 169
 drainage of lateral upper arm 163
 drainage of lower trunk quadrant I 189
 drainage of lower trunk quadrant II 191
 drainage of medial upper arm 161
 drainage of the entire leg 179
 drainage of the face 195
 drainage of the foot 181
 drainage of the knee joint 199
 drainage of the lower leg 177
 drainage of the shoulder joint 197
 drainage of the thigh 175
 drainage of upper arm – medial and lateral 167
 drainage of upper trunk quadrant 187
 drainage using the arm spiral tape 173
 drainage using the leg spiral tape 185

E

eight loop 155
 elongated 16
 en bloc 17
 epicondylitis 139
 extensor carpi radialis longus muscle 47
 extensor hallucis longus 75
 external oblique 55

F

4 colors 3
 fallen arch 157
 fascia adhesion 27

fascia correction 25, 27, 99, 101, 103, 105, 107
 fascial applications 9
 fibrosclerotic change 31
 fibrosis 201
 fibular (lateral) collateral ligament 79
 finger contusion 145
 flatfoot 157
 freedom of movement 2
 frontal headache 103
 functional correction 25, 93, 105, 107
 functional corrective application 95
 functional disorders 2

G

gluteus maximus 71
 Golgi tendon organ 21

H

hallux valgus 107
 hematoma 201
 high volume insufficiency 28
 hip problem 147
 humeroulnar epicondylitis 139
 hypotonus 7
 hypotrophy 7

I

iliacus 59
 iliotibial tract 99
 impingement syndrome 135
 infrapinatus 45
 intact lymph node 163, 165
 intact lymph node chain 28, 161, 175, 177, 197, 199
 internal oblique 57
 international training system 6
 intrinsic back musculature 61

J

Joint 9

K

K-Tape Scissors 9
K-Taping Academy 2
K-Taping courses 6
K-Taping Forum 6

L

lateral collateral ligaments of the ankle
joint 85
lateralization of the patella 93
low volume insufficiency 29
lumbar vertebral syndrome (LVS) 125
lymphatic application 28
lymph node chain is defective 179,
181, 183, 185, 187, 189, 191

M

mechanoreceptors 2, 7, 17
menstrual disorder 129
micturition disorder 127
migraine 113
motor nocireaction 8
Muscle application 14
muscle application for the lower
extremities 63
muscle applications 2, 14
muscle applications for the trunk 49
muscle applications for the upper
extremities 37
muscle injuries 7
muscle shortening 7

N

neck musculature 111, 113
Nociceptors 7

O

osteoarthritis of the knee joint 151

P

pain attenuation 2
pain point 16, 23, 27, 87, 101, 125, 139
pain receptors 2
pain reduction 23, 25
patella correction 93
patellar ligament 81
pectoralis major 51
pectoralis minor 49
peripheral feedback regulation 7
peritoneum 131
physiological bottleneck 177
plantar ligament 157
position 16
posterior talofibular ligament 85
primary lymphedema 29
primary osteoarthritis 151
proprioception 2, 7
protein fibrosis 171
punctum fixum 14
punctum mobile 14

Q

quality control 4, 5
quality deficiencies 4
quality of the materials 3

R

radiohumeral epicondylitis 139
receptor excitation 25
receptor stimulation 17
rectus abdominis 53
rectus femoris 65
redistribution of force 9
retropatellar pressure reduction 151
rhythmic movement 27

S

safety valve insufficiency 31
scar formation 133
scar tape 133
scoliosis 95, 123
secondary lymphedema 29
secondary osteoarthritis 151
self-healing process 11
semimembranosus 69
sensitive skin 10
separate anchor 10
shoulder musculature 113
skin displacement 14, 21
skin irritations 4, 10
spacetape 87
spinal segment 16, 23
spinous process correction 97
splayfoot 157
stabilization 155
stabilization of the knee 151
stemmer sign 171
stemmer sign in the foot 183
stretched position 21
suction effect 23
superficial pes anserinus 101
supraclavicular fossa 163
supraclavicular fossa (terminus) 167,
197

T

temporomandibular joint 117
the head of the humerus 135
thoracic outlet syndrome (TOS) 119
tibial (medial) collateral ligament 79
tibialis anterior 73
tinnitus 111
tissue damage 7
tonus-decreasing applications 14
tonus-decreasing muscle application
14
torn muscle fiber 149
transverse arch 157
trapezius 37
triceps brachii 43
trigger point 16, 23, 87, 89

U

upper ankle joint 155
upper trunk quadrant 179
uterine prolapse 131

W

watershed 175
whiplash 115
wrist stabilization 143